

Parathyroid Adenoma: Our Experience

Nitin Gupta¹, Surinder K Singhal², Vaibhav Saini³, Shashikant Pol⁴

Received on: 21 December 2021; Accepted on: 26 April 2023; Published on: 09 January 2024

ABSTRACT

Introduction: Thyroid surgeries are routinely performed in day-to-day practice. However, parathyroid surgery is a rarely performed surgery that calls upon the highest level of skill and knowledge on the part of the surgeon to perform a complication-free surgery. Parathyroid adenomas are the most common tumors of parathyroid glands leading to hyperparathyroidism. Most of these patients are primarily seen by orthopedic surgeons or physicians and are then referred to the ENT Department for surgery.

Aim and objective: To present the clinic-radiological – pathological profile of parathyroid adenoma patients.

Materials and methods: Study design: Prospective observation study.

Setting: Tertiary Care Centre and Government Medical College.

Subjects: Clinico-radiological-pathological profile of 47 consecutive patients who underwent parathyroidectomy for adenomas during a 5-year period from 2016 to 2020 in our institute which is a Tertiary Care Hospital and Medical College excluding patients operated for parathyroid carcinoma.

Results: Findings were suggestive of adenomas in left inferior parathyroid (18), right inferior parathyroid (11), left superior parathyroid (9), right superior parathyroid (7) and in one patient there were 2 parathyroid adenomas.

Conclusion: We conclude that accurate diagnosis and thorough knowledge of anatomy is the key to carry out a successful parathyroid surgery.

Keywords: Parathyroid, Adenoma, Primary hyperparathyroidism, Sestamibi scan.

Otorhinolaryngology Clinics: An International Journal (2023): 10.5005/jp-journals-10003-1472

INTRODUCTION

Parathyroid glands are important endocrine glands that play a major role in the regulation of calcium metabolism. Disorders of parathyroid glands are rare disorders that can alter calcium levels in the human body causing major morbid manifestations for the patients. Parathyroid adenomas are the most common parathyroid tumors leading to hypercalcemia, which in turn can cause major morbidity to the patients.¹ These patients can present with myriad manifestations in the form of muscle weakness, nausea, vomiting, pathological fractures, and neuropsychiatric disturbances.^{2,3} The diagnosis of this entity is not straightforward and requires a strong suspicion on the part of the primary clinician. Diagnosis is reached by a combination of biochemical and radiological investigations. Nuclear medium scanning with Sestamibi is the diagnostic imaging of choice, as the dye is actively concentrated in the parathyroid glands.⁴ The mainstay of treatment is surgical excision, which can be challenging due to difficulty in identifying the offending gland and also the close proximity of the gland to the recurrent laryngeal nerve.

In this prospective study, we share our experience of clinic-radiological and surgical profiles of the patients who underwent surgery for parathyroid adenomas in our institute.

MATERIALS AND METHODS

This is a prospective analysis and observational study of patients who underwent surgery for parathyroid adenoma in our institute which is a tertiary care government hospital and a referral medical college. This analysis was done after studying the data of all 47

^{1,2}Department of ENT, Government Medical College Hospital, Chandigarh, India

³Department of ENT, All India Institute of Medical Sciences, Bathinda, Punjab, India

⁴Department ENT and Head Neck Surgery, Dr. Vasant Rao Pawar Medical College & Research Centre, Nashik, Maharashtra, India

Corresponding Author: Nitin Gupta, Department of ENT, Government Medical College Hospital, Chandigarh, India, Phone: +91 9646121704, e-mail: nitinent123@gmail.com

How to cite this article: Gupta N, Singhal SK, Saini V, *et al.* Parathyroid Adenoma: Our Experience. *Int J Otorhinolaryngol Clin* 2023;15(3): 161–164.

Source of support: Nil

Conflict of interest: None

consecutive patients who underwent surgery in our department in 5 years period from 2016 to 2020. The study was approved by the Institutional Research and Ethics Committee.

Statistical Analysis

Results were recorded and are expressed as the means \pm standard deviation. Statistical significance was determined using the Chi-square test. The coefficient of agreement was collected to compare various investigations. All analyses were performed using the Statistical Package for Social Science (SPSS) version 16.0 (SPSS Inc., Chicago, IL, USA). $p < 0.05$ was considered to indicate a statistically significant difference.

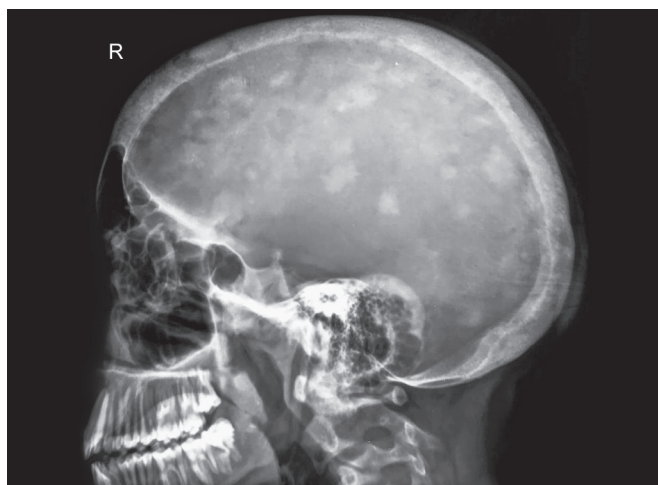

Fig. 1: X-ray skull showing typical salt and pepper appearance

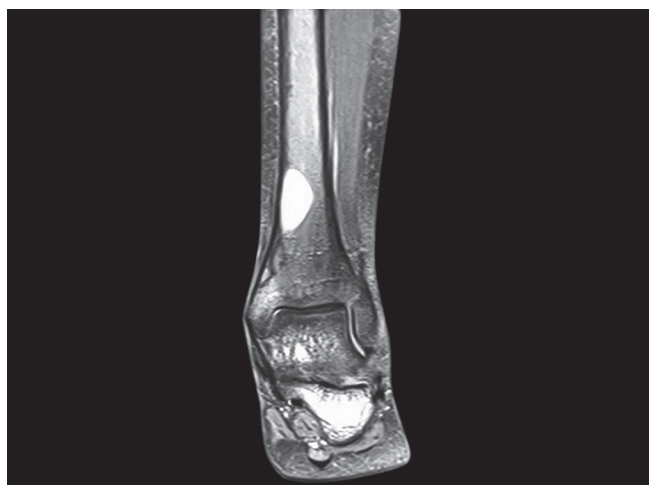

Fig. 3: MRI foot showing lytic lesion in femur

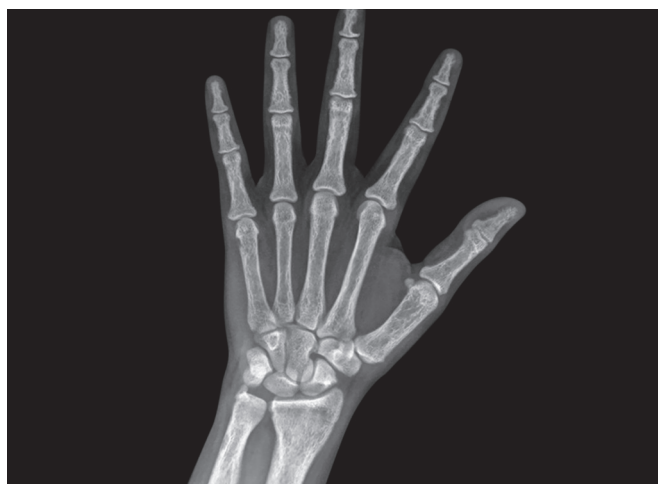

Fig. 2: X-ray of hand showing bone erosion and resorption of phalanges

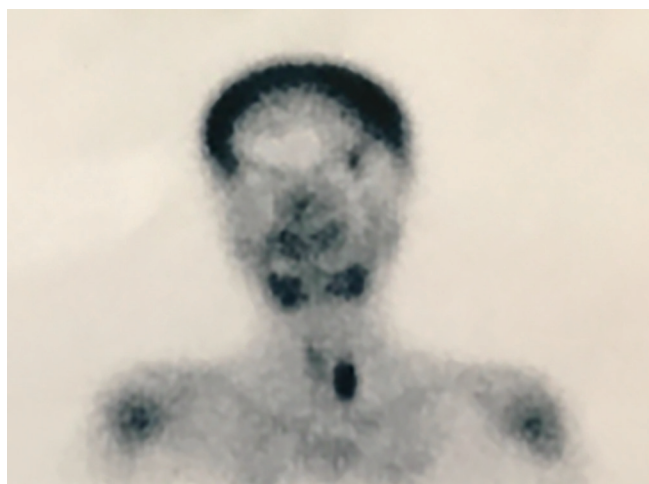


Fig. 4: Sestamibi scan showing a left inferior parathyroid adenoma

Inclusion Criteria

All patients of either sex operated for parathyroid adenoma during the period.

Exclusion Criteria

- Patients not consenting for surgery
- Patients requiring revision surgery
- Patients diagnosed as parathyroid carcinoma

RESULTS

A total of 47 patients were operated in this period, with 19 being male and 28 female patients. The ages of these patients ranged from 29 to 63 years. Most of these patients (39) presented to the orthopedics department with bone pains or pathological fractures. One patient had the characteristic salt and pepper appearance in the skull (Fig. 1), bone erosion and resorption of phalanges (Fig. 2), demineralization, and lytic lesions in peripheral long bones (Fig. 3). Two patients were referred from the nephrology department with the presentation of renal stones and 3 patients presented to the surgical emergency with acute pancreatitis. All these

patients were diagnosed due to a strong clinical suspicion which was confirmed by biochemical tests. All the patients had raised serum calcium levels ranging from 10 to 15 mg/dL. Hypercalciuria was seen in 33 patients with values ranging from 300 to 560 mg/24 hours. Parathyroid hormone assay was done in all these patients. The majority of the patients had very high levels of parathyroid hormone level in their samples (100–2300 pg/mL). Seven patients had PTH levels of even more than 1500 pg/mL. Imaging studies were done on all these patients. Sestamibi scan which is considered as a gold standard was done in 46 patients (Fig. 4). In one patient who had multiple fractures and could not be transported, the scan was not done. Ultrasonography of the neck was done in 47 patients. Radiological findings were suggestive of adenomas in the left inferior parathyroid (18), right inferior parathyroid (11), left superior parathyroid (9), right superior parathyroid (7) and in one patient there were 2 parathyroid adenomas (Fig. 5). All the patients were operated by surgery through an open neck incision. Surgical exploration of the neck with prior informed consent with particular emphasis on calcium imbalance, recurrent laryngeal nerve (RLN) injury, wound hematoma, and possible re-exploration was taken. The surgery was done in the standard extended neck position

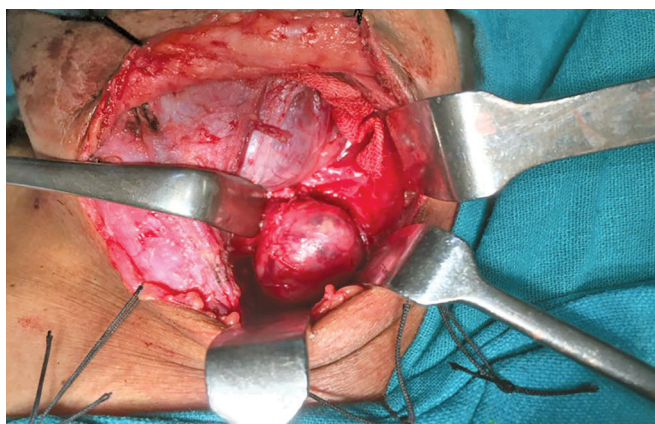


Fig. 5: Intraop picture of left inferior parathyroid adenoma

allowing complete exposure of the neck. A standard low-neck incision of about 3–4 cm about 2.5 cm above the suprasternal notch was made. After raising subplatysmal flaps, dissection was directed to the side of the offending gland. The ipsilateral strap muscles were retracted laterally and the thyroid lobe retracted medially. The middle thyroid vein was looked for and was ligated if present. Inferior thyroid artery (ITA) was identified as this is a key landmark for further dissection. Recurrent laryngeal nerve was identified next in Beahrs' triangle. Intersection of RLN and ITA is an important landmark and was used as a guide to the location of parathyroid glands. The tumor along with the offending parathyroid gland was identified and excised in toto.

A negative suction drain was kept and the wound was closed in layers. Serum calcium levels were measured every 12 hours in the postoperative period. Serum calcium levels returned to near-normal levels in 48–72 hours in the majority (38) of the patients. Parathyroid hormone levels were measured on the first postoperative day and they returned to normal levels in 44 patients. Three patients developed hypocalcemia and calcium supplements were given to them for about 7 days. Two patients developed hoarseness and vocal cord palsy was seen in these 2 patients on laryngoscopy. They were managed on speech therapy. Both these patients recovered completely after a period of 3 months. The drain was removed after 72 or 96 hours when the amount reached less than 10 mL. Sutures were removed on the 7th postoperative days and the patient was discharged. The patients were followed 2 weeks after the surgery and serum calcium, PTH levels, and vitamin D levels were measured. Serum calcium and vitamin D levels were found to be normal in all the patients while PTH levels were marginally raised in 5 patients. All the patients were kept on regular follow-up and were doing well.

DISCUSSION

Parathyroid adenomas are rarely diagnosed tumors of the neck which pose a significant diagnostic and therapeutic challenge for clinicians. Most of the patients are diagnosed late as the patients do not have specific presentations related to parathyroid but have bone fractures, renal stones or psychiatric manifestations.⁵ Majority of patients have a single parathyroid adenoma as reported by Ruda et al. who reviewed patients of primary hyperparathyroidism from 1995 to 2003 and concluded that single parathyroid adenoma accounts for 90% of benign tumors of the parathyroid.⁶ This was in correspondence to our study in which we found 95% of our

patients had a single-gland disease.⁶ Many of the patients were referred to us from the orthopedics department with presentations of fractures. This is in agreement with Uden et al. who had also described this in their paper in 1992.³ Serum calcium and PTH levels were raised in the majority of our patients in conjunction with other studies. Preoperative localization of the offending gland is the key to a good surgical outcome avoiding the need for re-explorations. Ultrasonography of the neck, CT scan of the neck, and Sestamibi scan (gold standard) are the key radiological investigations in order to find out the exact location of the gland.^{7,8} High-resolution ultrasound is an effective examination to locate enlarged parathyroid glands in the neck.⁹ The sensitivity of ultrasonography for the localization of abnormal parathyroid glands generally varies in the literature from 61 to 85%.^{8,9} In our patients we found a sensitivity of 76% as regards the ultrasonography of the neck. Sestamibi scan also has a high sensitivity for the detection of abnormal parathyroid glands and is particularly useful in detecting small, posterior adenomas. In our patients, we found a sensitivity of 96% for the Sestamibi scan which is comparable with the majority of studies in literature.⁷ Accurate location of the involved gland holds the key to a successful surgical outcome.^{10–12}

CONCLUSION

Symptoms of Primary hyperparathyroidism vary and lack specificity. Parathyroid adenomas are the most common cause of primary hyperparathyroidism. Treating clinicians should have an high index of suspicion for diagnosing this rare entity. Accurate localization of the offending gland is the key to a correct diagnosis and a good surgical outcome. Sestamibi scan is the gold standard investigation for parathyroid gland with high sensitivity and specificity. Exact anatomical location and good surgical techniques provide the recipe for a complication less and uneventful postoperative period.

ORCID

Nitin Gupta  <https://orcid.org/0000-0003-0706-7171>

Surinder K Singhal  <https://orcid.org/0000-0002-9940-4210>

Shashikant Pol  <https://orcid.org/0000-0001-9774-6439>

REFERENCES

1. Bilezikian JP, Silverberg SJ. Clinical practice. Asymptomatic primary hyperparathyroidism. *N Engl J Med* 2004;350:1746–1751. DOI: 10.1056/NEJMc032200.
2. Fraser WD. Hyperparathyroidism. *Lancet* 2009;374:145–158. DOI: 10.1016/S0140-6736(09)60507-9.
3. Udén P, Chan A, Duh QY, et al. Primary hyperparathyroidism in younger and older patients: Symptoms and outcome of surgery. *World J Surg* 1992;16(4):791–797. DOI: 10.1007/BF02067389.
4. Suliburk JW, Perrier ND. Primary hyperparathyroidism. *Oncologist* 2007;12(6):644–653. DOI: <https://doi.org/10.1634/theoncologist.12-6-644>.
5. Felger EA, Kandil E. Primary hyperparathyroidism. *Otolaryngol Clin North Am* 2010;43(2):417–432. DOI: 10.1016/j.otc.2010.01.009.
6. Ruda JM, Hollenbeak CS, Stack BC. A systematic review of the diagnosis and treatment of primary hyperparathyroidism from 1995 to 2003. *Otolaryngol Head Neck Surg* 2005;132(3):359–372. DOI: 10.1016/j.otohns.2004.10.005.
7. Johnson NA, Tublin ME, Ogilvie JB. Parathyroid imaging: Technique and role in the preoperative evaluation of primary hyperparathyroidism. *AJR Am J Roentgenol* 2007;188(6):1706–1715. DOI: 10.2214/AJR.06.0938.

8. Meilstrup JW. Ultrasound examination of the parathyroid glands. *Otolaryngol Clin North Am* 2004;37(4):763–778. DOI: 10.1016/j.otc.2004.02.008.
9. Ghaheri BA, Koslin DB, Wood AH, et al. Preoperative ultrasound is worthwhile for reoperative parathyroid surgery. *Laryngoscope* 2004;114(12):2168–2171. DOI: 10.1097/01.mlg.0000149451.45264.90.
10. Meyer A, Brabant G, Behrend M. Surgical treatment of primary hyperparathyroidism. *Eur J Med Res* 2005;29(10):287–291. PMID: 16055399.
11. Augustine MM, Bravo PE, Zeiger MA. Surgical treatment of primary hyperparathyroidism. *Endocr Pract* 2011;17(Suppl 1):S75–S82. DOI: <https://doi.org/10.4158/EP10359.RA>.
12. Hessman O, Stålberg P, Sundin A, et al. High success rate of parathyroid reoperation may be achieved with improved localization diagnosis. *World J Surg* 2008;32(5):774–781. DOI: 10.1007/s00268-008-9537-5.