

# A Comparative Study of Endoscopic Septoplasty and Conventional Septoplasty Outcomes

Manik Rao Kulkarni<sup>1</sup>, Sushmitha V Badiger<sup>2</sup>, Nasreenbanu Khadarnayakar<sup>3</sup>

## ABSTRACT

**Background:** Sinonasal illness frequently results in a significant reduction in quality of life, more so in chronic situations. The most frequent issue is a deviated nasal septum (DNS). This study compared the postoperative results for patients who underwent traditional septoplasty and endoscopic septoplasty.

**Methods:** A prospective study conducted on patients, attending the Department of ENT on an in-patient basis who are diagnosed to have DNS, and other associated pathologies like chronic rhinosinusitis, polyps, and nasal cavity mass were selected on a simple random basis for this study from March 2020 to August 2021. The patients were subjected for either conventional/endoscopic septoplasty, postoperatively patients followed up, and assessed for symptom relief [Nasal Obstruction Symptom Evaluation (NOSE) score] and other complications.

**Results:** One of the most common causes of nasal obstruction is a DNS. In our study, second-decade age was more commonly affected, men are more common (60%). Type III and type V are the most common endoscopic type of septal deviations according to the Jain Bhalerao (JB) endoscopic classification. The NOSE questionnaire was given to all patients preoperatively and postoperatively at 1 and 3 months to both the study group, and *p*-value was calculated, which was <0.001 when compared between conventional septoplasty and endoscopic septoplasty, which indicates it as highly significant.

**Conclusion:** Endoscopic septoplasty is better than conventional septoplasty with regards to better visualization, good access to the posterior part of the septum, better illumination, limited resection and postoperative improvement, and complications are less in comparison with conventional septoplasty.

**Keywords:** Conventional septoplasty, Endoscopic septoplasty, NOSE score, Postoperative complications.

*Otorhinolaryngology Clinics: An International Journal* (2024): 10.5005/jp-journals-10003-1436

## INTRODUCTION

Nasal blockage is one of the most frequent problems that otorhinolaryngologists see in their daily practice. DNS is the most frequent etiological cause. Surgical correction is only needed if the patient is symptomatic.<sup>1,2</sup> Epistaxis, sinusitis, headache, and obstructive sleep apnea are the other presenting complaints.<sup>3</sup>

Surgical management progressed from submucosal resection radical removal of cartilage to septoplasty. With the usage of endoscope, presently, endoscopic septoplasty is commonly performed by the ENT surgeons.<sup>4</sup>

The endoscope has advanced from using it to septal and lateral nasal wall pathologies and presently has been used to anterior skull base approaches for pituitary surgeries, cavernous sinus surgeries, and other different petrous apex lesions.

The main aim of the surgery includes the following:

- Should improve patient's symptomatology
- Should be conservative
- No compromise on normal anatomy
- Must be able to perform a revision operation, if needed

With regard to the above-mentioned points, all procedures have its limitations and complications.<sup>5</sup>

Cottle first described septoplasty in 1947. Historical surgeries improve patient airway but do not fulfill above criteria. Poor illumination, poor visualization, relative accessibility, unneeded manipulation, resection, and overexposure of the septal framework were the main problems, making it challenging to perform revision surgery.<sup>5</sup> Since the advent of diagnostic nasal endoscopy, we have been able to identify the pathology of the lateral wall

<sup>1-3</sup>Department of Otorhinolaryngology, Vijayanagar Institute of Medical Sciences, Ballari, Karnataka, India

**Corresponding Author:** Sushmitha V Badiger, Department of Otorhinolaryngology, Vijayanagar Institute of Medical Sciences, Ballari, Karnataka, India, Phone: +91 9632577905, e-mail: sush.badiger@gmail.com

**How to cite this article:** Kulkarni MR, Badiger SV, Khadarnayakar N. A Comparative Study of Endoscopic Septoplasty and Conventional Septoplasty Outcomes. *Int J Otorhinolaryngol Clin* 2024;16(1):70-74.

**Source of support:** Nil

**Conflict of interest:** None

and the septum in advance of surgery, which has assisted in the planning of endoscopic septoplasty.<sup>6</sup> The use of a direct approach septoplasty, which requires little dissection and good postoperative healing, is reserved for isolated septal spurs without severe septal abnormalities.<sup>5</sup>

Lanza was the first to describe endoscopic correction of septal deviations. Later many studies showed more and more advancement in the surgeries like access to lateral wall of nose pathologies as a teaching guide.

In the beginning of the introduction of endoscopic septoplasty, it was easier for the surgeons for dissection and for resection of spurs. It was very useful in teaching hospital as a tool for teaching.<sup>7</sup>

Nasal endoscopy is an excellent technique for determining the relationship between the middle turbinate and the septum, allowing the surgeon to determine whether or not the septum's location would restrict access during endoscopic procedures.

Septoplasty may be required to maximize access to the middle meatus during endoscopic sinus surgery, even in the absence of subjective nasal blockage or severe septal deviation, such as in the case of a narrow nasal cavity with a substantial septal body. Nasal endoscopy is a fantastic method for post-septoplasty surveillance outside of the hospital, both during and beyond the initial postoperative healing phase.

Endoscopic septoplasty is utilized to reach the surgical site, like with functional endoscopic sinus surgery (FESS), rather than to remove nasal obstruction. However, it offers clear benefits in all instances of septal deviations, revision procedures, and situations of prior septal perforation, cases of isolated septal spurs, and cases involving previous perforation.

Like complex anomalies, caudal deflections need to be treated according to the standard practice.

In order to compare the subjective postoperative results of symptomatic alleviation as measured by the NOSE score with the objective complications such as septal abscess, synechiae, deformity, septal perforation, etc., the current study was carried out. The objective of this study is to determine if endoscopic septoplasty is a superior surgical option for treating septal deviations, spurs, and sinonasal pathology among patients who have undergone conventional and endoscopic septoplasty.

## MATERIALS AND METHODS

This is a prospective study, conducted from March 2020 to August 2021 in the Department of ENT, Vijayanagar Institute of Medical Sciences, Ballari, Karnataka, India. Ethical committee clearance was obtained before the study was conducted. The study included 60 patients of both sexes attending to the Department of ENT on out- and/or in-patient basis aged above 10 years of either sex with symptomatic DNS-like nasal obstruction, headache or rhinorrhea. These patients were selected on the simple random basis.

Patients having symptoms and evidence of a DNS were chosen for this prospective randomized trial conducted at a tertiary referral center.

The goal was to precisely detect nasal septal abnormality in respect to the lateral nasal wall, to treat the pathology, and to

compare the efficacy of endoscopic septoplasty to that of standard septoplasty.

Inclusion criteria: All patients were above the age of 10 years.

Exclusion criteria:

- Patients age below 10 years
- Patients with allergic rhinitis
- Patients with vasomotor rhinitis
- Patients with acute infections

The endoscopic anatomic classification of the DNS (JB classification) of the DNS is provided in [Table 1](#).<sup>1</sup> All patients underwent diagnostic nasal endoscopy. Additionally, routine preoperative hematological and radiological tests were performed, and septoplasty was performed. Thirty patients received endoscopic septoplasty and thirty underwent traditional septoplasty after providing written informed consent in their native tongue.

Patients followed up and subjected for subjective assessment of the NOSE questionnaire<sup>2</sup> for symptomatic relief nasal obstruction symptom relief score and objective assessment of complications like synechiae formation, septal perforation, septal abscess, and nasal deformity were compared with both the groups.

The following parameters were collected and analyzed from the data of the two groups:

- Subjective improvement on the NOSE scale, 1 month and 3 months after surgery.
- Using diagnostic nasal endoscopy, objectively analysis of complications such as synechiae formation, septal abscess, septal perforation, and deformity.

## Statistical Analysis

Qualitative data represented in the form of frequency and percentage. To assess the association between variables, Chi square test and Fisher's exact test were used. Continuous variables were represented as mean and Standard deviation. Mean comparison between groups was done with unpaired *t*-test. *P*-value of <0.05 was considered statistically significant.

International business machines statistical package for social sciences (IBM SPSS) version 28 for windows was used to do the statistical analysis.

**Table 1:** Endoscopic anatomic classification of dns (JB classification)<sup>1</sup>

Type of DNS	Description
Type I	Cartilaginous deviation only on one side (C-shaped)
Type II	Cartilaginous deviation with caudal dislocation(ipsilateral/contralateral)
Type III	Ipsilateral high posterior deviation (perpendicular plate of ethmoid) with cartilaginous deviation of septum, with vomerine deviation and/or ipsilateral/contralateral caudal dislocation
Type IV	Contralateral high posterior deviation (perpendicular plate of ethmoid) with cartilaginous Deviation of septum, with vomerine deviation and/or ipsilateral/contralateral caudal dislocation
Type V	Ipsilateral high posterior bony deviation (perpendicular plate of ethmoid) with maxillary crest displacement and/or vomerine deviation, with/without spur, and with/without caudal dislocation
Type VI	Contralateral high posterior bony deviation (perpendicular plate of ethmoid) with maxillary crest displacement and/or vomerine deviation with/without spur with/without caudal dislocation
Type VII	Maxillary crest displacement and/or vomerine deviation with/without spur with/without caudal dislocation
Type VIII	High posterior bony deviation only (unilateral or bilateral)
Type IX	Spur only (cartilaginous and/bony)
Type X	Any other (combination of previous types)

### Procedure of Conventional Septoplasty

Prior to surgery, a bilateral nasal decongestion was performed with 4 % lignocaine and adrenaline for 10 minutes. A freer's incision was performed 2–3 mm from the caudal end of the septum on the concave side along the entire height of the septum under general or local anesthesia under headlamp vision, after infiltration with 2% lignocaine with adrenaline (1:10,000) into the septum.

Raising the mucoperichondrial flap formed the anterior tunnel, raising the mucoperiosteal flap created the posterior tunnel, and raising the flap over the maxillary crest created the inferior tunnel. On the opposite side, the bony-cartilaginous junction was displaced, and the periosteal flap was elevated. To rectify the bone abnormality, a portion of the ethmoid's perpendicular plate and the vomerine spur were excised. Inferiorly, a small cartilaginous strip was removed. Any more cartilage was excised as needed for the specific instance, and the mucoperichondrial flap on the opposite side was also elevated. Incision was sutured with catgut, and nasal cavities were packed with Vaseline nasal pack. Nasal pack was removed second postoperatively.

### Procedure of Endoscopic Septoplasty

Prior to surgery, a bilateral nasal decongestion was performed with 4% lignocaine and adrenaline for 10 minutes. Under local or general anesthesia, the procedure was performed. The septum was injected with 2% xylocaine in 1:10,000 epinephrine on the convex side of the most deviated part of the septum using 0° rigid 4 mm endoscope. A Freer's incision was made. The incision was not prolonged from the dorsum to the floor, as in a traditional incision, but instead was extended superiorly and inferiorly as needed to expose the most deviated area.

A mucoperichondrial and mucoperiosteal flap was raised using a suction elevator under direct visualization with an endoscope, underlying cartilage, bones were exposed, and the most deviated part was removed. The flap was repositioned back after suction clearance and edges of the incision were just made to lie closely, and suturing was done with 3.0 catgut. The nasal cavity was packed with Vaseline Nasal pack. Nasal pack was removed second postoperatively. [Figure 1](#) showing intraoperative finding of posterior septal deviation in endoscopic septoplasty done at VIMS BALLARI.

### Postoperative Care

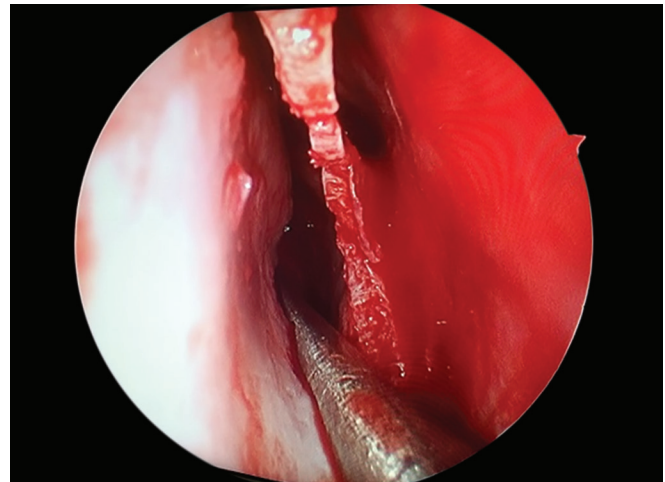
All patients were given both parenteral antibiotics, analgesics, and oral antihistamines. The pack was removed after 48 hours. They were discharged following 24 hours of pack removal.

All patients were followed up as outpatients 7, 15, 30, and 90 days after the surgery and were assessed for subjective improvement of symptoms by the NOSE score. The NOSE score, which included five parameters such as nasal stuffiness, nasal blockage or obstruction, trouble breathing through nose, trouble sleeping, and unable to get enough air through nose during exertion or exercise, has value ranging from 0 to 4, and the maximum score was 20. The NOSE score is shown in [Table 2](#).<sup>1</sup> The objective assessment by diagnostic nasal endoscopic examination was done on follow-up dates in discharge to look for synechiae, septal perforation, septal abscess, and deformity. In case of complications, some were treated conservatively and some were needed admission.

### RESULTS

The study include 60 patients, 30 patients underwent conventional septoplasty and 30 endoscopic septoplasty on the random basis. The mean age of study population was in the second decade. The study included 44 men and 16 women. About 46.7% of students were most commonly affected. The right-sided nasal obstruction was seen in 66.7% of the patients. Type III and Type V are the most common endoscopic type of septal deviations according to the JB classification.<sup>1</sup>

In our study, 21 patients had comorbidities, and out of study group patients 9 have hypertension and 12 have diabetes. all patients were on regular treatment. The NOSE questionnaire was given to all patients preoperatively and post operatively at 1 and



**Fig. 1:** Showing intraoperative finding of posterior septal deviation in endoscopic septoplasty

**Table 2:** The NOSE score<sup>1</sup>

Symptom	Not a problem (A)	Very mild problem (B)	Moderate problem (C)	Fairly bad problem (D)	Severe problem (E)
Nasal stuffiness	0	1	2	3	4
Nasal blockage or obstruction	0	1	2	3	4
Trouble breathing through my nose	0	1	2	3	4
Trouble sleeping	0	1	2	3	4
Unable to get enough air through my nose during exertion or exercise	0	1	2	3	4

**Table 3:** The comparison of the nose score among two groups

NOSE score	Intergroup comparison					
	Group C		Group E		Unpaired t-test	
	Mean	Std. Deviation	Mean	Std. Deviation	p-value	Significance
Preoperative	11.40	1.90	9.53	1.55	0.001	HS
1-month postoperative	6.87	2.45	2.87	1.14	0.001	HS
3-month postoperative	5.80	1.83	2.07	0.52	0.001	HS

HS, highly significant

**Table 4:** Postoperative complications of conventional and endoscopic septoplasty groups

	Group C	Group E	p-value
Synechia	18	2	0.001, HS
Septal perforation	7	0	0.001, HS
Septal abscess	1	0	0.313, NS
Deformity	0	0	

HS, highly significant; NS, not significant

3 months to both the study group, and *p* value was calculated. The comparison of the NOSE score among two groups is shown in Table 3.

The calculation shows that there is a significant correlation of the NOSE score in both groups, with *p*-value of 0.001 indicating highly significant. The endoscopic septoplasty group has a better score compared to the conventional septoplasty.

We considered only four complications postoperative synechia, septal perforation, septal abscess, and deformity. Diagnostic nasal endoscopy and objective evaluation of complications were done postoperatively to all the patients. There were many complications associated with septoplasty like intraoperative bleeding, tear of mucoperichondrial, mucoperiosteal flap, and later complications like septal hematoma, bleeding, retraction of columella, persistence of deviations, flapping of nasal septum, toxic shock syndrome, and rarely death.

In our study, most of the complications were seen in conventional septoplasty group; 18 patients had postoperative synechia formation, 7 patients had septal perforation, and only 1 patient had septal abscess. no patient had deformity postoperatively. Whereas in endoscopic septoplasty group only two patients had postoperative synechia formation and no patients had septal perforation, septal abscess, and deformity. the postoperative complications among two study groups is shown in Table 4.

In our study, only one patient had septal abscess and needed readmission incision drainage. patient was a known case of diabetes and hypertension with uncontrolled sugars, and patient had all risk factors for abscess formation. And after admission under local anesthesia, incision drainage was done. Postprocedure patient stayed in hospital for 5 days and completed his intravenous antibiotic treatment and discharged on the sixth day. During discharge, the wound was healthy, and sugar was under control. Patient was advised oral antibiotics on discharge. Patient followed-up regularly and no further complications were noted.

## DISCUSSION

Nasal septum deviation is quite common, but it is not necessarily symptomatic.

If the patient has difficulty breathing, recurrent episodes of epistaxis, or a headache, surgery is recommended.

There are many medical and surgical descriptions of the pathology and treatment of the DNS available. But none of these descriptions met all of the requirements listed above. It is necessary to keep up the airway improvement. Initially, a submucous resection of the septum was performed. This radical procedure involved the elevation of mucoperiosteal flaps on both sides and the removal of the entire cartilage and bony septum. It was also associated with additional complications like septal tears, perforations, hematomas, abscesses, and deformities. Later, septoplasty was created because of its advantages of minimizing septum resection, limiting elevation of the mucoperiosteal and mucoperichondrial flaps to the deviated portion, and resulting in fewer problems. Since the invention of endoscopes, endoscopic septoplasty has taken the place of all aforementioned procedures.<sup>8</sup>

Our study aimed at comparing the results of endoscopic septal surgery vs conventional septal surgery using these parameters: subjective improvement in symptoms preoperatively and postoperative 1 month and 3 month using the validated NOSE scores<sup>2</sup> and the presence of complications. The complications we included were only septal synechia, septal perforation, abscess, and septal deformity. Our study coincides with other studies.

Endoscopic septoplasty is utilized to reach the surgical site, as in the case of FESS, rather than to remove nasal obstruction. However, it has specific benefits in all circumstances, revision operations, cases of prior septal perforation, and situations of lone septal spurs. Complex deformities, as well as caudal deflections, require conventional treatment.

In the study by Nayak et al., the endoscope-aided septoplasty was found to be more effective in treating symptoms such as nasal obstruction and headache. In this, *p*-value was significant, i.e., <0.02 and <0.05, respectively. There is a significantly higher rate of persistence of symptoms that were found with conventional septoplasty as compared to endoscopic septoplasty in the present study.<sup>6</sup>

Harley et al. observed that nasal obstruction and headache were improved significantly with endoscopic group than conventional group.<sup>9</sup>

Garzaro et al. observed that the complications were less in endoscopic septoplasty when compared with conventional septoplasty. our study also has similar results, and the complication was synechia.<sup>10</sup>

The complication rate in endoscopic septoplasty group was 3%. While in the present study, the complication rates were found to be 2.08% and 1.6% by Gupta, and Nawaiseh and Al-Khtoum, respectively. Our study showed similar percentage of complications.<sup>11, 12</sup>

Traditional septoplasty techniques include headlight illumination, viewing using a nasal speculum, and surgical



equipment such as Killian's nasal speculum, which are commonly used during regular conventional operations. There were numerous challenges with this surgery, including low illumination, difficult to assess posterior abnormalities, and frequent headlight exchanges. In addition, poor vision can lead to nasal mucosal damage, which can make endoscopic visualization difficult during sinus surgery.

Overexposure, needless modification of the septal anatomy, and greater resection are common in traditional nasal septal surgery. Because of the inadequate lighting, accessibility, and magnification, greater exposure is required through a wide incision and elevation of flaps bilaterally on the septum.<sup>13</sup> Endoscopically, posterior deviations and spurs that were largely inaccessible by the traditional approach due to tunnel vision and limited manipulation space were better dealt with. With the invention of the endoscope, all traditional procedures have been replaced, and access to the many disorders of the nose has been much improved.<sup>14</sup>

Lastly, endoscopic septoplasty can also be considered as a newer proforma for different nasal pathologies and for effective teaching tool. For learning, instruction, graduate specialist, and medical college students, there is good access to anatomy, pathologies, and surgical techniques due to the depiction on the computer screen.<sup>15</sup>

We concluded that while both conventional and endoscopic procedures were efficient in alleviating symptoms of a DNS, endoscopic septoplasty was significantly superior to conventional surgery.

This is most likely due to the endoscopic procedures direct-focused approach to the septal anatomic anomaly, which allows for a minimally invasive operation with little septal mucosal flap dissection and removal of a mild cartilaginous and/or bony deformity.

## CONCLUSION

Overall, the study found that endoscopic septoplasty produced superior outcomes, fewer side effects, and better patient compatibility than the group that underwent conventional septoplasty. By using a small incision and elevating a small portion of the flap, endoscopic septoplasty can cure high DNS and posterior deviations while requiring the least amount of resection. By lessening the damage to the septum, this approach lowers the risk of problems following surgery. We advise that all surgeons become proficient in the endoscopic procedure in the light of the clear advantages it has over the conventional method of doing septoplasty.

Due to the limited extent of flap dissection, the lack of use of the Killian's nasal speculum, which by pressure can cause preoperative discomfort, limited manipulation, and resection of the septal framework, endoscopic septoplasty is associated with a significant reduction in the patient's morbidity in both the preoperative and postoperative period. However, the endoscope has some limitations of its own, such as the loss of binocular vision and the requirement for routine cleaning of the endoscope's tip, particularly when there is more bleeding.

## ORCID

Manik Rao Kulkarni  <https://orcid.org/0000-0002-8507-0598>

Sushmitha V Badiger  <https://orcid.org/0000-0003-0970-1076>

Nasreenbanu Khadarnayakar  <https://orcid.org/0000-0002-2804-6559>

## REFERENCES

- Jain S, Bhalerao P, Singh C. A new endoscopic and anatomical classification of deviated nasal septum with clinical relevance. *Med Sci* 2020;24(104):2544–2554.
- Shukla RH, Nemade SV, Shinde KJ. Comparison of visual analogue scale (VAS) and the Nasal Obstruction Symptom Evaluation (NOSE) score in evaluation of post septoplasty patients. *World J Otorhinolaryngol Head Neck Surg* 2020;6(1):53–58. DOI: 10.1016/j.wjorl.2019.06.00.
- Dodia MN, Shah N, Shah A. Comparative study of endoscopic septoplasty without and with endonasal-septal suturing techniques. *J res med dent sci* 2015;3(3):219. DOI:10.5455/jrmds.20153313.
- Moore M, Eccles R. Objective evidence for the efficacy of surgical management of the deviated septum as a treatment for chronic nasal obstruction: a systematic review. *Clin Otolaryngol* 2011;36:106e113. DOI:10.1111/j.1749-4486.2011.02279.x.
- Jain L, Jain M, Chauhan AN, et al. Conventional septoplasty verses endoscopic septoplasty: a comparative study. *People J Sci Res* 2011;4(2):24–28.
- Nayak DR, Balakrishnan R, Murthy KD. An endoscopic approach to the deviated nasal septum – a preliminary study. *J Laryngol. Otol* 1998;112(10):934–939. DOI: 10.1017/s0022215100142124.
- Lanza DC, Kennedy DW, Zinreich SJ. Nasal endoscopic and its surgical applications. In: Lee KJ. *Essential Otolaryngology: head and neck surgery*, 5th edn.
- Gulati SP, Wadhwa R, Ahuja N, et al. Comparative evaluation of endoscopic with conventional septoplasty. *Indian J Otolaryngol Head Neck Surg* 2009;61(1):27–29. DOI: 10.1007/s12070-009-0029-1.
- Harley DH, Powitzky ES, Duncavage J. Clinical outcomes for the surgical treatment of sinonasal headache. *Otolaryngol Head Neck Surg* 2003;129(3):217–221. DOI: 10.1016/S0194-5998(03)00623-5.
- Garzaro M, Dell'Era V, Riva G, et al. Endoscopic versus conventional septoplasty: objective/subjective data on 276 patients. *Eur Arch Otorhinolaryngol* 2019;276(6):1707–1711. DOI: 10.1007/s00405-019-05393-w.
- Gupta N. Endoscopic septoplasty. *Indian j Otolaryngol Head Neck surg* 2005;57(3):240–243. doi: 10.1007/BF03008021.
- Nawaiseh S, Al-Khtoum N. Endoscopic septoplasty: retrospective analysis of 60 cases. *J Pak Med Assoc* 2010;60(10):796–798. PMID: 21381603.
- Shah J, Roxbury CR, Sindwani R. Techniques in septoplasty: traditional versus endoscopic approaches. *Otolaryngol clin North Am* 2018;51(5):909–917. DOI: 10.1016/j.otc.2018.05.007.
- Prepageran N, Lingham OR. Endoscopic septoplasty: the open book method. *Indian J Otolaryngol Head Neck Surg* 2010; 62(3):310–312. DOI: 10.1007/s12070-010-0090-9.
- ul Haq A, Bansal C, Pandey AK, et al. Key considerations in practices and principles of endoscopic septoplasty: Lessons, mistakes and future. *Bangladesh J Otorhinolaryngol* 2021;27(2):170–176. DOI: 10.3329/bjo.v27i2.56364t.