

CASE REPORT

Management of an Intranasal Open Safety Pin Foreign Body: A Case Report

Sunil S Kewat¹, Pravin M Bhat²

ABSTRACT

Background: Foreign body in the nose is a common situation encountered by an otolaryngologist in day-to-day practice. The removal of an intranasal open safety pin has remained a difficult situation in otolaryngology practice, especially in the pediatric age-group. There are numerous challenges with very few literature guidelines for the removal of such intranasal foreign bodies. We encountered such a case of a 4-year-old female child presented with an open safety pin in skiagram. There are several kinds of literature described regarding an open safety pin in the esophagus but silent about the intranasal open safety pin and its management. We have successfully removed the open safety pin under general anesthesia in an uncooperative child. The present manuscript is an attempt to remove the enigma of an intranasal open safety pin management with a video presentation of a rare case event.

Keywords: Foreign body, Nose, Open safety pin, Pediatric otolaryngology.

Otorhinolaryngology Clinics: An International Journal (2021): 10.5005/jp-journals-10003-1371

INTRODUCTION

Ingestion of nasal foreign body is a very common condition encountered by an ENT surgeon, pediatrician as well a family physician in the outpatient department (OPD). There is much diversity found in the types of nasal foreign body and hence always remains a challenging condition for removal.¹ Intranasal foreign bodies are most commonly seen in the pediatric age-group and mentally challenged patients while rarely seen in an adult patient. The intranasal foreign bodies reported in adults are mostly due to accidental injuries, trauma to the nose, and psychiatric condition of patients.² There are two types of intranasal foreign bodies: inanimate foreign bodies and animate foreign bodies. The commonly seen inanimate intranasal foreign bodies are nuts, piece of paper, beads, coins, eraser, bullets, pencils, chalk, sponge, thermocol, springs, and other metallic small things, including ornament part, and battery cell (Fig. 1). The animate foreign bodies are typically the myiasis caused due to fly maggots (Fig. 2). Some of the inert material foreign bodies may remain undetected for years and may cause congestion of nasal mucosa, ulceration, granulation, rhinolith, and recurrent epistaxis. Intranasal foreign bodies may be found unilaterally or bilaterally. The common locations are the floor of the nose below the inferior turbinate, anterior to the middle turbinate, and rarely in posterior choana.³ The open safety pin in the nose is a rare condition and inadequate literature is available about the same. The aerodigestive tract, tracheobronchial tree, and esophagus are the sites for open safety pin reported in the literature. The management of removal of open safety pin in nose remains a challenging situation in otolaryngology practice.⁴

In the present manuscript, we are reporting a case of an intranasal open safety pin, which is a rare condition. Usually closed safety pin can be seen in patients but in the present case, a closed safety pin was ingested in the nose by a 4-year-old female child and parents attempted to remove it at home and it gets opened accidentally during the attempt by parents, then they brought the patient in an emergency to the clinic.

¹Shri Sushrut ENT Clinic, Chikhali, Maharashtra, India

²Department of Shalakyatantra, MAMs Sumatibhai Shah Ayurved College, Pune, Maharashtra, India

Corresponding Author: Pravin M Bhat, Department of Shalakyatantra, MAMs Sumatibhai Shah Ayurved College, Pune, Maharashtra, India, Phone: +91 09860233173, e-mail: vdpravin82@gmail.com

How to cite this article: Kewat SS, Bhat PM. Management of an Intranasal Open Safety Pin Foreign Body: A Case Report. *Int J Otorhinolaryngol Clin* 2021;13(2):43–46.

Source of support: Nil

Conflict of interest: None

CASE DESCRIPTION

A 4-year-old female child was presented to the ENT clinic as an emergency with an ingested intranasal foreign body in the left nostril while playing with a cousin who witnessed the ingestion of a safety pin by the child. The parents were given the history of ingestion of a closed safety pin in left nostril 1 day back and the father of the child attempted to remove it at home and during the attempt accidentally it got opened and slipped deep near the nasopharynx. The child was hyperactive.

Systemic Examination

The general condition of the child was stable, and there was no respiratory distress. The respiratory rate was 16/minute, and pulse rate was 82/minute. The cardiovascular system (CVS) and central nervous system (CNS) were normal. There was no active epistaxis. There was mucous discharge in the nasal cavity, and the oropharynx was normal. However, the patient was having enlarged adenoids seen in lateral view of X-ray.

Nasal Examination and Radiography

The patient was uncooperative for nasal endoscopic examination due to multiple foreign body removal attempts by parents. On

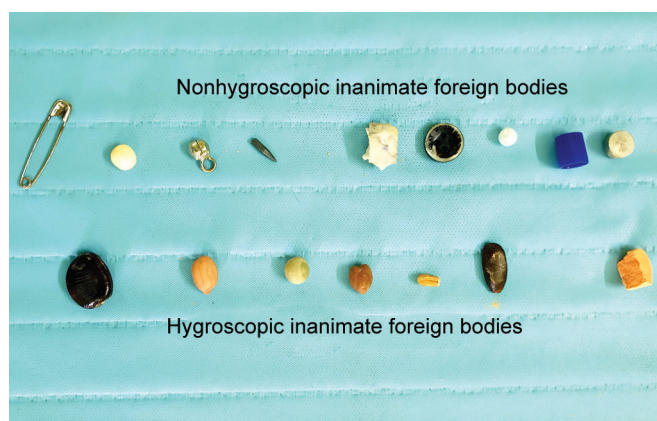

Fig. 1: Inanimate foreign bodies



Fig. 2: Animate foreign bodies (myiasis)

anterior rhinoscopic examination, only mucous secretions are seen in both nostrils and the foreign body was not visualized. So an emergency radiological examination was done by taking the X-ray skull anteroposterior (AP) view and lateral view. The radiographs revealed an open safety pin in the left nasal cavity (Figs 3 and 4) with hypertrophied adenoids. The spear was directed toward the roof of the nasal cavity. The keeper part of the safety pin was facing toward anterior to the nostril while the spring part toward the nasopharynx.

PROCEDURE

The patient was kept nil by mouth for 4 hours and taken to operation theater for endoscopic foreign body removal. The procedure of removal was planned under short general anesthesia with oral intubation. After oral intubation, a pharyngeal pack of wet gauze tape was kept to avoid accidental trickle down of foreign body in laryngopharynx. As a safety precaution, a pediatric feeding tube was inserted from the right nostril and the tip was brought out from the oral cavity for palatal elevation. The reason behind this is if a foreign body does not come out anteriorly then it can be pushed back and removed by holding the end part through oral cavity.

Nasal endoscopy was done with a 4-mm 0° rigid endoscope (Hopkins, Germany). The head of the open safety pin was partially

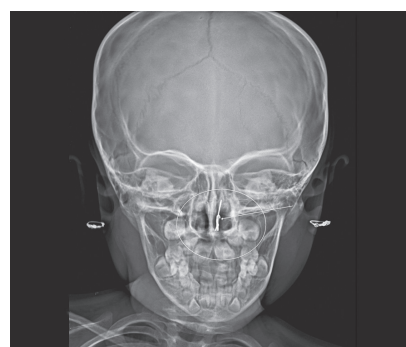

Fig. 3: Skull AP view showing metallic pin in left nostril

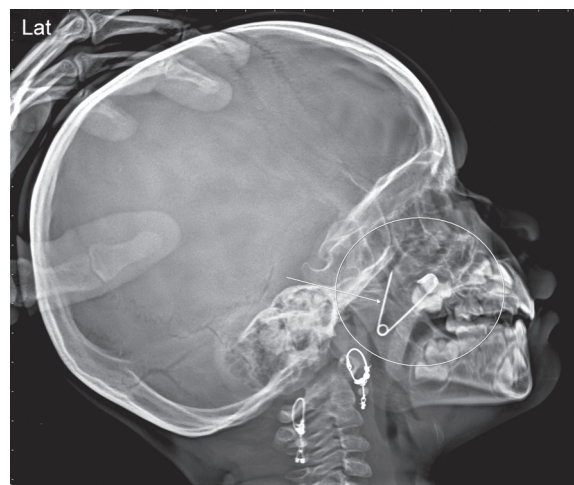

Fig. 4: Lateral view of skull demonstrating the open safety pin in nostril. The keeper shaft rest on floor while point shaft is directed upward

visualized at the floor of the nasal cavity while the end and sharp tip of the spear of pin were not visible. Decongestant nasal drops of xylometazoline 0.05% were instilled in the nose. After the decongestion effect, the head of the safety pin was visualized. An angled House micro-cup forceps (Santosh Surgical, Mumbai, India) (generally used for microscopic ear surgery) was used and the head of safety pin was held in forceps (Fig. 5). The safety pin was pulled anteriorly as possible as a surgeon can manage, but due to the open safety pin and its sharp tip of spear, it was not possible to come out of nasal cavity. Then the head of the pin was held by hemostatic forceps (Santosh Surgical, Mumbai, India) by the assistant. Again with the help of a straight House micro-cup forceps, spear part of the pin was held and both the head and spear part of the pin were pushed slightly posterior to dislodge the sharp end of the spear and then the pin was pulled out by the surgeon and assistant slowly and simultaneously and the safety pin was removed uneventfully (Video 1). There was no mucosal tear or epistaxis seen after the procedure. Review endoscopy was done, and mild oozing was noted near the adenoid region. A small nasal pack was kept in the left nostril, which was removed on the second day. The patient was reviewed on the 5th day; on examination, there was a healthy nasal cavity.

Video 1: Management of open safety pin in nose

Above mentioned video is available online on the website of www.aijoc.com

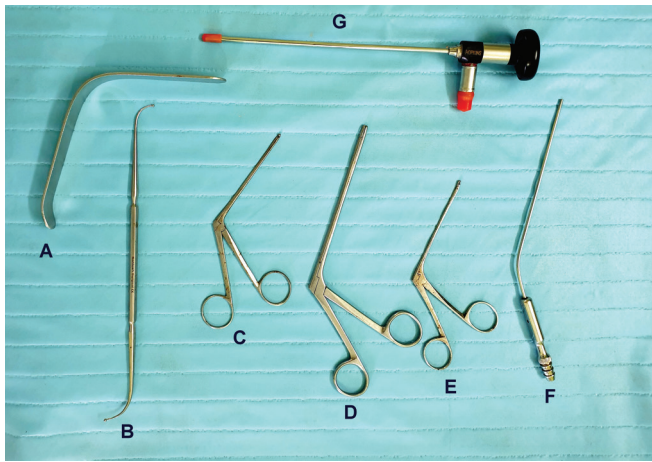


Fig. 5: Instruments used for procedure—(A) Lacks tongue depressor; (B) Ball probe; (C) House micro-cup forceps—angled; (D) Blakesley straight nasal forceps; (E) House micro-cup forceps—straight; (F) Nasal suction cannula; (G) 0° rigid endoscope

DISCUSSION

Foreign bodies in ENT practice is a common condition and can be found often in the nose and ear. The majority of patients are reported in between the age-group of 2–4 years of age.⁵ The most common foreign bodies reported are seeds followed by plastic beads.¹ The most common location in the nose is the floor of the nose below the inferior turbinate or anteriorly to the middle turbinate.⁶ The signs and symptoms need to assess very carefully in the case of nasal foreign body. These include unilateral nasal obstruction, epistaxis, discharge, foul smelling, pain, and tenderness at the nasal pyramid region. These signs and symptoms may vary as per the nature of foreign body and duration it remained in the nostrils. Many times a round foreign body like a bead or battery cell may dislodge posteriorly and can cause airway obstruction. The misdiagnosis may lead to fatal complications. The prevalence of foreign bodies in the right nostril is more because most of the people are right handed.⁷ However, the case we are presenting was right handed but having a foreign body in the left nostril. The present case was a hyperactive child who had inserted the safety pin in the nose. There is an association between the self-insertion of nasal foreign body in the nose and hyperactive disorders in children, which we have taken into consideration before attempting the removal of open safety pin.⁸

The diagnostic procedure includes torchlight/headlamp examination primarily. If the foreign body is not visualized then nasal endoscopy can be done in cooperative children and adult patients. But in uncooperative children and adult patients if a nasal foreign body is not visualized in a primary examination then the clinician can proceed for plain radiograph or computed tomography (CT) scan with sinus view.⁹ An utmost care should be taken before advising MRI in cases where a magnetic foreign body is suspected or witnessed by relatives of the patient. Such cases may lead to tissue necrosis.¹⁰

The removal attempt of the nasal foreign body by laypersons like relatives and unskilled/untrained healthcare professionals may lead to complications.¹¹ We have observed in the present case that the father of the child attempted to remove the closed safety pin ingested by the child at home and it gets open accidentally, which made the ENT surgeon difficult to remove it. There are various

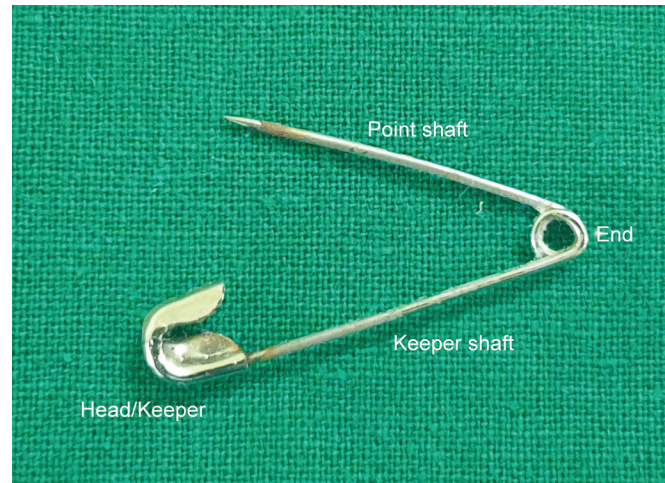


Fig. 6: Parts of an open safety pin

approaches of nasal foreign body removal explored in the literature as positive pressure technique, suctioning, Foley's catheter, removal with instruments, and by using magnets and medical adhesive glue.¹² Since the present case is of open safety pin, we preferred to go for removal with instruments. Open safety pin in the nose is a rare presentation among nasal foreign bodies.¹³ The safety pin has the parts as a keeper/head, spring, spear/point, keeper shaft, and a pointed shaft (Fig. 6).

There are various options for the removal of open safety pin described in the literature. Dislodgement of the shaft of the pin to the posterior side and attempt to close it for removal, cutting the shaft of the pin in two pieces and removal or controlled pushing of the pin toward the nasopharynx and then removal with curved forceps are some of the methods described.^{14–16}

The management of removal of open safety pin in the nose has remained an enigma in otolaryngology practice. The closing of the pin during the removal attempt may not be a useful option always as it may lead to slipping of the pin to airway. The easily visualized open safety pin can be removed with this method but when the keeper shaft is not visualized then otolaryngologists can be considered other options. The cutting of the keeper shaft near the spring of an open safety pin intranasal and remove it into two pieces is a skillful procedure. But during the removal, the cut ends may lacerate the nasal mucosa or pharyngeal mucosa. The deep-seated open safety pin after cutting the soft may perforate the soft palate. The presence of adenoids is also an additional concern in children during removal of the cut end part of open safety pin from the mouth. The controlled pushing of the pin toward the nasopharynx and then removal with curved forceps are the methods we have attempted in the present case. The additional precaution taken in this case was keeping the wet gauze in the throat near the tube inserted so that even if it gets slipped deep it can be caught into a gauze piece inserted and can be removed from the mouth.

In this way, a successful attempt was made to remove the open safety pin in the nose uneventfully under short general anesthesia.

PARENT'S PERSPECTIVE

Initially, the parents of child were very upset due to safety pin ingestion by the child in her nose. The child was also uncooperative and hyperactive. But after the counseling and removal of the open

safety pin under short general anesthesia made, the parents relaxed as they attempted to remove it at home initially before bringing the child to OPD. Parents' perspective was in their own words in local language (~marathi). The same is uploaded as a supplementary material.

Informed Consent

As the patient was a minor, informed consent was obtained from her father in a structured format. The same was explained to him and he has willingly given consent for the removal of open safety pin in the nose. Signed consent form was uploaded.

CONCLUSION

The nasal foreign bodies are of great concern to deal with as an emergency during otolaryngology practice. These can be removed successfully without any complications. However, when a case like open safety pin in the nose ingested by a child came to an emergency department, then the various techniques of removal should be taken into consideration as per the site of the lodged open safety pin. The expert anesthetist services and availability of all instruments and equipment while practicing in rural area and dealing with such nasal foreign bodies are very important factors for success. The most serious possibility of slipping of the foreign body into airway should also be taken care while dealing with open safety pin in the nose. The use of proper diagnostic tools and quick decisions along with skills are necessary to deal with open safety pin in the nose.

ACKNOWLEDGMENTS

- Dr Sandeep Wagh, Radiologist, Wagh Diagnostic Center, Chikhali, Maharashtra, India.
- Dr Aditi Khedekar, Anesthesiologist, Chikhali, Maharashtra, India.

ORCID

Sunil S Kewat  <https://orcid.org/0000-0003-0860-8400>

Pravin M Bhat  <https://orcid.org/0000-0003-3666-1479>

REFERENCES

1. Sajid T, Shah MI, Qamar Naqvi SR. Pattern of presentation of nasal foreign bodies, an experience with 155 patients. *J Ayub Med Coll Abbottabad* 2018;30(4):548–550. PMID: 30632334.
2. Burduk PK, Garstecka A, Betlejewski S. Nasal foreign body in an adult. *Eur Arch Otorhinolaryngol* 2005;262(6):517–518. DOI: 10.1007/s00405-004-0894-x. PMID: 15735953.
3. Kalan A, Tariq M. Foreign bodies in the nasal cavities: a comprehensive review of the aetiology, diagnostic pointers, and therapeutic measures. *Postgrad Med J* 2000;76(898):484–487. DOI: 10.1136/pmj.76.898.484. PMID: 10908376; PMCID: PMC1741675.
4. Sen I, Sikder B, Sinha R, et al. Open safety pin in the nasal cavity. *Indian J Otolaryngol Head Neck Surg* 2004;56(2):129–131. DOI: 10.1007/BF02974317. PMID: 23120052; PMCID: PMC3451324.
5. Kadish HA, Corneli HM. Removal of nasal foreign bodies in the pediatric population. *Am J Emerg Med* 1997;15(1):54–56. DOI: 10.1016/s0735-6757(97)90049-8. PMID: 9002571.
6. DeWeese D, Saunders AH. Acute and chronic diseases of the nose. In: DeWeese DD, Saunders AH, editors. *Textbook of otolaryngology*. St Louis (MO): CV Mosby; 1982.
7. Okoye BC, Onotai LO. Foreign bodies in the nose. *Niger J Med* 2006;15(3):301–304. DOI: 10.4314/njm.v15i3.37235. PMID: 17111765.
8. Celenk F, Gokcen C, Celenk N, et al. Association between the self-insertion of nasal and aural foreign bodies and attention-deficit/hyperactivity disorder in children. *Int J Pediatr Otorhinolaryngol* 2013;77(8):1291–1294. DOI: 10.1016/j.ijporl.2013.05.012. PMID: 23751280.
9. Glynn F, Amin M, Kinsella J. Nasal foreign bodies in children: should they have a plain radiograph in the accident and emergency? *Pediatr Emerg Care* 2008;24(4):217–218. DOI: 10.1097/PEC.0b013e31816a9f1b. PMID: 18431219.
10. Yeh B, Roberson JR. Nasal magnetic foreign body: a sticky topic. *J Emerg Med* 2012;43(2):319–321. DOI: 10.1016/j.jemermed.2010.02.013. PMID: 20381988.
11. Figueiredo RR, Azevedo AA, Kós AO, et al. Complications of ent foreign bodies: a retrospective study. *Braz J Otorhinolaryngol* 2008;74(1):7–15. DOI: 10.1016/s1808-8694(15)30744-8. PMID: 18392495.
12. Chan TC, Ufberg J, Harrigan RA, et al. Nasal foreign body removal. *J Emerg Med* 2004;26(4):441–445. DOI: 10.1016/j.jemermed.2003.12.024. PMID: 15093852.
13. Gupta G, Verma P, Grover M, et al. Open safety pin in nose: a tricky foreign body. *Int J Clin Rhinol* 2010;3(1):43–44.
14. Salley LH Jr, Wohl DL. Nasal foreign body: removal of an open safety pin from the left nostril. *Ear Nose Throat J* 2000;79(2):118–120. PMID: 10697937.
15. Utrata J. Erosion of the soft palate by a foreign body in the nose. *Ear Nose Throat J* 1977;56(10):403–404. PMID: 902617.
16. Sen I, Sikder B, Sinha R, et al. Open safety pin in the nasal cavity. *Indian J Otolaryngol Head Neck Surg* 2004;56(2):129–131. DOI: 10.1007/BF02974317. PMID: 23120052; PMCID: PMC3451324.