

# Symptomatic Septal Deviation: Its Nasal Endoscopy and Computed Tomography-aided Correlation with Chronic Rhinosinusitis

Shruti Tandon<sup>1</sup>, Vijay Giridher<sup>2</sup>, Akash Juneja<sup>3</sup>

## ABSTRACT

**Aim:** To evaluate the nasal septal deviation by measuring the angle of deviation and study its relation with sinus diseases and lateral nasal wall anomalies, by diagnostic endoscopy (DNE) and computed tomography (CT), in patients of chronic rhinosinusitis (CRS).

**Materials and methods:** A prospective study was carried out on 90 patients with nasal complaints and deviated septum, attending the Department of Otorhinolaryngology, from January 2015 to August 2016. Patients were diagnosed to have CRS clinically and were subjected to DNE and CT scans. The maximum angle of septal deviation was calculated in coronal cuts. The side and sites of rhinosinusitis and lateral wall anatomical variants were identified.

**Results:** The prevalence of CRS was 73%, with males more affected than females (1.8:1). Left-sided and C-shaped DNS were most common. Fifty-two percent patients suffering from CRS had septal angle of deviation between 7° and 12°, and 46% had more than 12°. Maxillary sinus was the most commonly involved sinus. Concha bullosa (32%) was the most common variant noted. Occurrence of medialized uncinate process was found to be increasing on the ipsilateral side of deviated septum with increasing angle of deviation.

**Conclusion:** In patients with chronic sinusitis, most of the angles were deviated between 7° and 12°. The mean deviation was 12.92°. Majority of patient with chronic rhinosinusitis had a concurrent variation along with the deviated nasal septum. No correlation was found between the side of deviated nasal septum and side of maxillary sinusitis. No correlation was noted between the anatomical variants of lateral nasal wall with increasing angle of deviation.

**Clinical significance:** Our study emphasizes the multifactorial etiology behind CRS with plausible role of genetic factors, environmental influence, allergic factors, and hormonal influence, etc., in its causation.

**Keywords:** Angle of septal deviation, Deviated nasal septum, Lateral wall variant, Prevalence of chronic rhinosinusitis, Prospective study, Rhinosinusitis.

*Otorhinolaryngology Clinics: An International Journal* (2019); 10.5005/jp-journals-10003-1325

## INTRODUCTION

Sinusitis affects one in seven adults<sup>1</sup> and is one of the most common disease of the nose and paranasal sinuses. Fifty million individuals diagnosed with sinusitis every year world over. Chronic rhinosinusitis (CRS) refers to a group of disorders characterized by inflammation of mucosa of nose and paranasal sinuses for more than 12 weeks. According to an analysis of the National Health Interview Survey data 2008,<sup>2</sup> chronic rhinosinusitis causes significant patient morbidity in terms of a negatively affected quality of life and substantial impairment of daily functioning resulting in decreasing overall productivity.

Identifying the predisposing factors for chronic sinusitis is very important. The current hypothesis involves a multifactorial pathogenesis. These include allergy, asthma, dental disease, nasal polyps, immunodeficiency, mucociliary disorders, trauma, medications, surgery, noxious chemicals, microorganisms (viral, bacterial, and fungal), and anatomic abnormalities, such as, a septal deviation, concha bullosa, septal spur, or paradoxical turbinate. Paranasal sinus and nasal cavity anatomical variants are usual findings with an estimated prevalence of 65%.<sup>3</sup> The effects of anatomical variations and their obstructive effect on sinus diseases have been investigated widely.<sup>4</sup>

Septal deviation refers to convexities of the septum to one side with accompanying deformities of the midline structures.<sup>5</sup> A marked deviation of portion or of entire nasal septum may cause not only obstructed nasal breathing but also disease within the lateral nasal

<sup>1-3</sup>Department of Otorhinolaryngology, Jaipur Golden Hospital, New Delhi, India

**Corresponding Author:** Shruti Tandon, Department of Otorhinolaryngology, Jaipur Golden Hospital, New Delhi, India, Phone: +91 8826208640, e-mail: dr.shrutitandon2@gmail.com

**How to cite this article:** Tandon S, Giridher V, Juneja A. Symptomatic Septal Deviation: Its Nasal Endoscopy and Computed Tomography-aided Correlation with Chronic Rhinosinusitis. *Int J Otorhinolaryngol Clin* 2019;11(1):5-8.

**Source of support:** Nil

**Conflict of interest:** None

wall and consecutively in paranasal sinuses. Patients with increasing nasal septal deviation are associated with a higher incidence of ostiomeatal complex (OMC) obstruction. Ostiomeatal complex obstruction in the direction of septal angulation is attributable to the nasal septal deformity; however, contralateral OMC obstruction is related to middle turbinates and lateral nasal wall abnormalities.<sup>5</sup>

In this study, we will evaluate the nasal septal deviation by measuring angle of septal deviation and will study the role and relation of degree of septal deviation on lateral wall of nose and sinus diseases, prevalence of ostiomeatal complex variations, and their correlation with degree of septal deviation and occurrence of CRS if any, by both endoscopic and computed tomographic evaluation in patients of chronic rhinosinusitis.

## MATERIALS AND METHODS

This study is a prospective cross-sectional observation carried out on 90 patients from January 2015 to August 2016. Patients >15 years presenting with nasal complaints having deviated nasal septum on anterior rhinoscopy were included in the study.

All patients with history of recent nasal trauma, nasal polyp on anterior rhinoscopy, septal perforation, allergic rhinitis, aggressive fungal infections, odontogenic sinusitis, neoplasia, immunodeficiency and mucociliary disorders, prior history of nasal or sinus surgery, and adenoid hypertrophy were excluded from the study.

The included patients underwent a complete otorhinolaryngological examination. Deviated nasal septum (DNS) if any was noted on anterior rhinoscopy. The patients having DNS were evaluated further and diagnosed clinically to have chronic rhinosinusitis. Diagnostic nasal endoscopy and noncontrast computed tomography were performed on patients to confirm and support the diagnosis. The maximum angle of deviation of the septum was calculated in coronal cuts (Fig. 1). The image that best defined the OMC was utilized for the calculation of the direction and angle of septal deviation. The superior attachment of the nasal septum at the crista galli, its inferior insertion at the level of the anterior nasal spine, and most prominent point of nasal septal deviation were all identified and the resultant angle was noted and graded in three predecided groups.

- Group I: 0–6°.
- Group II: 7–12°.
- Group III: >12°.

Computed tomography and diagnostic nasal endoscopy findings were further studied to find the side and site of rhinosinusitis, patency of OMC, and anatomical variants.

## Statistical Testing

The statistical package for the social science system version SPSS 17.0 was used. Continuous variables will be presented as mean  $\pm$  SD or median if the data will be unevenly distributed. Categorical variables will be expressed as frequencies and percentages. The comparison of normally distributed continuous variables between the groups will be performed using Student's *t* test. Nominal categorical data between the groups will be compared using

Chi-squared test or Fisher's exact test as appropriate. Non-normal distribution continuous variables will be compared using Mann–Whitney *U* test. For all statistical tests, a *p* value of less than 0.05 will be taken to indicate a significant difference.

## RESULTS

Among 90 patients aged between 15 years and 70 years, majority (33.3%) belonged to age group of 21–30 years. Male to female ratio was 1.8:1.

The prevalence of chronic rhinosinusitis was noted to be 73% in the studied population.

Left-sided deviated septum (31.1%) was most common. Amongst the bony spurs, left (19%) was more common than the right (13%). S-shaped deviation was present in 10% of patients.

The most common group of septal angle deviation was group II. The involvement of different groups of septal deviation was 6%, 52%, and 42%, respectively. The mean deviation was 12.92° (Table 1).

Maxillary sinus (55%) was the most commonly involved sinus. No correlation was found between the side of deviated septum and side of maxillary sinusitis ( $p = 0.283$ ).

Seventy-one percent patients showed that presence of concurrent variations along with the presence of deviated nasal septum concha bullosa (32%) was the most common variant noted.

On evaluating the degree of septal deviation with occurrence of anatomical variants, in intragroup comparison, there was no statistically significant relation in ipsilateral vs contralateral occurrence of variants (Table 2).

On intergroup comparison, medialized uncinate process was found to be increasing on the ipsilateral side of deviated septum with increasing angle of deviation ( $p = 0.078$ ). There was no statistically significant increase in occurrence of ipsilateral or contralateral variants with increasing angle of deviation (Table 3).

## DISCUSSION

The study was conducted on 90 patients of both sexes, above 15 years, who presented to the ENT OPD with nasal complaints and a deviated nasal septum during the period from January 2015 to August 2016.

Our study population had majority of the patients belonging to the age group of 21–30 years with male to female ratio 1.8:1. This is in concordance with the study carried out by Sood<sup>6</sup> and Sinha.<sup>7</sup> The probable explanation of disease being most common in middle age is that people in this age group are more exposed to environmental pollution, are more aware and conscious of their health, and can access medical facilities at the earliest.

The prevalence of CRS in the study population was noted to be 73%. Many plausible explanations are made to establish relation between the nasal septal deviation and chronic rhinosinusitis. The mechanical theory of Stammberger says that retention of secretions

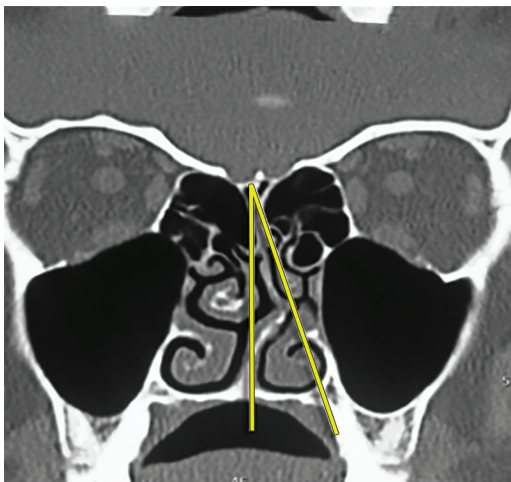


Fig. 1: Deviated septal angle measurement

Table 1: Distribution of angles of septal deviation in predecided groups

Group	Patients with CRS	
I (0–6)	4	6%
II (7–12)	34	52%
II (>12)	28	42%
Total	66	
Mean	12.92°	
Range	3–25°	

**Table 2:** Intragroup comparisons of lateral wall variants and severity of deviated septum

	Group I (0–6)			Group II (7–12)			Group III (>12)		
	I/L	C/L	p value	I/L	C/L	p value	I/L	C/L	p value
OMC obstruction	1	1	1.000	10	10	0.643	7	6	0.550
Concha bullosa	3	2	1.000	6	9	0.577	4	6	0.717
Enlarged bulla ethmoidalis	0	0	–	4	4	0.804	2	2	1.000
Uncinate medialization	0	0	–	0	1	1.000	3	3	1.000
Paradoxical MT	0	1	1.000	3	3	1.000	1	2	1.000

**Table 3:** Intergroup comparison of lateral wall variants (contralateral and ipsilateral side) and severity of septal deviation

		Group I	Group II	Group III	p value
OMC obstruction	I/L	1	10	7	0.786
	C/L	1	10	6	0.772
Concha bullosa	I/L	3	6	4	0.111
	C/L	2	9	6	0.74
Enlarged bulla ethmoidalis	I/L	0	4	2	0.62
	C/L	0	4	2	0.637
Medialized uncinate process	I/L	0	0	3	0.078
	C/L	0	1	3	0.318
Paradoxical middle turbinate	I/L	0	3	1	0.593
	C/L	1	3	2	0.697

in the sinus due to narrowed ostiomeatal complex becomes a focus for infection and leads to chronic rhinosinusitis. According to aerodynamic theory, due to nasal septal deviation, the mucociliary activity decreases, nasal flow rate increases, and mucosal dryness occurs leading to chronic rhinosinusitis. The third theory is the Bachert's pressure theory. According to this theory, deviation of the posterior nasal septum causes chronic rhinosinusitis by creating pressure and airflow changes within the maxillary sinuses. Previous studies by Moorthy,<sup>8</sup> Kolloju, Madhira, and Jowkar reported that the incidence of CRS in patients with complaints of nasal blockage was 65%.

In study done by Shoib et al.<sup>9</sup> in 2016, C-shaped deviation with spur (L) was present in 20.5%, Poorey et al. and Dipak Ranjan et al. found left-sided DNS to be more common.<sup>5</sup> In a study by Moorthy et al.,<sup>8</sup> C-shaped deviation to left was seen in 55%, C-shaped deviation to right in 35%, and S-shaped deviation in 10% of cases. Similar findings were noted in our study.

Fifty-two percent patients of chronic rhinosinusitis had angle of septal deviation in the group of 7–12°, and 42% patients of chronic rhinosinusitis had angle of septal deviation of more than 12°, while only 6% of the studied population had angle of septal deviations falling in 0–6° group. The mean deviation is 12.92°, while the range is from 3 to 25°. In a study done by Poorey et al., 56.7% of the patients had moderate DNS, i.e., between 6 and 10 followed by severe (>11) in 22.4%, and then mild (0–6°) in 20.9%, which are similar to our study.<sup>5</sup>

As per Mohebbi et al., maxillary sinus was the most commonly involved sinus, while frontal and sphenoid sinus being less involved, which is in concordance with our study.

In our study, 11 patients with right-sided DNS had right maxillary sinus involvement while 9 patients with right-sided DNS had left maxillary sinus involvement. Fourteen patients with left-sided DNS had right maxillary sinus involvement and 21 had right maxillary

sinus involvement. The *p* value was calculated to be 0.283, which is statistically insignificant. Thus, no correlation was found between side of deviated nasal septum and side of maxillary sinusitis.

In our study, 71% patients of chronic rhinosinusitis showed presence of a concurrent variation along with the presence of deviated nasal septum, while 29% patients of chronic rhinosinusitis had only deviated nasal septum as the sole anomaly. In a study by Moorthy et al. 2014, it was showed that deviated nasal septum can be associated with significant sinonasal disease even in absence of any nasal symptoms.<sup>8</sup>

In our study, concha bullosa was the most common variant noted in 32% of patients. The prevalence in the study group is less as compared to the earlier reports of 53.6% by Bolger et al. Seventy-three percent by Perez-Pinas et al., 67% by Scribano et al., and more when compared to studies by Zinreich et al. Llyod et al. reported further less prevalence of about 15%, 14%, and 15%, respectively. The prevalence of concha bullosa in our study group is comparable to when compared to the findings of Wani et al., Dua et al., and Asruddin et al. who reported the prevalence to be 36%, 30%, and 28%, respectively.

On comparing intragroup occurrence of anatomical variants on ipsilateral and contralateral side of septal deviation, it was noted that there was no difference statistically between ipsilateral and contralateral, osteomeatal complex blockage, occurrence of concha bullosa, enlargement of ethmoidal bulla, and medialization of uncinate process. There is no relation of side of paradoxically rotated middle turbinate with increasing deviation of nasal septum. On comparison between ipsilateral anatomical variants and increasing angle of septal deviation, no statistically significant relation was found in obstruction of osteomeatal complex (*p* = 0.786), occurrence of concha bullosa (*p* = 0.111), and enlargement of bulla ethmoidalis (*p* = 0.620) but incidence of medialized uncinate process was found to be higher with increasing septal angles.

Similar findings were found between occurrences of anatomical variants on opposite side.

Calhoun et al.<sup>10</sup> showed a strong correlation between septal deviation and sinus disease, although the degree of septal deviation was never quantified. They further documented a significant association with OMC obstruction and ethmoid sinus disease only on the side to which the septum was deviated, whereas Elahi et al.<sup>11</sup> found increasing OMC disease bilaterally with increasing septal deviation. As per Poorey et al.,<sup>5</sup> increasing angle of septal deviation was associated with bilateral sinus disease and contralateral middle turbinate abnormalities and contralateral ethmoid bulla prominence. But in our study, we did not find any such correlation. Incidence of medialized uncinate process was found to increase clinically with increasing septal angles, though statistical correlation needs a larger sample size ( $p = 0.078$ ).

## CONCLUSION

Sinusitis is one of the most common diseases of the nose and paranasal sinuses, which affects a significant portion of the global population and has diverse socioeconomic impact. Thus, it needs to be studied in detail.

The prevalence of chronic rhinosinusitis was 73%, with males more affected than females. Left-sided septal deviation was most common. C-shaped deviations were more common than the septal spur. In patients with chronic sinusitis, most of the angles were deviated between 7° and 12°. The mean deviation was 12.92°. Maxillary sinus was the most commonly involved sinus and side of involved maxillary sinus was not associated statistically with side of deviated septum. Majority of patient with chronic rhinosinusitis had a concurrent variation along with the deviated nasal septum, while concha bullosa was the most common variant noted. No correlation was noted between the anatomical variants of lateral nasal wall with increasing angle of deviation. Incidence of medialized uncinate process was found to be increasing on the ipsilateral side of deviated septum with increasing angle of deviation, though a larger sample size is needed to prove the statistical significance.

## CLINICAL SIGNIFICANCE

There is a need to educate general masses about the symptoms of chronic sinusitis and its effect on quality of life, in order to increase its prevention, diagnosis, treatment, and control. Patients should be made aware of the possible sequelae of it if left untreated. Although several hypotheses have been proposed over deviated nasal septum

and its impact on chronic rhinosinusitis, our study could not find a statistical correlation. Thus, a longer study with larger sample size is suggested. In our study, the occurrence of anatomical variations of lateral nasal wall could not be related to degree of deviated nasal septum. More research is thus recommended involving these parameters to evaluate the association. Our study reemphasizes the multifactorial etiology behind chronic rhinosinusitis with plausible role of other etiologies like genetic, environmental influence, allergic factors, and hormonal influence, etc., in its causation. Thus, we recommend inclusion of the said factors in the study, with a larger sample size, and may be multicentric in location.

## REFERENCES

1. Anon JB, Jacobs MR, Poole MD, et al. Antimicrobial treatment guidelines for acute bacterial rhinosinusitis. *Otolaryngol Head Neck Surg* 2004;130(1 Suppl):1–45. DOI: 10.1016/j.otohns.2003.12.003.
2. Pleis JR, Lucas JW, Ward BW. Summary health statistics for U.S. adults: National Health Interview Survey, 2008. *Vital Health Stat* 2009;10(242):1–157.
3. Bolger WE, Butzin CA, Parsons DS. Paranasal sinus bony anatomic variations and mucosal abnormalities: CT analysis for endoscopic sinus surgery. *Laryngoscope* 1991;101(1 Pt 1):56–64. DOI: 10.1288/00005537-199101000-00010.
4. Stammberger H, Wolf G. Headaches and sinus disease: the endoscopic approach. *Ann Otol Rhinol Laryngol Suppl* 1988;134:3–23. DOI: 10.1177/000348948809705501.
5. Poorey VK, Gupta N. Endoscopic and computed tomographic evaluation of influence of nasal septal deviation on lateral wall of nose and its relation to sinus disease. *Indian J Otolaryngol Head Neck Surg* 2014;66(3):330–335. DOI: 10.1007/s12070-014-0726-2.
6. Sood VP. Nasal and sinus endoscopy. *Indian J Otolaryngol* 1990;42(4):143–146.
7. Sinha DK. Nasal and sinus endoscopy in opaque maxillary antrum. *Indian J Otolaryngol Head Neck Surg* 1993;45(3):145–146. DOI: 10.1007/BF03054717.
8. Moorthy PNS, Kolloju S, Madhira S, et al. Clinical study on deviated nasal septum and its associated pathology. *Int J Otolaryngol Head Neck Surg* 2014;3:75–81. DOI: 10.4236/ijohns.2014.32016.
9. Shoib SM, Viswanatha B. Association between symptomatic deviated nasal septum and sinusitis: a prospective study. *Res Otolaryngol* 2016;5(1):P1–P8.
10. Calhoun KH, Waggenspack GA, Simpson CB, et al. CT evaluation of the paranasal sinuses in symptomatic and asymptomatic populations. *Otolaryngol Head Neck Surg* 1991;104(4):480–483. DOI: 10.1177/019459989110400409.
11. Kennedy DW, Senior BA. Endoscopic sinus surgery. A review. *Otolaryngol Clin North Am* 1997;30(3):313–330.