

## CASE REPORT

# Left-sided Paraganglioma of Larynx mimicking Carcinoma: A Rare Entity

<sup>1</sup>Priya Jain, <sup>2</sup>Richa Jindal, <sup>3</sup>Kuldeep Kaur, <sup>4</sup>Molly Joseph, <sup>5</sup>Mayank Jain

## ABSTRACT

Paragangliomas are a rare group of tumors composed of neuroendocrine cells. Head and neck are the uncommon sites of its origin and very few cases have been reported so far about its origin in larynx. Most paragangliomas arise from the right side of larynx. We are hereby reporting a rare case of left-sided laryngeal paraganglioma in a 55-year-old female.

**Keywords:** Larynx, Paraganglioma, Zellballen.

**How to cite this article:** Jain P, Jindal R, Kaur K, Joseph M, Jain M. Left-sided Paraganglioma of Larynx mimicking Carcinoma: A Rare Entity. *Int J Otorhinolaryngol Clin* 2018;10(2):70-72.

**Source of support:** Nil

**Conflict of interest:** None

## INTRODUCTION

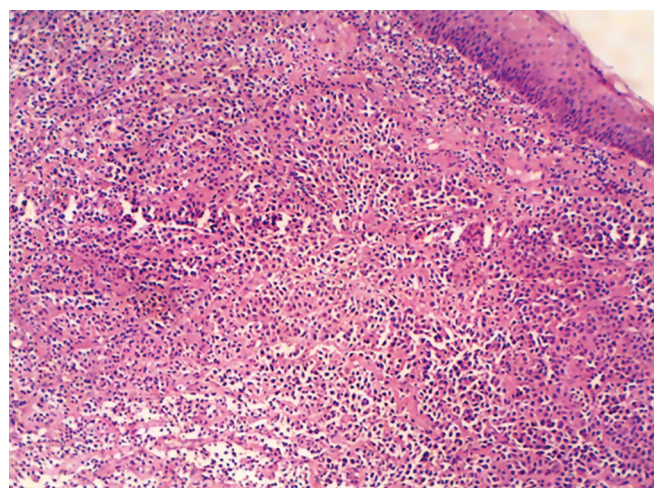
Paragangliomas are the neuroendocrine tumors that arise from the parasympathetic ganglion of our autonomic nervous system.<sup>1</sup> When these tumors arise from adrenal medulla, they are termed as pheochromocytoma, while in the extra-adrenal location, they are termed as paraganglioma.<sup>2</sup> Approximately 90% of these tumors arise in the adrenal gland, and the remaining 10% are known to have extra-adrenal origin. The neuroendocrine tumors of larynx can have epithelial as well as neural origin.<sup>3</sup> The tumors with epithelial origin include typical, atypical carcinoids, and small cell neuroendocrine carcinoma. Paraganglioma is known to have a neural origin. Less than 60 cases of laryngeal paraganglioma have been reported so far in the literature.<sup>4</sup> In this report, we are presenting another case of laryngeal paraganglioma in a female which was misdiagnosed as carcinoma of larynx clinically.

## CASE REPORT

A 55-year-old female presented to the emergency department with sudden onset respiratory distress since 2 days.

She had difficulty in swallowing since last 1 month. There was no history of trauma or loss of weight. No history of tobacco chewing was found. On physical examination, her BP was raised up to 160/100 mm Hg, which was fluctuating every hour. Her pulse rate was recorded as 100/min. She also had an episode of myocardial infarction due to fluctuating vitals. Direct laryngoscopy showed an ulceroproliferative growth measuring 2×2 cm involving left arytenoids and medial wall of pyriform fossa and interarytenoid area. The patient had to be intubated immediately after examination. A provisional diagnosis of carcinoma larynx was made. Urinary levels of catecholamines and vanillyl mandelic acid were measured, which were increased. However, calcitonin was within normal limits.

Hence, a biopsy was done and sent to the Department of Pathology which showed neoplastic cells arranged in organoid and nested pattern with a characteristic zellballen pattern (Fig. 1). Cytologically, the cells appeared benign with bland nuclear features (Fig. 2). There was no evidence of increase in mitotic activity. Focal area of necrosis was present. A provisional diagnosis of a neuroendocrine tumor of larynx was made. Immunohistochemical (IHC) stains were applied to confirm the diagnosis. On IHC analysis, tumor cells were positive for synaptophysin, chromogranin, S-100, and negative for cytokeratin, smooth muscle actin, and human melanoma black-45 (Figs 3 and 4). This confirmed the diagnosis of paraganglioma of larynx.



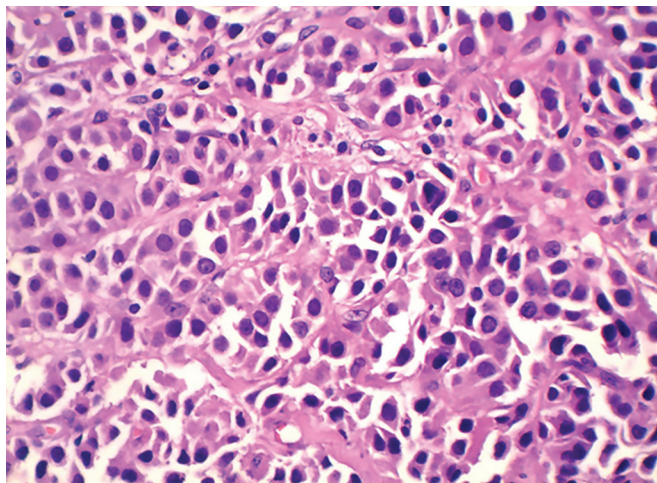
**Fig. 1:** Hematoxylin and eosin-stained section showing stratified squamous epithelium-lined tissue with cells arranged in zellballen pattern (10×)

<sup>1,5</sup>Senior Resident, <sup>2,4</sup>Consultant, <sup>3</sup>Resident

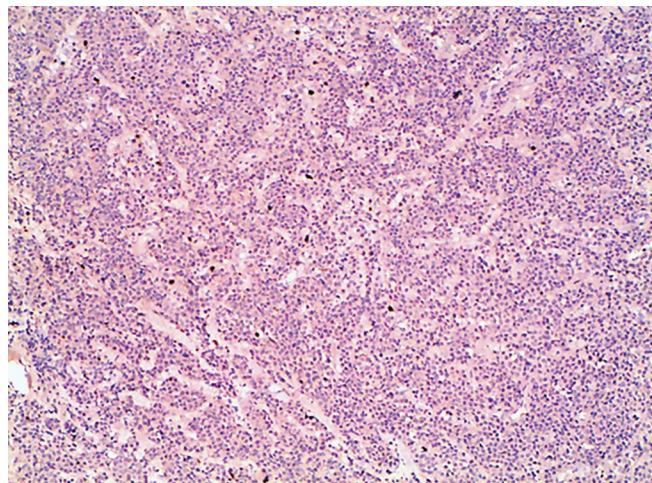
<sup>1-4</sup>Department of Pathology, St. Stephen's Hospital, New Delhi India

<sup>5</sup>Department of Pediatrics, St. Stephen's Hospital, New Delhi India

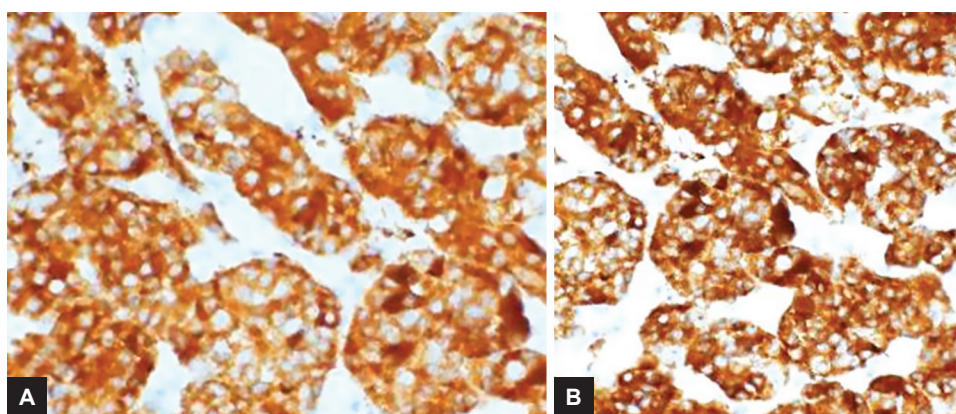
**Corresponding Author:** Priya Jain, Senior Resident Department of Pathology, St. Stephen's Hospital, New Delhi India, e-mail: priyajainsept2@gmail.com



**Fig. 2:** Hematoxylin and eosin-stained section (40×)



**Fig. 3:** S-100 stain showing sustentacular cells (10×)



**Figs 4A and B:** Synaptophysin- and chromogranin-positive cells (40×)

## DISCUSSION

Paragangliomas are benign neuroendocrine tumors with rare location in larynx. They arise from the parasympathetic ganglion present in the larynx. Larynx contains superior and inferior groups of paraganglia which serve as chemoreceptors and have a direct effect on respiration<sup>5</sup>. The lesion is mostly seen in 2nd to 8th decade of life and is three times more common in women than in men.<sup>6</sup> It is commonly seen in the supraglottic region on the right side, but few left-sided paragangliomas are also reported as is our case. Depending on the size and location, paraganglioma can be symptomatic and may present with complaints of dyspnea or hoarseness of voice.<sup>7</sup>

As previously discussed, these tumors are mostly benign in nature, only 2% of these tumors are malignant, and are often misdiagnosed as atypical carcinoids.<sup>8</sup> Microscopically, they are composed of chief cells and sustentacular cells arranged in a zellballen pattern. Mitosis, necrosis, and vascular invasion are important parameters for assessment of malignancy.<sup>9</sup> Metastatic involvement of lung, skull, and vertebral bodies has also been described in some cases.<sup>10</sup>

Paragangliomas should be differentiated from atypical carcinoids and accurate diagnosis is must, as the former is a benign tumor and latter, being malignant, has a fatal outcome.<sup>11</sup> Laryngeal paraganglioma should also be cautiously differentiated from large cell and small cell neuroendocrine tumors as the prognosis, outcome, and treatment differ in both subgroups. Clinically, they are often misdiagnosed as hemangioma, chondroma, chondrosarcoma, and salivary gland tumors.<sup>12</sup> Therefore, lab diagnosis, histopathology, and IHC staining form a major footstep for accurate diagnosis of these tumors.

Computed tomography and angiography are the main imaging modalities of choice for evaluation and diagnosis of paragangliomas. They help us to know the exact location and extent of involvement by the tumor.<sup>13</sup>

Surgical excision with free margins is the treatment of choice for paraganglioma. However, some recommend radiotherapy in cases with multicentricity.<sup>14</sup> Recently, treatment with CO<sub>2</sub> laser surgery has also been published for the treatment of laryngeal paraganglioma.<sup>15</sup>

To conclude, histopathological examination of tumor remains the mainstay for diagnosis of neuroendocrine



tumors and IHC, as well as biochemical tests like catecholamines; calcitonin is mandatory for differentiating it from other tumors of this group. Treatment of choice includes surgical excision, although various new modalities are under review.

The re-occurrence rate of these tumors is around 17% and it may be a sign of malignancy.<sup>16</sup> Therefore, regular follow-up of the patient is necessary. We followed up the patient for 3 months and she recovered well.

## REFERENCES

- Knosp WM, Knox SM, Lombaert IM, Haddox CL, Patel VN, Hoffman MP. Submandibular parasympathetic gangliogenesis requires sprout-dependent wnt signals from epithelial progenitors. *Dev Cell* 2015 Mar;32(6):667-677.
- Chen J. Paraganglioma. *Chin J Pathol* 2006;35:494-496.
- Gripp FM, Risse EKJ, Leverstein H, Snow GB, Meijer CJL. Neuroendocrine neoplasms of the larynx. Importance of the correct diagnosis and differences between atypical carcinoid tumours and small-cell neuroendocrine carcinoma. *Eur Arch Otorhinolaryngol* 1995 Jul;252(5):280-286.
- Ferlito A, Barnes L, Wenig BM. Identification, classification, treatment, and prognosis of laryngeal paraganglioma. Review of the literature and eight new cases. *Ann Otol Rhinol Laryngol* 1994 Jul;103(7):525-536.
- Barnes L, Tse LLY, Hunt JL, Michaels L. Tumors of paraganglionic system: introduction. In: Barnes L, Eveson JW, Reichart P, Sidransky D, editors. *Pathology and genetics. Head and neck tumors*. Lyon: IARC Press; 2005;362-364.
- Khademi B, Taghizadegan L, Gandomi B, Vasei M. Paraganglioma of the larynx: a case report. *Int J Med Sci* 2004;29.
- Kaytaz A, Karaman E, Edizer DT, Hacıyev Y, Oz B. Laryngeal paraganglioma: report of an unusual entity. *Ear Nose Throat J* 2010 Nov;89(11):550-552.
- Rubin AD, Cheng SS, Bradford CR. Laryngeal paraganglioma in a patient with multiple head and neck paragangliomas. *Otolaryngol Head Neck Surg* 2005 Mar;132(3):520-522.
- Khalkhali K, Nadimi-Tehrani A, Yazdani N, Azizi A. Tracheal and subglottic paraganglioma: a case report. *Acta Medica Iranica* 2005 Aug;43(5):377-380.
- Cummings C, Haughey B, Thomas R, Harker L, Robbins T, Flint P, Schuller D, Richardson M, editors. *Cummings' textbook of otolaryngology, head and neck surgery*. 4th edition. Mosby;1998.
- Ferlito A, Milory CM, Wenig BM, Barnes L, Silver CE. Laryngeal paraganglioma versus atypical carcinoid tumor. *Ann Otol Rhinol Laryngol* 1995 Jan;104(1):78-83.
- Dogan S, Senol S, Imamoglu H, Abdulrezzak U, Ekinci A, Yuce I, Ozturk M. An unusual case of laryngeal paraganglioma in a patient with carotid body paraganglioma: multimodality imaging findings. *Case Rep Radiol* 2015;2015(Article ID 342312):1-6.
- Sharifkashany S, Yazdani N, Ghazavi H, Tajdini A. Laryngeal paraganglioma: a case report. *Iran J Radiol* 2014 Aug;11(3):e21011.
- Erickson D, Kudva YC, Ebersold MJ, Thompson GB, Grant CS, van Heerden JA, Young WF Jr. Benign paragangliomas: clinical presentation and treatment outcomes in 236 patients. *J Clin Endocrinol Metab* 2001 Nov;86(11):5210-5216.
- Sesterhenn AM, Folz BJ, Lippert BM, Janig U, Werner JA. Laser surgical treatment of laryngeal paraganglioma. *J Laryngol Otol* 2003 Aug; 117(8):641-646.
- Pellitteri PK, Rinaldo A, Myssiorek D, Gary Jackson C, Bradley PJ, Devaney KO, Shaha AR, Netterville JL, Manni JJ, Ferlito A. Paragangliomas of the head and neck. *Oral Oncol* 2004 Jul;40(6):563-575.