

CASE REPORT

Laryngeal Neuroendocrine Tumor: Atypical Presentation

¹Varun Rai, ²Vikas Malhotra, ³Naresh Kumar, ⁴Nita Khurana

ABSTRACT

Neuroendocrine tumors of the larynx are the most common non-epidermoid tumors of the larynx and comprise less than 1% of the laryngeal tumors. Most of the symptoms and presentation mimic a usual laryngeal malignancy making the diagnosis difficult.

Keywords: Calcitonin, Laryngeal, Neuroendocrine tumor, Periodic acid–schiff.

How to cite this article: Rai V, Malhotra V, Kumar N, Khurana N. Laryngeal Neuroendocrine Tumor: Atypical Presentation. *Int J Otorhinolaryngol Clin* 2017;9(1):32-34.

Source of support: Nil

Conflict of interest: None

INTRODUCTION

Neuroendocrine tumors (NETs) of the larynx, which represent a heterogeneous group of neoplasm, are rare, but still are the second most common neoplastic lesion of the larynx. The first case of NET was reported by Goldman et al in 1969. Almost 500 cases of NETs have been reported in the literature so far.¹ The origin of these tumors is obscure with many theories of origin advocated with the most commonly accepted being that they originate from the precursor cells of neuroendocrine system. This spectrum of condition forms the most common nonepidermoid carcinomas of the larynx.² The most important risk factor associated is smoking. Here, we report a case of laryngeal neuroendocrine carcinoma that was managed with total laryngectomy.

CASE REPORT

A 50-year-old male presented to the emergency department with progressive difficulty in swallowing and

change in voice since 3 months. He also complained of difficulty in breathing since the last 15 days, which had progressed to a frank stridor for which he was referred to the ENT department where he underwent an emergency tracheostomy. On general examination, he was conscious with pulse rate of 84 beats/minute and respiratory rate of 18/minute, and chest examination revealed conducted sounds over the chest. Indirect laryngoscopy showed an ulceroproliferative growth involving the left aryepiglottic (AE) fold and piriform sinus and extending to the midline causing edema in the left false vocal cord causing reduced glottis chink. On hematological investigation, he had hemoglobin of 105 gm/L with ESR of 55/hour. His liver function, kidney function, and other biochemical parameters were within the normal limits. Contrast-enhanced computer tomography (CECT) of neck showed soft tissue lesion with smooth outlines in left piriform fossa with involvement of left AE fold. The mass showed heterogeneous attenuation with no evidence of calcification or cavitation (Figs 1A and B). A CECT scan of chest, abdomen, and brain was done to know the staging and to rule out metastasis. The tumor was found to be limited to the laryngeal framework with no distant metastasis. The TNM staging of the tumor was deemed to be T₃N₀M₀. He underwent a direct laryngoscopic biopsy under general anesthesia, which revealed features of NET. However, further grading of the tumor could not be done on the biopsy specimen. Thereafter, the patient was worked up and counseled for a total laryngectomy. The surgery was performed and no intraoperative complications were noted. The immediate postoperative period was uneventful.

Upon final histopathologic examination, there was an ulceroproliferative lesion involving the left AE fold and piriform sinus measuring 2 × 2 × 1.5 cm, which stained intensely with epithelial membrane antigen, neuron-specific enolase (NSE), and chromogranin (Fig. 2). Thus, a diagnosis of atypical carcinoid tumor was made.

The patient, however, expired due to sudden cardiac arrest 10 days postoperatively, so radiotherapy and follow-up could not be done.

DISCUSSION

Neuroendocrine tumors of the larynx are the most common nonepidermoid tumors of the larynx and comprise less than 1% of the laryngeal tumors.² The male to female ratio is 3:1, and the most common risk factor associated with this condition is smoking.³

¹Senior Resident, ^{2,4}Professor, ³Associate Professor

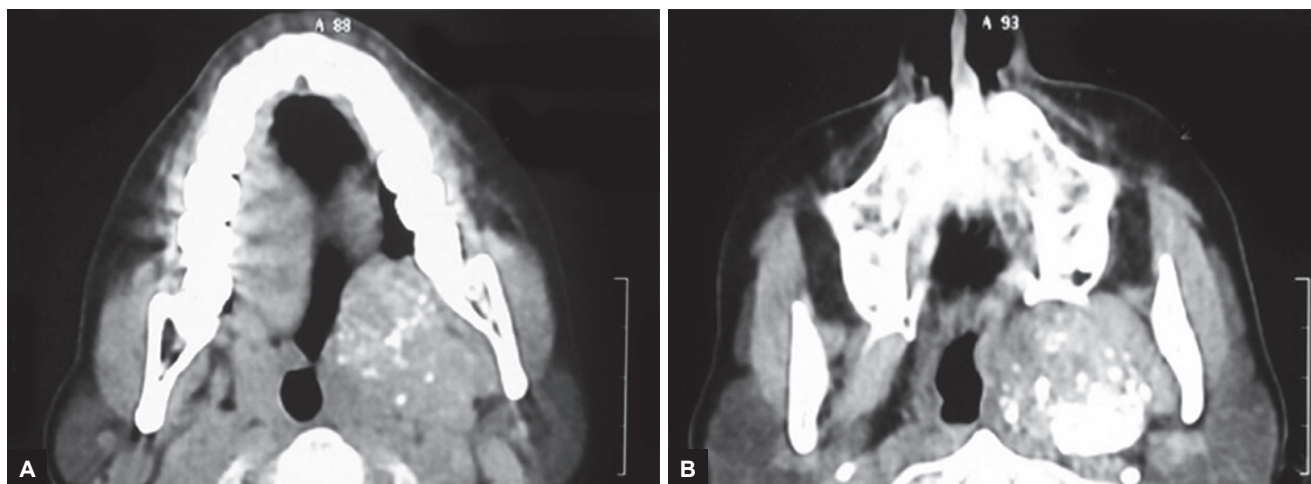
¹Department of ENT, Lok Nayak Jai Prakash Narayan Hospital New Delhi, India

²Department of ENT, Maulana Azad Medical College, New Delhi, India

³Department of Medicine, Maulana Azad Medical College, New Delhi, India

⁴Department of Pathology, Maulana Azad Medical College New Delhi, India

Corresponding Author: Varun Rai, Senior Resident, Department of ENT, Lok Nayak Jai Prakash Narayan Hospital, New Delhi India, Phone: +1128745642, e-mail: varun_rai@me.com



Figs 1A and B: The CECT scan of neck (axial and coronal views) shows soft tissue density mass with smooth outlines in left pyriform fossa with involvement of left AE fold. The mass shows heterogeneous attenuation with no evidence of any calcification

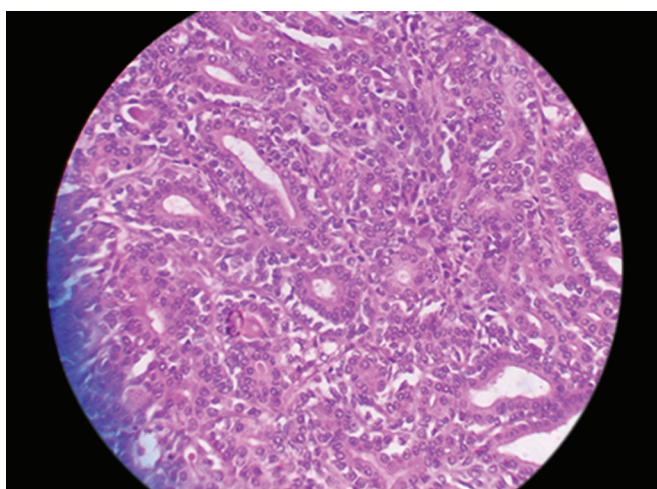


Fig. 2: Ulceration of the lining mucosa. Tumor cells showing a prominent nesting pattern with thin fibrovascular septae. Cells are polygonal with eosinophilic granular cytoplasm immunoreactive for synaptophysin and NSE (hematoxylin and eosin $\times 40$)

The spectrum of NETs can only be differentiated from one another histopathologically and they constitute paragangliomas, atypical carcinoids, small and large cell neuroendocrine carcinoma. The most frequent site involved is the supraglottis. Atypical carcinoid tumor is the most commonly reported variant in the literature, with the typical carcinoid being the rarest.⁴ Most of the symptoms and presentation mimic a usual laryngeal malignancy and they can be distinguished only upon histopathologic examination. Features suggestive of NETs are neurosecretory granules, cells with variable degrees of pleomorphism and organization into nests, cords and trabeculae with submucosal origin of the neoplasm, evidence of mucin (Periodic acid-Schiff+) and immunohistochemical positivity for neuroendocrine markers, such as chromogranin, NSE, synaptophysin, and neurofilaments.⁵ Positive staining for calcitonin

in neuroendocrine carcinoma is usually the norm; however, in our case, this was not so.⁶ Negative staining is suggestive for paragangliomas; however, in our case, the other histopathological features suggested atypical carcinoid tumor.

Other nonspecific markers for paragangliomas like urinary levels of catecholamines could also be done to confirm the diagnosis. Urinary levels of catecholamines and some metabolites (vanillylmandelic and homovanillic acid) are often raised in paraganglioma, whereas increased levels of 5-HIAA, NSE, and CgA can be diagnostic for carcinoids.⁷ The most frequent sites of metastasis are lymph nodes, skin, liver, and lung.⁸

The therapeutic approaches to NETs of the larynx vary according to the biological behavior of the various histological types and disease stage. Conservative surgery is the standard treatment for local typical carcinoid and paraganglioma but locoregional lymph node dissection is not indicated because metastatic lymph node involvement is rare⁹ and the long-term prognosis is good. In NETs and atypical carcinoids, depending upon the extent of disease, total or subtotal laryngectomy with lymph node dissection is the most appropriate treatment for carcinoma. The overall 5-year survival rate is 48%.¹⁰ The role of radiotherapy and/or chemotherapy is still doubtful, as these tumors are usually resistant.

We would like to highlight this case as laryngeal NETs form a relatively rare entity when compared with the commoner epidermal origin tumors. Our case was also unique in the sense that even though all histopathologic features pointed toward atypical carcinoid tumor, calcitonin negativity usually indicates paragangliomas. Thus, in cases of atypical presentations, optimal management of this subgroup of tumors can be difficult.

REFERENCES

1. Goldman NC, Hood CI, Singleton GP. Carcinoid of the larynx. *Arch Otolaryngol* 1969 Aug;90(1):64-67.
2. Soga J, Osaka M, Yakuwa Y. Laryngeal endocrinomas (carcinoids and relevant neoplasms): analysis of 278 reported cases. *J Exp Clin Cancer Res* 2002 Mar;21(1):5-13.
3. Kasantikul V, Keelawat S, Maneesri S, Panichabhongse V. Moderately differentiated neuroendocrine carcinoma (atypical carcinoid) of the larynx. *J Med Assoc Thai* 1997 Jun;80(6):396-401.
4. Ferlito A, Barnes L, Rinaldo A, Gnepp DR, Milroy CM. A review of neuroendocrine neoplasms of the larynx: update on diagnosis and treatment. *J Laryngol Otol* 1998 Sep;112(9):827-834.
5. Ferlito A, Friedmann I. Review of neuroendocrine carcinomas of the larynx. *Ann Otol Rhinol Laryngol* 1989 Oct;98(10):780-790.
6. Wenig BM, Hyams VJ, Heffner DK. Moderately differentiated neuroendocrine carcinoma of the larynx. A clinicopathologic study of 54 cases. *Cancer* 1988 Dec;62(12):2658-2676.
7. Govaerts PJ, van den Broek P, Corstens FH, Peters HM. Clinical oncology: case presentations from oncology centres – 2. Carcinoid of the larynx. *Eur J Cancer* 1992 Mar;28A(10):1755-1758.
8. Procopio G, Ricotta R, Fusi A, Celio L, De Dosso S, Catena L, Ferrari L, Quattrone P, Verzoni E, Bajetta E. Neuroendocrine tumours of the larynx: a clinical report and literature review. *Tumori* 2006 Jan;92(1):72-75.
9. Ferlito A, Shaha AR, Rinaldo A. Neuroendocrine neoplasms of the larynx: diagnosis, treatment and prognosis. *ORL J Otorhinolaryngol Relat Spec* 2002 Mar-Apr;64(2):108-113.
10. Mills SE. Neuroectodermal neoplasms of the head and neck with emphasis on neuroendocrine carcinomas. *Mod Pathol* 2002 Mar;15(3):264-278.