

RESEARCH ARTICLE

Effectiveness of Oral Antihistamines and Intranasal Steroid Spray in relieving Ocular Symptoms in Allergic Rhinitis using Total Ocular Symptom Score

¹Namit K Singh, ²Prakash S Nagpure, ³Manish K Yadav, ⁴Shushil Chavan, ⁵Shraddha Manpe, ⁶Ravi Ganeshkar

ABSTRACT

Ocular symptoms in allergic rhinitis are often overlooked, but they have a significant impact on the quality of life of an individual.

Materials and methods: A randomized controlled trial was conducted from August 2012 to July 2013; a total of 153 cases were considered and divided into two groups. Group A received levocetirizine, and group B received mometasone furoate nasal spray.

Aims and objectives: The aims and objectives of this study were to determine the total ocular symptom score (TOSS) according to the severity of allergic rhinitis, determine the TOSS before medication, and determine the effectiveness of antihistamines (levocetirizine) and intranasal corticosteroid spray (mometasone furoate).

Results: The results indicate average TOSS to be in intermittent mild (51.32), intermittent moderate to severe (55.86), persistent mild (44.50), and persistent moderate to severe (52.02). Chi-square test to compare the relief between groups A and B did not show any statistical significance after 1st ($p=0.8951$) and 4th weeks ($p=0.9758$) of follow-up.

Keywords: Allergic rhinitis, Levocetirizine, Mometasone furoate, Ocular symptoms, Total ocular symptom score.

How to cite this article: Singh NK, Nagpure PS, Yadav MK, Chavan S, Manpe S, Ganeshkar R. Effectiveness of Oral Antihistamines and Intranasal Steroid Spray in relieving Ocular Symptoms in Allergic Rhinitis using Total Ocular Symptom Score. *Int J Otorhinolaryngol Clin* 2016;8(2):45-50.

Source of support: Nil

Conflict of interest: None

INTRODUCTION

Allergic rhinitis is defined as an inflammation of the nasal membranes¹ and is characterized by a symptom complex

of sneezing, nasal congestion, nasal itching, and rhinorrhea.² Because of the continuity of the mucosal lining of the nose with the paranasal sinus and its communication with the ears through the Eustachian tube and with the eyes through nasolacrimal duct, these structures also gets involved to some extent.

Allergic rhinitis was defined by the American Association of Otolaryngology and Head and Neck Surgery as an inflammatory, immunoglobulin E (IgE)-mediated disease characterized by nasal congestion, rhinorrhea (nasal drainage), sneezing, and/or nasal itching, and these are associated with the ocular symptoms of tearing (epiphora), itching (pruritus), and redness (erythema), which are the major factors in reducing the quality of life of patients with allergic rhinitis.

According to the French INSTANT study, 31.7% of the population-based sample suffered from allergic rhinitis and 52.0% of the allergic rhinitis subjects described ocular symptoms. Men had significantly less ocular symptoms than women. The troublesome ocular symptoms were itching eyes (51.1%), watery eyes (38.6%), red eyes (6.6%), and swollen eyelids (3.6%). The trigger factors were pollens (51.3%), household dust and mites (34.8%), pets (12.2%), and air pollution (3.8%).³ Another study conducted in 509 untreated Swiss subjects with seasonal allergic rhinitis found that 93% of the subjects had conjunctivitis, and the subjects described the ocular symptoms as one of the most severe and unpleasant manifestations of the disease.⁴ The above findings were also supported by the US survey in which ocular symptoms were labeled as the most bothersome characteristic of allergic rhinitis second only to nasal congestion.⁵

The effect on quality of life of patients was summarized by Pitt et al⁶ in 2004 where they opined that ocular allergy can have a significant impact on activities of daily living, mental health, and social functioning, which was supported by the French INSTANT study, which concluded that ocular symptoms had a negative impact on daily activities, with the implication that the patient suffers from blurred sight, reduction in daily activities and efficacy at work, sleep disturbances, and sick leave.³

Pathophysiology of Ocular Symptoms

The proposed mechanisms responsible for the ocular symptoms in patients with allergic rhinitis are as follows:

¹Associate Professor, ²Professor and Head, ³Senior Resident
⁴⁻⁶Postgraduate Resident

¹Department of ENT and Head and Neck Surgery, Maharishi Markandeshwar Institute of Medical Sciences and Research Ambala, Haryana, India

²⁻⁶Department of ENT, Mahatma Gandhi Institute of Medical Sciences, Wardha, Maharashtra, India

Corresponding Author: Namit K Singh, Associate Professor Department of ENT and Head and Neck Surgery, Maharishi Markandeshwar Institute of Medical Sciences and Research Ambala, Haryana, India, Phone: +918888527927, e-mail: drnamit@rediffmail.com

First, it may be due to the direct effects of allergen deposition on the conjunctiva and second, because of nasal ocular reflexes.

Direct effects of the allergens are supported by the fact that ocular allergen challenge causes symptoms of watering and itching in eyes, which is associated with the release of inflammatory mediators, including histamine, in ocular secretions.^{7,8}

Considering the nasal ocular reflexes, Hom and Bielory⁹ suggested that there are numerous anatomic connections between the eyes and nose. Detailed examination of the innervation, circulation, lymphatic, and neurogenic systems revealed that the eye is richly supplied by parasympathetic nerves that govern the formation of the tear films that enter the eyes after traveling in combination with the parasympathetic fibers to the nasal cavity and that are responsible for the nasal secretions. They suggested that these fibers can intersect at the pterygopalatine ganglion. They also suggested that the neurogenic inflammation affects both the eyes and the nose as evidenced by the presence of the same neurogenic factors. These facts are supported by studies conducted by Lebel et al¹⁰ who reported that 20% of allergic rhinitis sufferers experienced ocular symptoms during nasal provocation with grass pollen and concluded that allergic ocular symptoms can occur without direct exposure of the conjunctiva to allergen. Other studies conducted by Zilstorff-Pedersen¹¹ and Philip et al¹² also supported the presence of nasal ocular reflex.

Baroody and Naclerio¹³ opined that allergen depositing on the nasal mucosa can trigger afferent reflexes that propagate centrally and the efferent limbs of these reflexes can give rise to symptoms in the contralateral nasal cavity and also to conjunctivae and maxillary sinuses. They also suggested that nasal allergic reaction leads to the release of mediators from the nose and upregulation of circulating cells, which reaches the eye and releases more mediators and causes more severe symptoms.

MATERIALS AND METHODS

After approval from the Institutional Ethical Committee, a randomized controlled trial was conducted in the Department of Otolaryngology of a tertiary care center from August 2012 to July 2013. A total of 153 cases determined to be having allergic rhinitis on the basis of history and clinical examination with ocular symptoms and on regular follow-up were considered. The cases were randomly divided into two groups: Group A was given 5 mg of levocetirizine as a single dose for the night, and group B was advised to take mometasone furoate nasal spray initially one puff in each nostril twice a day for 7 days followed by one puff in each nostril once a day (preferably in the morning).

The clinical diagnosis of the cases was made on the basis of careful detailed history in which patients were particularly asked about ocular symptoms of itching, redness, watering and swelling, and seasonal variations in symptoms, their habits, and family history. Careful inquiry was also made about different precipitating factors.

Inclusion criteria: Patients with nasal discharge, sneezing, and nasal obstruction and also having any of the following ocular symptoms of itching, redness, watering, and swelling were included in the study.

Exclusion criteria: Children below 2 years of age and pregnant females were not included in the study.

Clinical examinations – after routine local examinations of ear, nose, and throat, a complete systemic examination was carried out. Allergic rhinitis and its Impact on Asthma (ARIA) classification of allergic rhinitis 2010 was used to classify the patients into intermittent or persistent with different grades of severity (mild and moderate to severe).

Total ocular symptom score (TOSS) (Fig. 1) was taken into account in the form of a questionnaire, and the score calculated for each patient at the time of initial visit and at subsequent follow-up as per the directions shown in the figure.

AIMS AND OBJECTIVES

- To determine the TOSS according to the severity of allergic rhinitis.
- To determine the TOSS before medication and at subsequent follow-up in each group.
- To determine the effectiveness of antihistamines (levocetirizine) and intranasal corticosteroid spray (mometasone furoate) in relieving ocular symptoms on the basis of TOSS.

RESULTS

In this study, a total of 153 cases were taken into consideration: 76 cases were included in group A who were prescribed 5 mg HS levocetirizine, and 77 cases were included in group B who were prescribed intranasal mometasone furoate nasal spray initially one puff in each nostril twice a day for 7 days followed by one puff in each nostril once a day (preferably in the morning).

Statistical analysis was done with the help of Open EPI from WHO website to apply the chi-square test.

Gender Predilection

In our study, there was a preponderance of males (n=116). This might have been because of more environmental exposure (Graph 1), and the male-to-female ratio was 3.1:1.

| Have you experienced any of the following during the last week? | All of the Time (4) | Most of the Time (3) | Half of the Time (2) | Some of the Time (1) | None of the Time (0) | N/A |
|---|---------------------|----------------------|----------------------|----------------------|----------------------|-----|
| Itching | | | | | | |
| Redness | | | | | | |
| Tearing (eyes watering) | | | | | | |
| Swelling (puffy eyes) | | | | | | |

•Add up scores

All of the Time = 4

Most of the Time = 3

Half of the Time = 2

Some of the Time = 1

None of the Time = 0

•Divide by maximum score

All 4 questions answered divide by 16

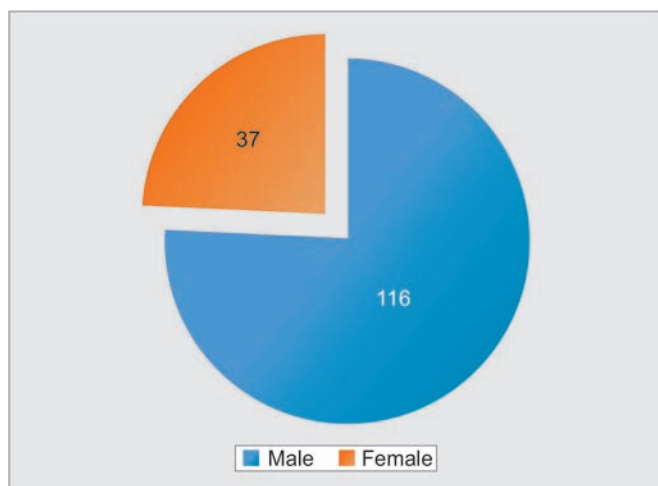
3 questions answered divide by 12

2 questions answered divide by 8

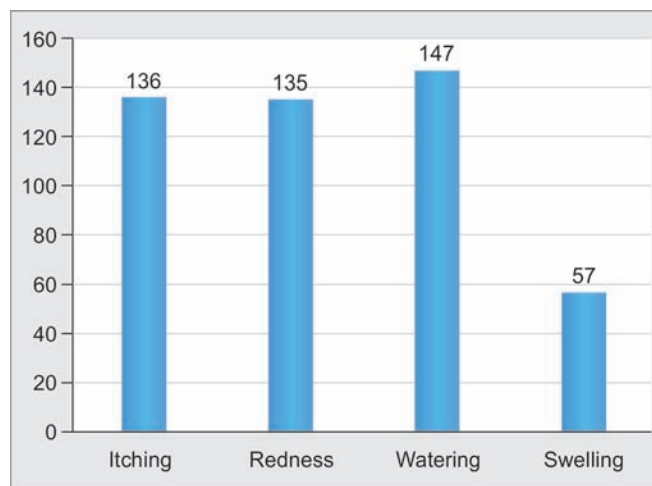
1 question answered divide by 4

•Multiply by 100

Fig. 1: Total ocular symptom score



Graph 1: Distribution according to gender



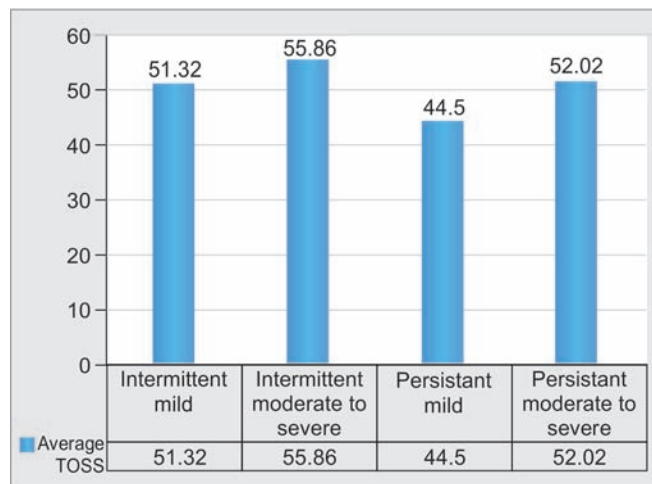
Graph 2: Frequency of ocular symptoms

Frequency of Ocular Symptoms

In our study, watering from the eyes was the most common (n=147) ocular symptom followed by itching (n=136) and redness (n=135). The presentation was in the form of symptom complex with only a few cases presenting with a single symptom (Graph 2).

Average TOSS in Various Types of Allergic Rhinitis

The overall average of TOSS was 50.92; taking into account the above figure, a slightly higher score is associated with intermittent type of allergic rhinitis. This might be because of the desensitization of the mucosa due to repeated or continuous exposure of the allergen in patients with persistent type of allergic rhinitis (Graph 3).



Graph 3: Average TOSS in various types of allergic rhinitis

Variation of TOSS in Group A

Table 1 and Graph 4 demonstrate the effect of treatment prescribed in group A (levocetirizine) on TOSS, which shows a decreasing trend from an initial average TOSS as 50.50 to 25.99 at the end of 4 weeks.

Variation of TOSS in Group B

Table 2 and Graph 5 demonstrate the effect of medication prescribed to group B (mometasone furoate) on TOSS, which depicts a decreasing trend with the initial overall TOSS as 51.52 to 22.09 at the end of 4 weeks.

Difference in TOSS in 1st and 4th Weeks of Follow-up

Tables 3 and 4 depict the decrease in TOSS after 1st and 4th weeks of treatment respectively. On applying the

chi-square test to determine the level of significance, $p=0.8951$ at the end of 1st week and $p=0.9758$ at the end of 4th week. Though the difference was not statistically significant, a slightly higher value of decrease in TOSS is seen in the group treated with mometasone furoate nasal spray as compared with levocetirizine.

DISCUSSION

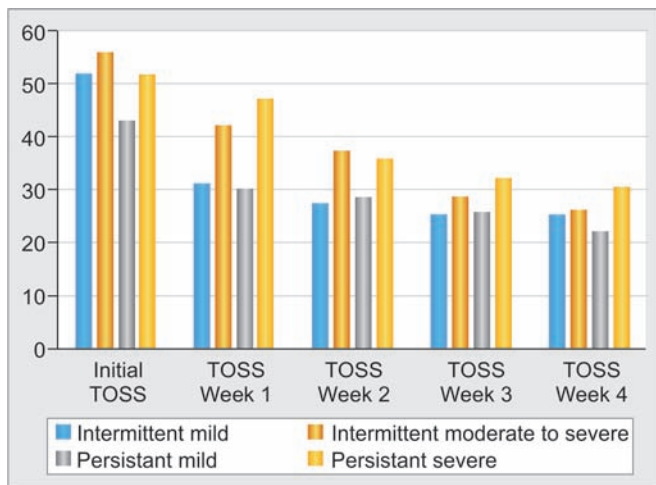
Levocetirizine is an easily available over-the-counter medicine and is the R-isomer of cetirizine dihydrochloride in a once-daily 5 mg formulation. It is the antagonist of histamine H1 receptor that is responsible for the majority of the immediate manifestations of allergic disease. It causes inhibition of eotaxin production by endothelial cells¹⁴ which leads to inhibition of eotaxin-induced eosinophil migration¹⁵ and also inhibits both resting and granulocyte-macrophage colony-stimulating

Table 1: Total ocular symptom score at initial visit and at subsequent weekly follow-up in group A

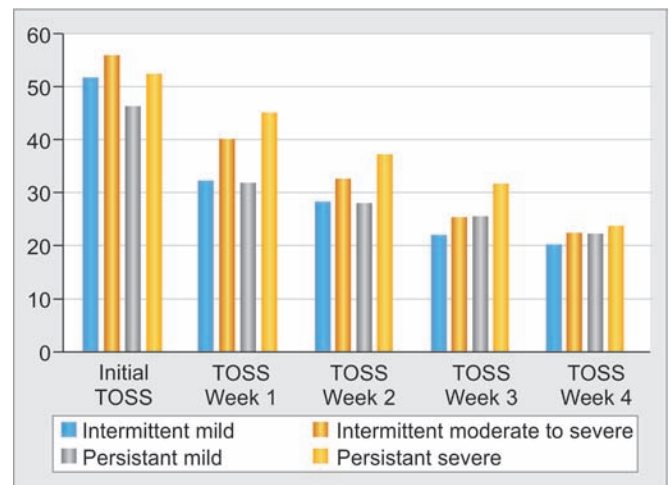
| Group A | Initial TOSS | TOSS Week 1 | TOSS Week 2 | TOSS Week 3 | TOSS Week 4 |
|---------------------------------|--------------|-------------|-------------|-------------|-------------|
| Intermittent mild | 51.8 | 31.26 | 27.32 | 25.17 | 25.17 |
| Intermittent moderate to severe | 55.76 | 42.15 | 37.24 | 28.63 | 26.23 |
| Persistent mild | 42.73 | 30.17 | 28.43 | 25.64 | 22.13 |
| Persistent severe | 51.72 | 47.12 | 35.73 | 32.15 | 30.43 |

Table 2: Total ocular symptom score at initial visit and at subsequent follow-up in group B

| Group B | Initial TOSS | TOSS Week 1 | TOSS Week 2 | TOSS Week 3 | TOSS Week 4 |
|---------------------------------|--------------|-------------|-------------|-------------|-------------|
| Intermittent mild | 51.56 | 32.15 | 28.26 | 22.15 | 20.13 |
| Intermittent moderate to severe | 55.96 | 40.24 | 32.47 | 25.13 | 22.37 |
| Persistent mild | 46.25 | 31.86 | 27.83 | 25.34 | 22.15 |
| Persistent severe | 52.32 | 45.14 | 37.26 | 31.63 | 23.73 |



Graph 4: Graphical representation TOSS at initial visit and at subsequent weekly follow-up in group A



Graph 5: Graphical representation TOSS at initial visit and at subsequent weekly follow-up in group B

Table 3: Difference in TOSS at week 1

| Week 1 | Intermittent mild | Intermittent moderate to severe | Persistent mild | Persistent moderate to severe |
|---------|-------------------|---------------------------------|-----------------|-------------------------------|
| Group A | 20.54 | 13.61 | 12.56 | 4.6 |
| Group B | 19.41 | 15.72 | 14.39 | 7.18 |

$p=0.8951$

Table 4: Difference in TOSS at week 4

| Week 4 | Intermittent mild | Intermittent moderate to severe | Persistent mild | Persistent moderate to severe |
|---------|-------------------|---------------------------------|-----------------|-------------------------------|
| Group A | 26.63 | 29.53 | 20.6 | 21.29 |
| Group B | 31.43 | 33.59 | 24.1 | 28.59 |

$p=0.9758$



factor-stimulated eosinophil adhesion to vascular cell adhesion molecule-1¹⁶

The actions of levocetirizine occur through the inhibition of the release of mediators from mast cells and basophils which involve stimulation of the intracellular activity of the polyphosphatidylinositol pathway, and they also downregulate the nuclear transcription factors that regulate the production of proinflammatory cytokines and adhesion proteins.

With the properties of inhibiting the release of histamine and chemokines, levocetirizine plays a role in cell recruitment and inhibits the vicious cycle of allergic reaction. Hence, levocetirizine relieves the extranasal symptoms of allergic rhinitis.

Mometasone furoate is a potent steroid preparation that is being used as a nasal spray, and at a dose of 50 µg per dose it shows promising effects, it acts at multiple points in the allergic inflammation pathway, and its anti-inflammatory effects mediated through inhibition of proinflammatory cytokines (i.e., interleukin (IL)-1, IL-3, IL-4, and IL-5) decrease the number of inflammatory cells.¹⁷ Studies have shown that IL-4 and IL-5 are T-helper cell type 2 (Th2)-secreted proinflammatory cytokines that regulate mast cell activation and degranulation, eosinophil differentiation, and IgE production; on the contrary, INF-gamma is a Th1-secreted cytokine that downregulates the effects of the Th2 cytokines. Mometasone furoate acts by reversing the exaggerated Th2 response that contributes to the pathophysiology of allergic disease.¹⁸ In other studies, Hochhaus¹⁷ observed that patients using mometasone furoate showed a reduction in eosinophils and basophils from baseline after 6 hours (late phase), and it also enhances apoptosis of eosinophils.¹⁹ Studies have shown that mometasone furoate inhibits activation of cell molecule system and prevents infiltration of inflammatory cells in the nasal mucosa, and in this way, it protects against cell injury.²⁰

Hence, by decreasing nasal inflammation, mometasone furoate prevents the excess stimulation of reflex neural activity occurring during allergic reactions, which lead to reduction in the ocular symptoms; it also inhibits local nasal inflammation that helps to reduce the recruitment of inflammatory cells to the eyes, which is observed as a late response to ocular challenge with antigen.

CONCLUSION

Through this study, we conclude that there is no statistically significant difference between the two modalities of treatment, but the side effects commonly seen with levocetirizine are headache, muscle aches, sleepiness or unusual drowsiness, stuffy or runny nose, congestion, and dryness or soreness of the throat, which leads to

its unacceptability if prescribed for a longer duration, whereas mometasone furoate is associated with bitter taste, headache, stuffy or runny nose, and cough with hoarseness, but these symptoms wear off with regular use of medication that leads to better acceptability by the patients, and the mucosal changes, it brings about help in symptom relief for a longer duration; hence, mometasone furoate is subjectively better in the management of ocular symptoms.

ACKNOWLEDGMENTS

I would like to acknowledge the efforts of all the faculty members and residents of the Department of ENT of MGIMS, Sevagram for their effort and support in the conductance of this study and above all the unconditional and motivational support of my wife Dr. Naina Kumar in preparation of this manuscript.

REFERENCES

1. Togias AG. Systemic immunologic and inflammatory aspects of allergic rhinitis. *J Allergy Clin Immunol* 2000 Nov;106 (Suppl 5):S247-S250.
2. Druce HM. Allergic and nonallergic rhinitis. In: Middleton EM Jr, Reed CE, Ellis EF, Adkinson NF Jr, Yunginger JW, Busse WW, editors. *Allergy: principles and practice*. 5th ed. St. Louis (MO): Mosby Year-Book; 1998. p. 1005-1016.
3. Klossek JM, Annesi-Maesano I, Pribil C, Didier A. The burden associated with ocular symptoms in allergic rhinitis. *Int Arch Allergy Immunol* 2012;158(4):411-417.
4. Wüthrich B, Brignoli R, Canevascini M, Gerber M. Epidemiological survey in hay fever patients: symptom prevalence and severity and influence on patient management. *Schweiz Med Wochenschr* 1998 Jan 31;128(5):139-143.
5. Allergies in America. A landmark survey of nasal allergy sufferers: executive summary.
6. Pitt AD, Smith AF, Lindsell L, Voon LW, Rose PW, Bron AJ. Economic and quality-of-life impact of seasonal allergic conjunctivitis in Oxfordshire. *Ophthalmic Epidemiol* 2004 Feb;11(1):17-33.
7. Bielory L. Update on ocular allergy treatment. *Expert Opin Pharmacother* 2002 May;3(5):541-553.
8. McGill JI, Holgate ST, Church MK, Anderson DF, Bacon A. Allergic eye disease mechanisms. *Br J Ophthalmol* 1998 Oct;82(10):1203-1214.
9. Hom MM, Bielory L. The anatomical and functional relationship between allergic conjunctivitis and allergic rhinitis. *Allergy Rhinol* 2013 Fall;4(3):e110-e119.
10. Lebel B, Bousquet J, Morel A, Chanal I, Godard P, Michel FB. Correlation between symptoms and the threshold for release of mediators in nasal secretions during nasal challenge with grass-pollen grains. *J Allergy Clin Immunol* 1988 Nov;82 (5 Pt 1):869-877.
11. Zilstorff-Pedersen K. Quantitative measurements of the nasolacrimal reflex. *Arch Otolaryngol Head Neck Surg* 1965 May;81(5):457-462.
12. Philip G, Baroody FM, Proud D, Naclerio RM, Togias AG. The human nasal response to capsaicin. *J Allergy Clin Immunol* 1994 Dec;94(6 Pt 1):1035-1045.

13. Barody FM, Naclerio RM. Nasal-ocular reflexes and their role in the management of allergic rhinoconjunctivitis with intranasal steroids. *World Allergy Organ J* 2011 Jan;4(Suppl 1):S1-S5.
14. Menzies-Gow A, Ying S, Phipps S, Kay AB. Interactions between eotaxin, histamine and mast cells in early microvascular events associated with eosinophil recruitment to the site of allergic skin reactions in humans. *Clin Exp Allergy* 2004 Aug;34(8):1276-1282.
15. Thomson L, Blaylock MG, Sexton DW, Campbell A, Walsh GM. Cetirizine and levocetirizine inhibit eotaxin-induced eosinophil transendothelial migration through human dermal or lung microvascular endothelial cells. *Clin Exp Allergy* 2002 Aug;32(8):1187-1192.
16. Wu P, Mitchell S, Walsh GM. A new antihistamine levocetirizine inhibits eosinophil adhesion to vascular cell adhesion molecule-1 under flow conditions. *Clin Exp Allergy* 2005 Aug;35(8):1073-1079.
17. Hochhaus G. Pharmacokinetic/pharmacodynamic profile of mometasone furoate nasal spray: potential effects on clinical safety and efficacy. *Clin Ther* 2008 Jan;30(1):1-13.
18. Umland SP, Nahrebne DK, Razac S, Beavis A, Pennline KJ, Egan RW, Billah MM. The inhibitory effects of topically active glucocorticoids on IL-4, IL-5, and interferon-gamma production by cultured primary CD4+ T cells. *J Allergy Clin Immunol* 1997 Oct;100(4):511-519.
19. Zhang X, Moilanen E, Adcock IM, Lindsay MA, Kankaanranta H. Divergent effect of mometasone on human eosinophil and neutrophil apoptosis. *Life Sci* 2002 Aug;71(13):1523-1534.
20. Calderón E, Lockey RF. A possible role for adhesion in asthma. *J Allergy Clin Immunol* 1992 Nov;90(5):852-865.