

CASE REPORT

Lymphangiomatous Polyp of the Tonsil: An Unusual Cause of Snoring

¹Shubha P Bhat, ²Shrinath D Kamath P, ³Natasha Hilda Rent, ⁴Kishore Chandra Shetty

ABSTRACT

Benign vascular tumors and hamartomatous malformations of the palatine tonsils are less common than malignancies and are infrequently encountered. Lymphangiomatous polyp (LAP) is a rare hamartomatous lesion, arising from the surface of tonsil in children and young adults. They usually present with sore throat and dysphagia. Tonsillectomy with excision of polyp is the curative treatment. Histopathological examination will aid in the final diagnosis. We report a case of an adult male with LAP of left tonsil, who presented with snoring, sore throat, and change of voice.

Keywords: Hamartoma, Polyp, Tonsil, Tonsillectomy.

How to cite this article: Bhat SP, P Kamath SD, Rent NH, Shetty KC. Lymphangiomatous Polyp of the Tonsil: An Unusual Cause of Snoring. *Int J Otorhinolaryngol Clin* 2015;7(2):88-90.

Source of support: Nil

Conflict of interest: None

INTRODUCTION

Lymphangiomas are benign tumors of the lymphatic vessels. More than 90% of lymphangiomas occur in skin and subcutaneous tissue of head and neck region, followed by larynx, parotid, mouth and tongue.^{1,2} Lymphangiomatous polyps (LAP) are hamartomas, which occur more commonly in lower gastrointestinal tract. Tonsil is a common site for LAP in the head and neck region. About 30 cases of tonsillar LAP have been reported in the literature till date.^{3,4} Incidence of this condition ranges from 1.9 to 8% of all benign tonsillar tumors.⁵ Lymphangiomatous polyp usually occurs in the first two decades of life, with a male preponderance.⁶ Patients usually present with history of sore throat, dysphagia, dyspnea and even sensation of mass, when

it attains larger size.⁴ They are commonly unilateral and have a pedicle attached to the surface of tonsil.^{3,7} Treatment includes simple surgical excision of the polyp and the tonsil.⁶ We report a case of a lymphangiomatous polyp of left tonsil in an adult male who presented with sore throat since 6 years and recent history of snoring and change of voice.

CASE REPORT

A 40-year-old male presented with history of throat pain since 6 years. His throat pain was recurrent and was sometimes associated with fever, cough and odynophagia. Recently, he also developed change in voice and snoring. Examination of the throat revealed bilateral enlarged tonsils and congested anterior pillars. A pedunculated polypoidal mass measuring about 3 × 2 cm was seen arising from the upper pole of left tonsil (Fig. 1). It had smooth surface. Bilateral jugulodigastric lymph nodes were palpable and were firm and nontender. Nasal and laryngeal examination did not show any abnormality. Tonsillectomy was performed under general anesthesia by dissection method. The blood loss during the procedure was about 20 ml which is almost same as most of the tonsillectomies by dissection method. The tissue was sent for histopathological examination in labeled containers. Postoperative period was uneventful.

Grossly, both the tonsils were enlarged and measured 4.5 × 4 cm. Cut surface showed lobulated contour. A pedunculated polypoidal mass measuring 3 × 2 cm was seen arising from the surface of left tonsil. Outer surface of the polyp was smooth, firm and yellowish white. Cut surface showed homogenous, solid, yellowish white areas (Fig. 2). Histology of both tonsils showed lymphoid hyperplasia with evidence of bacterial colony suggesting chronic tonsillitis. Polyp was lined by stratified squamous epithelium; subepithelium showed dilated lymphatic channels containing lymph and lymphocytes in the lumen, embedded in loose fibrocollagenous stroma (Fig. 3). Lymphoid aggregates with well formed germinal centers and adipose tissue was also seen (Fig. 4). Features were suggestive of lymphangiomatous polyp of palatine tonsil.

Patient is under regular follow-up and is symptom free.

^{1,3}Assistant Professor, ²Associate Professor, ⁴Professor

¹Department of Pathology, KS Hegde Medical Academy Mangaluru, Karnataka, India

²⁻⁴Department of ENT, KS Hegde Medical Academy, Mangaluru Karnataka, India

Corresponding Author: Shrinath D Kamath P, Associate Professor, Department of ENT, KS Hegde Medical Academy Mangaluru, Karnataka, India, Phone: 919980162161, e-mail: drshrinath.kamath@gmail.com



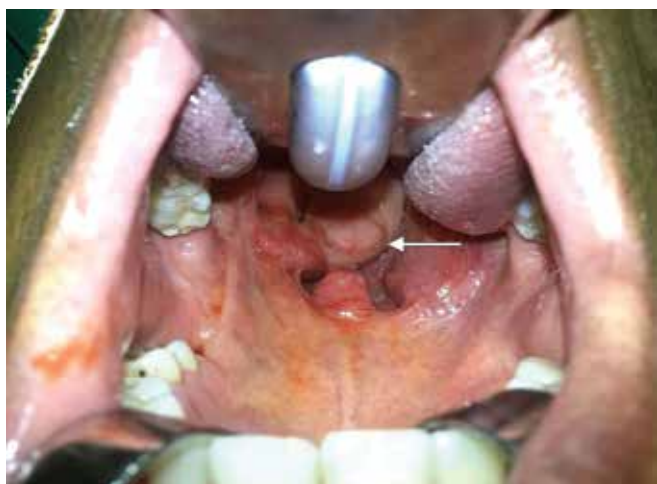

Fig. 1: Clinical photograph showing pedunculated polyp on left tonsil

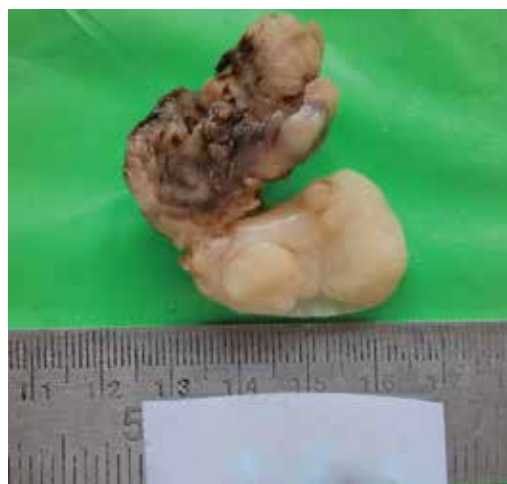

Fig. 2: Gross specimen of left tonsil with pedunculated polyp

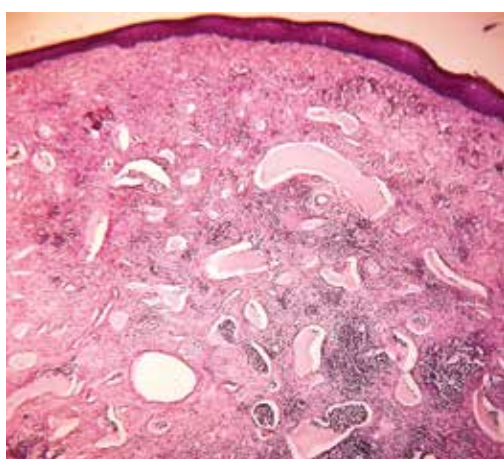


Fig. 3: Polyp lined by stratified squamous epithelium, subepithelium showing numerous dilated lymphatic channels and lymphoid aggregates in fibrocollagenous tissue 10× H and E

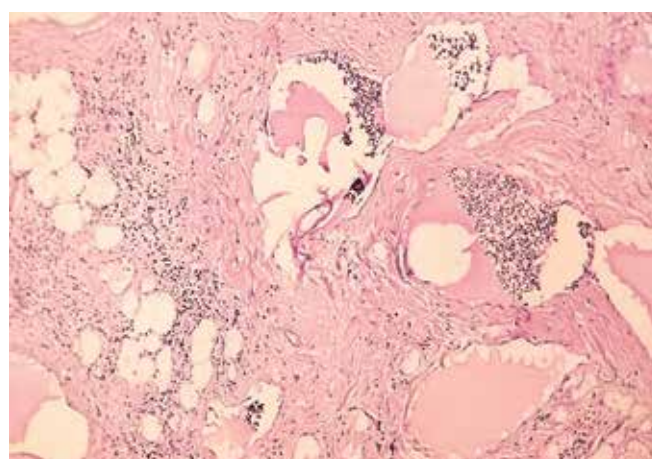


Fig. 4: Lymphatic vessels containing lymph and lymphocytes in fibrocollagenous and adipose tissue stroma 40× H and E

DISCUSSION

Tonsillar lymphangiomatous polyps are reportedly rare hamartomatous lesions. They have been presented with different nomenclature in the past, such as lymphangiectatic fibrous polyp, polypoidal lymphangioma of the tonsil, hamartomatous tonsillar polyp. Hence, the true incidence of this condition is uncertain.^{4,7} Although they are congenital vascular malformations, they usually present in the first two decades of life, average age being 25 years.^{3,6}

Exact etiology of LAP is not clearly understood. A few theories have been proposed to explain the pathogenesis of tonsillar lymphangiomatous polyp:

- Failure of primordial lymphatic sacs to drain into the veins, causing dilation of isolated lymphatic channels.
- Abnormal sequestration of lymphatic tissue, which may explain more peripheral lesions such as capillary and cavernous lymphangiomas.
- Abnormal budding of the lymphatics, which eventually canalize to form lymph filled cysts.^{6,8}

- Chronic inflammation causing obstruction of lymphatic channel.³

The common presenting symptoms are sore throat and dysphagia. Sometimes they can be asymptomatic and detected accidentally. When they attain huge size, they can cause rhinolalia clausa, respiratory difficulty, stridor, excessive saliva in the oral cavity and nausea.⁶ Our patient was 40 years old male, who presented with recurrent sore throat since 6 years and recent history of snoring and change of voice. His oral examination showed bilateral tonsillar hypertrophy with congested anterior pillar and he also had palpable bilateral jugulodigastric nodes. This suggests chronic tonsillitis and associated obstruction was the possible mechanism causing lymphangiomatous polyp in our case.

History of slow growing polypoidal mass of long duration with typical symptoms clinches the diagnosis of a benign lesion. Differential diagnosis includes other benign lesions, such as squamous papilloma, angiomas, fibromas, fibroepithelial polyp, myxomas, lipomas and

chondromas.⁶ Simple surgical excision of polyp with the tonsil is the curative treatment.^{3,6,7} Our patient underwent bilateral tonsillectomy as he had recurrent history of chronic tonsillitis; the polyp was excised along with the tonsil.

Histopathological examination is mandatory for definite diagnosis. Lymphangiomas are different from lymphangiomas by the fact that dilated lymphatic channels are less prominent and stromal component is abundant in LAPs than lymphangiomas. Hence like most authors, we also consider LAPs are hamartomatous proliferations as there is haphazard proliferation of elements that are normally present in the tonsil.^{1-3,5,7} Three components of lymphangiomas include: dilated lymphatic channels, fibrous, and/or adipose stroma and lymphoid tissue.¹

CONCLUSION

Lymphangiomas of tonsils are hamartomatous lesions. Although they are commonly seen in children and young adults, patients can present in the middle age also. Sore throat and dysphagia are the common symptoms associated with this disease; snoring and change of voice are rare symptoms due to the mass effect. Chronic tonsillitis and associated obstruction of lymphatics could

be one of the possible etiologies triggering the formation of hamartomatous polyp. In such cases, tonsillectomy with excision of the polyp is curative. Histopathological examination is mandatory to establish the final diagnosis.

REFERENCES

1. Kardon DE, Wenig BM, Heffner DK, Thompson LD. Tonsillar lymphangiomas: a clinicopathologic series of 26 Cases. *Mod Pathol* 2000;13(10):1128-1133.
2. Ahmed MW, Aldhawi ZM, Almaghrahi LH. Tonsillar lymphangioma. *Pakistan J Otolaryngol* 2011;27(1):18-19.
3. Park E, Pransky SM, Malicki DM, Hong P. Unilateral lymphangioma of the palatine tonsil in a very young child: a clinicopathologic case report. *Case Reports Pediatr* 2011;1-3. Article ID 451542.
4. Cengiz BP, Acar M, Giritli E. A pedunculated lymphangioma of the palatine tonsil: a case report. *Braz J Otorhinolaryngol* 2013;79(3):402.
5. Ryu HS, Jung SY, Koh J, Lee S. Tonsillar lymphangioma polyp-report of two cases. *Korean J Pathol* 2006;40(5):381-384.
6. Balatsouras DG, Fassolis A, Koukoutsis G, Ganelis P, Kaberos A. Primary lymphangioma of the tonsil: a case report. *Case Reports in Med* 2011;1-3. Article ID 183182.
7. Khilnani A, Rekha T, Talsania JR. Lymphangioma tonsillar polyp. *National J Otorhinolaryngol Head Neck Surg* 2013;1(10):2:31-32.
8. Raha O, Singh V, Purkayastha P. Lymphangioma tonsil: rare case study. *Ind J Otolaryngol Head Neck Surg* 2005;57(4): 332-334.

