

## CASE REPORT

# Venous Ectasia: A Potential Mimicker for Laryngocele Radiology Covers the Road

<sup>1</sup>Gaurav Ashish, <sup>2</sup>Mary Kurien

## ABSTRACT

**Introduction:** Venous ectasia is rare causes of neck mass. Among neck veins, ectasia of the internal jugular vein (IJV) are extremely uncommon. However, this is to be kept in mind when considering differentials for laryngocele.

**Objectives:** To recognize the similarities between laryngocele and ectasias of the IJV and the differences in their presentation and management.

**Study design:** Observational.

**Setting:** Tertiary care hospital, India.

**Conclusion:** Presenting a 7-year-old boy with a left-sided soft, non-tender neck mass that fluctuated in size with coughing and straining for the past 1 year, presentation classical of laryngocele. Computed tomography (CT) demonstrated marked asymmetrical dilatation of the left IJV in the neck. Color-flow Doppler ultrasonography revealed a solitary cystic lesion with evidence of high venous blood flow in the IJV area. The relevance of radiological evaluation in neck swelling is being highlighted.

**Keywords:** Color flow Doppler ultrasound, Computed tomography, Ectasia, Internal jugular vein, Laryngocele.

**How to cite this article:** Ashish G, Kurien M. Venous Ectasia: A Potential Mimicker for Laryngocele Radiology Covers the Road. *Int J Otorhinolaryngol Clin* 2015;7(2):64-67.

**Source of support:** Nil

**Conflict of interest:** None

## INTRODUCTION

Venous ectasia, phlebectasia, or varix are synonymous terms for venous dilations that may present as a pediatric neck mass.<sup>1</sup> They are rarely reported in the literature and the true incidence is unknown. Jugular vein ectasia, which is innocuous, has been mistaken for laryngocele, cystic hygroma, as well as other vascular

lesions. However, the management of jugular vein ectasia, which is thought to be due to incompetence of the bicuspid jugular venous valve, is chiefly conservative.<sup>2</sup> We report the case of a 7-year-old boy who presented with a soft, nontender mass in the left-side of the neck that appeared on clinical evaluation to be a laryngocele but on radiological evaluation proved to be a venous ectasia. We present this case in view of developing insight for importance of radiological investigations in such cases.

## CASE REPORT

A 7-year-old boy presented with a soft, non pulsatile enlarging left neck mass for the past 9 months which increased in size during straining and coughing. He denied any pain or tenderness over the site. There was no history of prior illness or injury at the site. He had no other contributory medical history. His physical examination was normal except for a soft, compressible mass lateral to the sternocleidomastoid which became more prominent on performing a valsalva maneuver. There was no palpable thrill, and no bruit was appreciated on auscultation. Examination of his ear, nose and throat was normal.

A plain radiograph of the neck in lateral view was taken with the patient performing a valsalva manoeuvre which failed to show neither an air-filled sac nor any soft tissue mass that could be attributed for the swelling on straining. Routine evaluation of blood counts and chest X-ray were normal. An ultrasound scan of the neck at this stage showed a thin walled, compressible, cystic lesion of approximately 6 × 4 × 3 cm in the left side of the neck, which was confirmed upon Doppler study as ectasia of the lower third of the left internal jugular vein (IJV). The swelling was more obvious on valsalva manoeuvre (Figs 1 and 2). A computed tomography (CT) scan of the neck and thorax with contrast showed asymmetry of the two IJV, more prominent with valsalva manoeuvre (left IJV enlarged 3 times when compared to right-side; Fig. 3).

Treatment options and outcome including surgical ligation with excision of ectatic segment and conservative management with periodic follow-up was explained to patients relative. However, patients relative chose to go ahead with conservative management and periodic follow-up.

<sup>1</sup>Postgraduate Registrar, <sup>2</sup>Professor

<sup>1</sup>Department of ENT and Head and Neck Surgery, Christian Medical College, Vellore, Tamil Nadu, India

<sup>2</sup>Department of ENT, Christian Medical College, Vellore, Tamil Nadu, India

**Corresponding Author:** Gaurav Ashish, Postgraduate, Registrar Department of ENT and Head and Neck Surgery, Christian Medical College, Vellore, Tamil Nadu, India, Phone: 9629329361 e-mail: gauravashish05@gmail.com



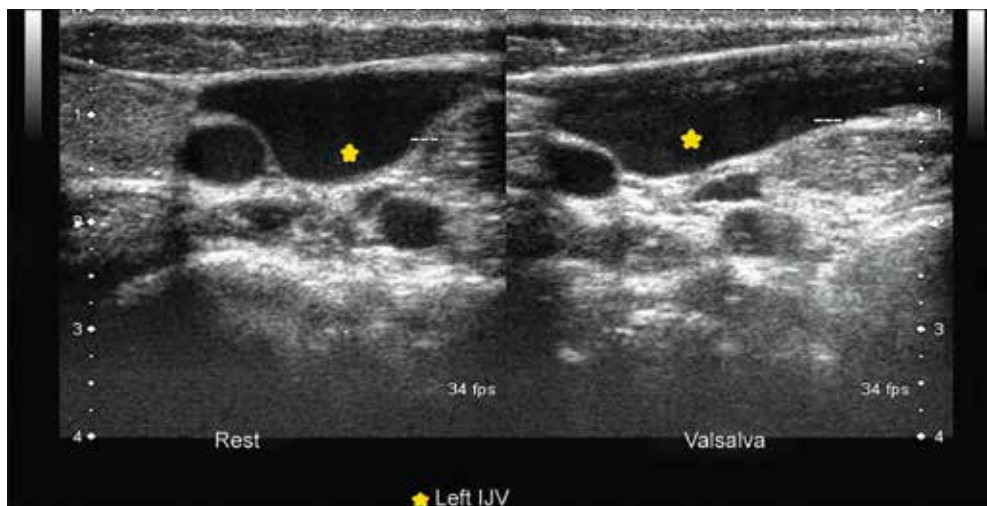


Fig. 1: Transverse ultrasound showing left IJV at rest and with valsalva manoeuvre

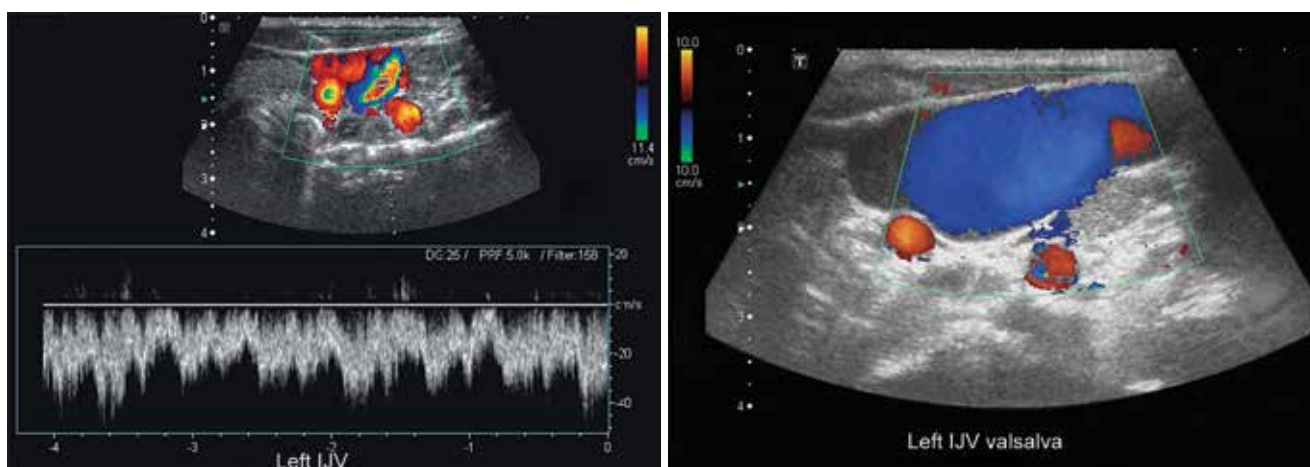


Fig. 2: Color-flow Doppler study showing difference in blood flow in IJV at rest and with valsalva manoeuvre

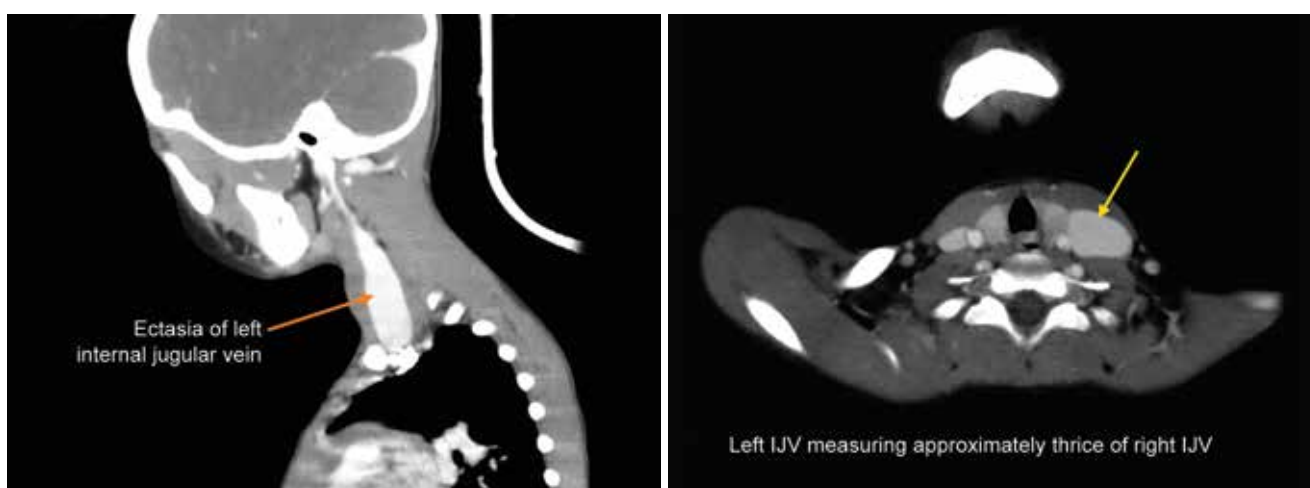


Fig. 3: Contrast enhanced CT scan showing left IJV was thrice of right IJV asymmetry of left IJV

**DISCUSSION**

In a child with soft mass in the neck that increases in size on straining, coughing or with valsalva manoeuvre, the differentials to be considered include laryngocele superior mediastinal neoplasms or cysts, hyperinflation of the cupula of the lung and jugular ectasia.<sup>3</sup>

Larry, a surgeon in Napoleon army, first described laryngocele in 1829 in Egypt.<sup>4</sup> Laryngoceles are abnormal dilatations of the laryngeal saccules. Usually, these communicate with the laryngeal lumen and are generally filled with air. They become more apparent clinically when air is forced into them or when they are filled with

fluid. Laryngocele account for over 20% of the true submucosal lesions of the larynx.<sup>5</sup>

Ectasia is used to describe outward dilatation of a vein which differs from varix, which implies dilatation plus tortuosity.<sup>6</sup> Gruberg was the first to report ectasia of IJV in 1875. Venous ectasia, is a rare disease also known by other names, such as venous aneurysm, venous pseudo aneurysm, congenital venous cyst, phlebectasia, venous cyst, and venoma;<sup>7</sup> usually seen in male children with right IJV reported to be 4 times more common than left.<sup>8</sup> The exact cause of this lesion still remains controversial, however, many proposed hypotheses include gross anatomic abnormality of the vein, mechanical compression of the brachiocephalic veins, congenital structural defect in the vein wall, acquired lesion of the vein, and, idiopathic causes.<sup>9</sup>

Jugular vein ectasia may present as a constellation of symptoms, like feeling of constriction, change in voice, sensation of choking and giddiness, bluish discolored bulging in the neck, discomfort during physical activity, discomfort on coughing, thrombosis, and tongue pain.<sup>10</sup> However, some cases may be asymptomatic and may have a very confusing presentation and may mimic laryngocele, as in our patient.

Radiological investigations serve as a boon in such situations. Lateral view cervical X-ray followed by ultrasonography proceed color-flow Doppler and/contrast enhanced CT lay the foundation for an accurate diagnosis.

Plain anteroposterior and lateral radiographs revealing an air column in a mass in the neck caters to the possibility of laryngocele. However, air column may be absent in cases of complicated laryngocele (laryngocele with pus or fluid level due to retained secretion or infection) and need not rule out possibility of laryngocele. In such instances, other investigations like USG and CT scan are warranted to reach a correct diagnosis.<sup>11</sup> Ultrasonography helps us to study in a non-invasive manner, the real time morphology, and has been found to be the most reliable investigation in such cases and should be performed on both sides of the neck.<sup>11</sup>

However, when combined with Doppler flow imaging, it confirms the presence or absence of blood flow and also reveals its direction.<sup>12</sup> Contrast enhanced CT scan of the neck region has been found to be extremely useful in terms of defining the spatial relationships, differentiating the lesion from other cystic/vascular formations and in identifying the coexistence of a laryngeal cancer with laryngocele.<sup>13</sup> Other investigations, such as MRA or venography have also been selectively found to be helpful to make a diagnosis but usually contrast enhanced CT

scan coupled with color-flow Doppler ultrasound are adequate to make a correct diagnosis.

Reported literature suggests that the diameter of the IJV can become upto four times (our case being approximately three times) wider on straining when compared without straining. The chance of thrombosis arising in these lesions is higher than the normal side, however, only very rarely thrombosis has been reported in cases of IJV ectasia.<sup>14</sup>

The treatment of choice for symptomatic patients remains surgical ligation and excision of the ectatic segment. But for asymptomatic cases, the opinion of surgeons varies. Some go ahead with surgical excision, whereas others prefer conservative management with periodic check-up and surgical intervention only if size increases significantly or becomes symptomatic.<sup>15</sup>

## CONCLUSION

Intermittent neck mass which exaggerates on blowing, coughing, straining or valsalva manoeuvre may suggest a diagnosis of laryngocele which is a relatively more common condition. But, the presentation may be very deceptive with venous ectasia a strong mimicker for laryngocele and radiological diagnostic tools are of immense value to reach the correct diagnosis.

## REFERENCES

1. Eric R. Grimes GI. Jugular venous ectasia can mimic a cystic hygroma—potential risk from sclerotherapy. *Int J Pediatr Otorhinolaryngol Extra* 2006;(1):50-52.
2. Stocks RM, Milburn M, Thompson J. Unusual neck masses secondary to jugular venous abnormalities: case report and discussion. *Am Surg* 1997 Apr;63(4):305-309.
3. Nwako FA, Agugua NE, Udeh CA, Osuorji RI. Jugular phlebectasia. *J Pediatr Surg* 1989 Mar;24(3):303-305.
4. Rutka J, Birt D. Laryngocele: a case report and review. *J Otolaryngol* 1983 Dec;12(6):389-392.
5. Saleh EM, Mancuso AA, Stringer SP. Computed tomography of submucosal and occult laryngeal masses. *J Comput Assist Tomogr* 1992 Feb;16(1):87-93.
6. Gerwig WH Jr. Internal jugular phlebectasia. *Ann Surg* 1952 Jan;135(1):130-133.
7. Bowdler DA, Singh SD. Internal jugular phlebectasia. *Int J Pediatr Otorhinolaryngol* 1986 Dec;12(2):165-171.
8. al-Dousary S. Internal jugular phlebectasia. *Int J Pediatr Otorhinolaryngol* 1997 Jan 3;38(3):273-280.
9. Danis RK. Isolated aneurysm of the internal jugular vein: a report of three cases. *J Pediatr Surg* 1982 Apr;17(2):130-131.
10. Balik E, Erdener A, Taneli C, Mevsim A, Sayan A, Yüce G. Jugular phlebectasia in children. *Eur J Pediatr Surg* 1993 Feb; 3(1):46-47.
11. Dhungel K, Gupta MK, Ahmad K, Sah PL, Rauniyar RK. Laryngocele masquerading as a soft tissue neck mass. *Kathmandu Univ Med J* 2009 Dec;7(28):423-425.



12. Walsh RM, Murty GE, Bradley PJ. Bilateral internal jugular phlebectasia. *J Laryngol Otol* 1992 Aug;106(8):753-754.
13. Shimizu M, Takagi Y, Yoshio H, Takeda R, Matsui O. Usefulness of ultrasonography and Doppler color flow imaging in the diagnosis of internal jugular phlebectasia. *Heart Vessels* 1992;7(2):95-98.
14. Mickelson SA, Spickler E, Roberts K. Management of internal jugular vein phlebectasia. *Otolaryngol Head Neck Surg* 1995 Mar;112(3):473-475.
15. Sander S, Eliçevik M, Unal M, Vural O. Jugular phlebectasia in children: is it rare or ignored? *J Pediatr Surg* 1999 Dec; 34(12):1829-1832.