

ORIGINAL RESEARCH

The Impact of Tracheotomy on the Eventual Outcome of Surgery for Benign Laryngotracheal Stenosis in a Tertiary Health Care Setup

¹Bachi T Hathiram, ²Vicky S Khattar

ABSTRACT

Introduction: Acquired benign laryngotracheal stenosis is often preventable. A majority of such patients have a history of some airway intervention, ranging from a planned endotracheal intubation for the purpose of anesthesia, to an emergency tracheotomy in the setting of stridor. The primary aim of the first treating clinician is to secure the airway, and often these patients already have a tracheotomy at the time of initial presentation.

Materials and methods: We analyzed 80 patients that have been managed for varying grades and locations of acquired benign laryngotracheal stenosis presenting to a tertiary healthcare centre, and analyzed the impact of tracheotomy on the eventual outcome.

Summary and conclusion: Tracheotomies performed in patients suffering from stenosis in the airway pose technical challenges. If planned even in the most urgent situations, they can play a vital role in determining the eventual outcome of the definitive treatment. The site, technique and care of the tracheotomy are key factors in determining the eventual outcome.

Keywords: Airway, Benign, Laryngotracheal stenosis, Tracheotomy.

How to cite this article: Hathiram BT, Khattar VS. The Impact of Tracheotomy on the Eventual Outcome of Surgery for Benign Laryngotracheal Stenosis in a Tertiary Health Care Setup. *Int J Otorhinolaryngol Clin* 2015;7(2):51-56.

Source of support: Nil

Conflict of interest: None

INTRODUCTION

Acquired benign laryngotracheal stenosis is often preventable; in the event of an established stenosis

at the time of initial presentation, a careful planning of the primary intervention often plays a vital role in determining the eventual outcome of the definitive treatment. Tracheotomy is the most common primary intervention performed, following which the definitive treatment strategy is planned. There have been occasions wherein the tracheotomy has been avoided altogether, or incorporated into the primary surgical strategy; this is possible in patients with incipient stenosis, or those that have been diagnosed and managed whilst in an indoor hospital setting. The latter is seen in post-traumatic laryngotracheal stenosis or in inflammatory pathologies, and is an exception, rather than the rule.

A majority of patients suffering from benign laryngotracheal stenosis have a previous history of endotracheal intubation. They have usually been in an intensive care setting, and following a resolution of the primary pathology, they are extubated and eventually discharged. Hoarseness and dysphonia after extubation are at times attributed to the general medical condition of the patient, and otherwise overlooked due to the more sinister nature of the primary disease for which the patient initially presented to the hospital.

The usual time lapse between the extubation and the onset of stenotic sequelae ranges anywhere between 3 and 6 weeks in our experience. By this time the patient has usually been discharged from hospital care, thus presenting in an emergency situation. It is at this time that some immediate airway management is needed, and we feel that this is a crucial event which plays an important role in deciding the eventual outcome of the definitive treatment.

Mucosal "trauma" following intubation can result from a variety of causes, namely direct trauma during the act of intubation, constant friction between the endotracheal tube and the airway mucosa, constant pressure due to the cuff of the endotracheal tube causing mucosal ischemia and subsequent necrosis, infection from secretions, etc. The net result is either a mucosal scar in the form of a band, web, etc., or the more sinister "framework collapse" as an outcome of cartilage devoid of mucosa, resulting in perichondritis and cartilage necrosis, with subsequent scar formation.

¹Professor and Head, ²Assistant Professor

^{1,2}Department of ENT, Head and Neck Surgery, Topiwala National Medical College and BYL Nair Charitable Hospital Mumbai, Maharashtra, India

Corresponding Author: Bachi T Hathiram, Professor and Head Department of ENT, Head and Neck Surgery, Topiwala National Medical College and BYL Nair Charitable Hospital, Mumbai Maharashtra, India, e-mail: ORLclinics@gmail.com

Mucosal trauma during tracheotomy has been known to occur due to various issues, such as a “traumatic” episode of tracheotomy wherein the patient has struggled during the insertion of the tube due to a variety of reasons, prolonged tracheotomy especially where the cuff has been inflated for extended periods of time (such as patients requiring positive pressure ventilation), tracheotomy itself when more than one tracheal ring is sacrificed during the procedure, lesions occurring due to the tip of the tracheotomy tube causing distal tracheal trauma, etc.

Numerous studies have mentioned the increasing incidence of stenotic airway sequelae following tracheotomy.¹⁻⁴ The reported incidence can be anywhere between 0.6 and 21%.² They have also discussed the various reasons that may lead to the tracheotomy causing stenosis. The site of tracheostomy has been mentioned as the commonest site.^{2,5,6} The incidence of stenosis is compounded by the presence of wound sepsis⁷ pre-existing chronic lung disease and airway infection.⁸

With the advent of propagators of an “early” tracheostomy for patients requiring long-term endotracheal intubation, it was hypothesized that the incidence of “iatrogenic” post-intubational stenosis would decline, eventually resulting in a lower incidence of laryngotracheal stenosis. However, literature has witnessed the contrary with Tsakiridis et al 2012 having mentioned that “post-tracheotomy stenosis is more common due to the earlier performance of tracheotomy in the intensive care units...” The same has been observed by Lim 2012.

Tracheotomy today is included as one of the commoner causes of benign laryngotracheal stenosis at par with endotracheal intubation in numerous studies. This is for patients intubated for any medical condition. In accordance, if this incidence is extrapolated to patients already suffering from airway compromise, one can fathom the sheer impact that a tracheotomy can have, *vis-à-vis* a patient that does not otherwise suffer from laryngotracheal stenosis. Thus one ends up dealing with two issues: The primary stenosis, as well as those changes induced by the tracheotomy itself.

MATERIALS AND METHODS

A total of 80 patients suffering from various grades and locations of laryngotracheal stenosis that were treated at the researchers’ institute between October 2006 and April 2015 were analyzed as regards their primary pathology, the primary airway management performed (which may have been elsewhere) as well as the definitive treatment delivered at the institute. The conditions surrounding the tracheotomy, the site of the tracheotomy and its

relation to the stenotic segment of the airway, details of the definitive treatment performed and the eventual outcome (if treatment completed) were analyzed. The data were studied applying the relevant statistical analysis as well as the tests of significance, and the observations and inference tabulated.

Only those patients that were followed up to the logical conclusion of their treatment were included in the study, whether that meant decannulation, or otherwise. All patients had some degree of cartilaginous stenosis, and had a tracheotomy performed prior to the definitive surgery. Only those patients that needed a resection and anastomotic procedure were included in the study, whether it was a partial cricotracheal resection or a tracheal resection with end-to-end anastomosis. Patients that were managed exclusively with endoscopic techniques were excluded from this analysis. The final position of the tracheotomy was decided as it appeared at the time of definitive surgery.

OBSERVATIONS

Numerous variables were analyzed during the course of the study, and observations were made as below:

- Site of tracheotomy in relation to the site of stenosis
- Number of tracheal rings cut
- Type of tracheotomy
- Presence of a “tip of cannula lesion”.

Each of the abovementioned variables have been analyzed in detail.

Site of tracheotomy in relation to the site of stenosis: All patients were analyzed clinically, radiologically and endoscopically, and a schematic diagrammatic representation of the airway was made, depicting the variables for discussion, namely “S” denoting the site of stenosis, “L” depicting the length of resection of the airway eventually required and the “green dot” depicting the site of the tracheotomy. All patients were then categorized into one of four categories depending upon the above variables, and analyzed. (1) The preoperative tracheotomy was performed as close to the site of stenosis as possible (Fig. 1), (2) The preoperative tracheotomy was performed more than four rings away from the site of stenosis (Fig. 2), (3) The preoperative tracheotomy was performed less than four rings away from the site of stenosis (Fig. 3), (4) The preoperative tracheotomy was performed through the stenosis (Fig. 4).

Number of tracheal rings cut: This observation was based on the number of rings found to be included in the tracheotomy at the time of definitive surgery, that needed to be sacrificed in order to obtain a stable end-to-end anastomosis.



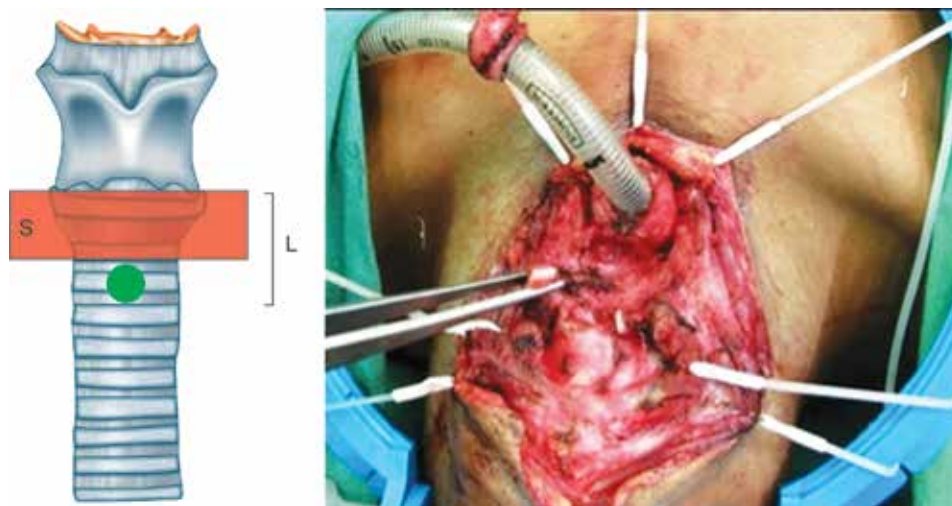


Fig. 1: The preoperative tracheotomy (green dot) performed very close to the site of stenosis “S”. Thus, the eventual length of resection needed “L” was reasonably less. The intraoperative view accompanying shows an armored endotracheal tube inserted through the site of tracheotomy, during the definitive surgery; one can appreciate the stenotic segment of trachea located just above the stoma, being excised

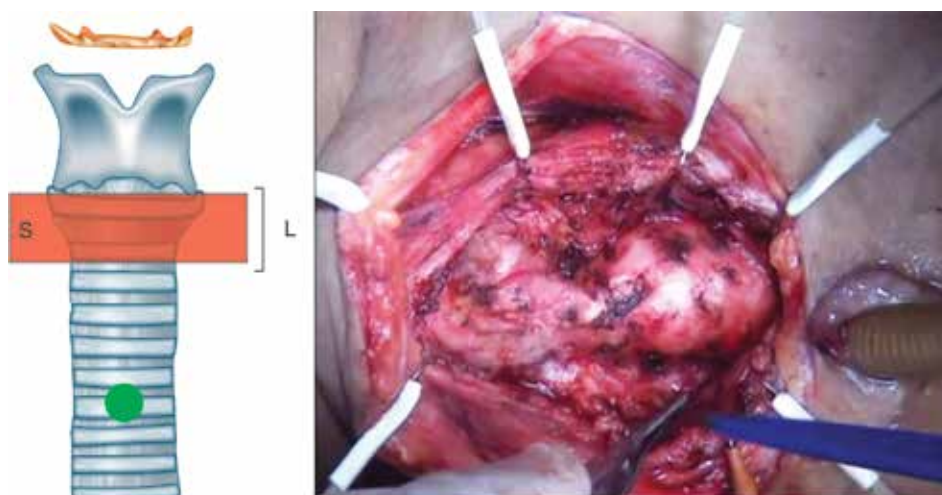


Fig. 2: The preoperative tracheotomy (green dot) performed very far from the site of stenosis “S”. Thus the eventual length of resection needed “L” was reasonably less, however, the tracheotomy was closed in a second stage after the primary anastomosis healed. Thus, it became a double-staged procedure. The same can be appreciated in the intraoperative view (to the right), wherein the stenotic segment is far away from the stoma

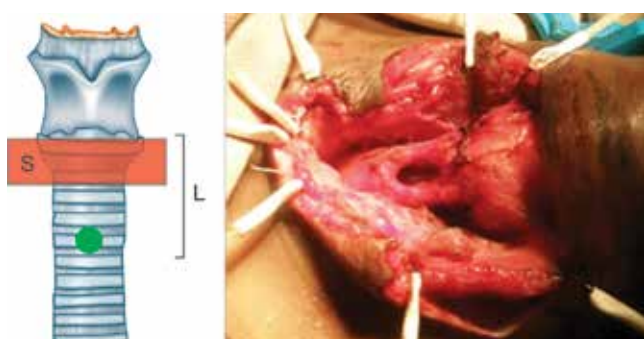


Fig. 3: The preoperative tracheotomy (green dot) performed not very close or far to the site of stenosis “S”. After performing the anastomosis, the site of tracheotomy ended up really close to the former. This probably served as a potential site for secretions to contaminate the anastomosis, thus, compromising it. If one had to sacrifice all the intervening rings, the eventual length of resection needed “L” was reasonably long, thus, putting the anastomosis under tension. The same can be appreciated in the intraoperative view (to the right) showing the final anastomosis extremely close to the stoma

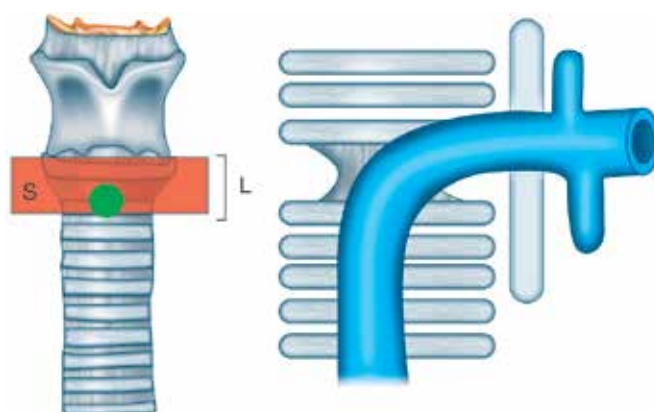


Fig. 4: The tracheotomy (green dot) was performed through the stenosis. This was possible in select cases wherein the stenosis was incipient, and partial at the time of initial presentation. The eventual length of resection “L” was the least, and the procedure could be performed in a single stage. To the right, the schematic diagram depicts the same in a sagittal view (S: Stenotic segment)

Type of tracheotomy: It was not possible to obtain details of most of the patients as regards their technique of tracheotomy, since most of the patients were tracheotomized prior to presenting to the institute. However, this variable was evaluated with respect to the presence of a pedicled tracheal flap at the time of surgery.

Presence of a "tip of cannula lesion": A lesion seen on the anterior tracheal wall in close relation to the tip of the tracheotomy tube was termed as a "tip of cannula lesion" and was seen as below.

DISCUSSION

Site of tracheotomy in relation to the site of stenosis (Graph 1): In order to analyze this factor, the authors further classified the patients in each of the four categories into those done as an Graph 5.

In decreasing order of a favorable outcome after definitive surgery, category IV was considered the ideal situation, wherein the tracheotomy tube was inserted through the stenotic segment, thus salvaging the proximal and distal normal segments of airway. During the definitive surgery, the stenotic segment was the only part of the airway that was sacrificed, thus preventing undue wastage of normal cartilage framework. Irrespective of the site of the stenosis, this resulted in the most favorable outcome. However, observing the circumstances under which these tracheotomies were performed, it was observed that only one emergency tracheotomy fell into this category, whilst the remaining were all planned. This was only possible in patients who had a partial/impending stenosis and those who were detected in time (either in a hospital setting or those that simply presented early).

In the authors' experience, in a patient with impending stenosis, one usually has sufficient time to ventilate the patient and perform an endoscopic evaluation to determine the exact site of the stenosis, and the status

of the mucosa so as to plan a tracheotomy without any "wastage" of cartilaginous framework. This evaluation has proved to be a game-changing event in the evolution of the treatment wherein the final outcome can be optimized to the best possible for the particular patient.

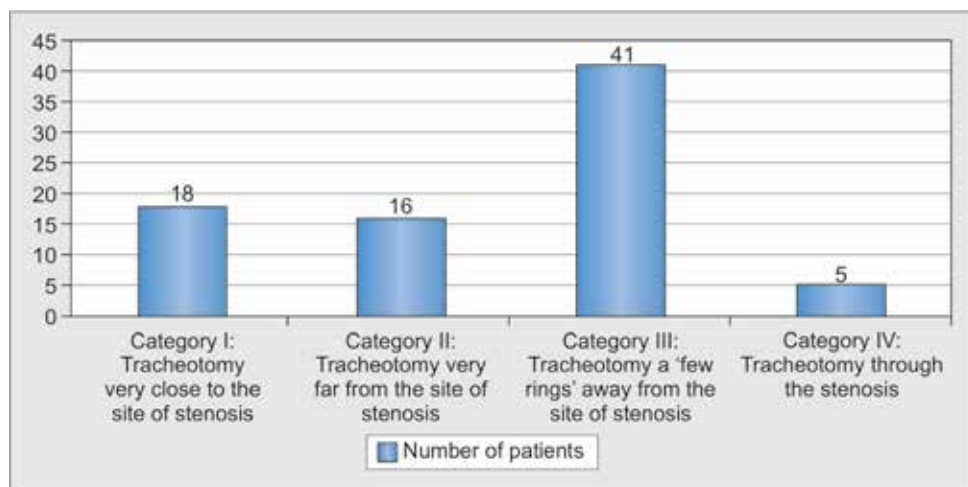
Even in patients that present in an emergent situation, it is usually possible to plan the tracheotomy, atleast to an extent wherein the eventual outcome is not affected in a negative manner.

Coming to the second best scenario (category I) wherein the tracheotomy was performed just below the site of stenosis. This is still a favorable situation as there is not much wastage of normal tracheal armature. It is heartening to observe that 11 of these patients were tracheotomized on an emergency basis. It further corroborates the fact that there is usually sufficient time to "plan" the site of tracheotomy.

Patients belonging to the II category still had a favorable outcome, barring the fact that they all needed a second stage to close the tracheotomy. The only potential added advantage would be that the new distal tracheotomy would allow for the anastomosis to "rest" and heal, without much movement at the anastomotic site due to the trachea being "hitched" to the skin with the distal tracheotomy.

Category III patients pose the biggest challenge to the treating clinician, calling for much skill and effort to tackle this situation. Tracheotomies placed thus would end up being very close to the site of anastomosis, allowing for secretions and infection to compromise the latter, and eventually the final outcome; in order to prevent the same one would have to resect the tracheotomy along with the stenotic segment, which would mean wastage of the interval "normal" tracheal rings. Thirteen of our patients in this category were planned procedures!

Number of tracheal rings cut and type of tracheotomy (Graph 2): A majority (68 patients) had two or more



Graph 1: The site of tracheotomy in relation to the site of airway stenosis



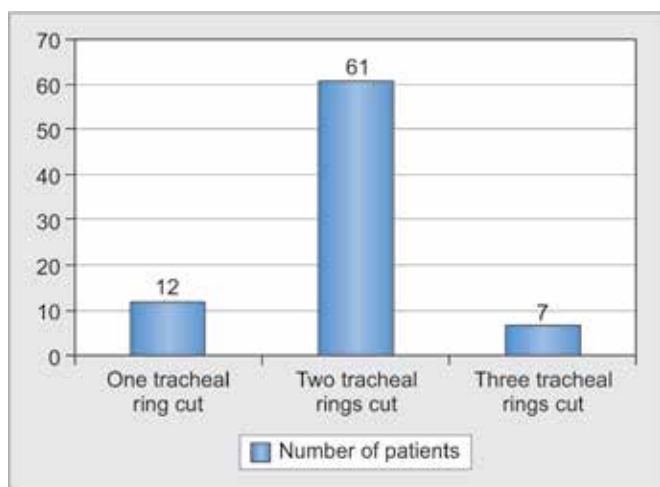
tracheal rings found cut at the time of definitive surgery. In most scenarios, devising a tracheotomy from a single tracheal ring is adequate regardless of its indication. In patients with airway stenosis, each tracheal ring counts, and avoiding undue “wastage” can make all the difference. To quote Hermes Grillo,⁹ “the tracheal tailor quickly runs out of cloth.” In the authors’ experience, the ideal way to avoid cutting more rings was the use of an inferiorly based (Graph 3), pedicled Bjork flap, which could serve both the purpose of a permanent tracheotomy, as well as be reversed without loss of any cartilage. The authors recommend using the Bjork flap in all electively planned tracheotomies, and eventually attempting to do the same even in urgent situations.

Presence of a tip of cannula lesion (Graph 4): Endotracheal and tracheotomy tubes are designed to match the curved trajectory of intubation, as well as to accommodate for various thicknesses of the skin and subcutaneous tissues. Accordingly, one can understand that using a curved tube in a relatively vertical conduit, such as the trachea, is going to cause some abutment at its tip, which when coupled

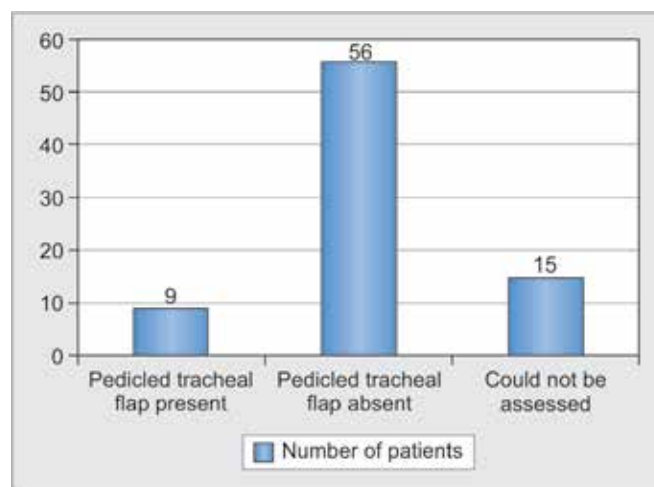
with prolonged pressure and/or infection can lead to a spectrum of lesions ranging from an insignificant scar, to granulation tissue, and eventually to stenosis. A majority of our patients (48 out of 80) presented with varying grades of such lesions. While such lesions may occur in many patients, reducing the duration of intubation, making the episode of intubation as least traumatic as possible and using tubes manufactured from highly biocompatible materials, such as medical grade silicone can minimize their occurrence. Even once occurred, they need to be detected early and that too in as early a stage as possible so as to prevent stenotic sequelae.

CONCLUSION

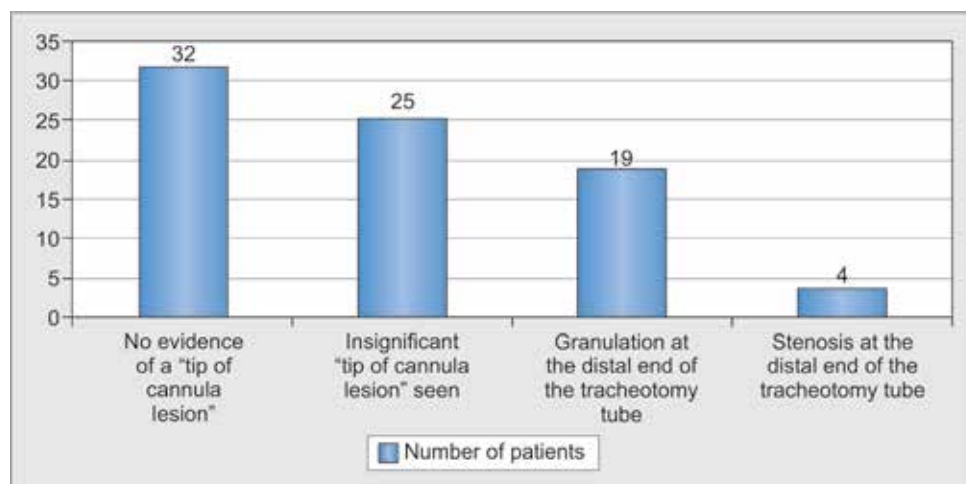
Tracheotomies performed in patients suffering from stenosis in the airway pose technical challenges. If planned even in the most urgent situations, they can play a vital role in determining the eventual outcome of the definitive treatment. The site, technique and care of the tracheotomy are key factors in determining the eventual outcome.



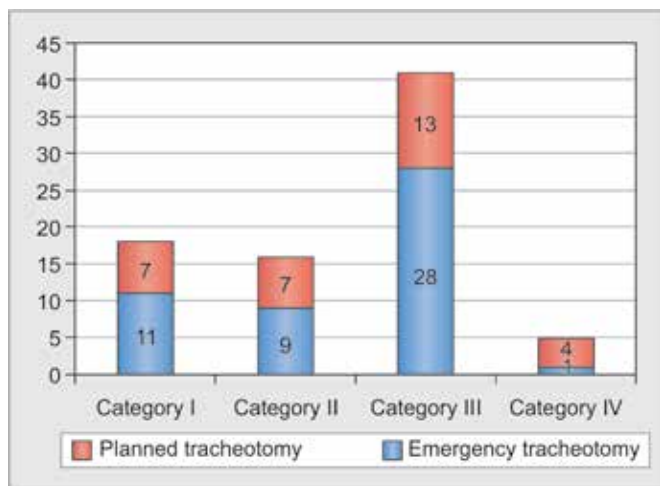
Graph 2: Number of tracheal rings that were found to be cut during definitive surgery



Graph 3: The number of patients that had a pedicled tracheal flap at the site of preoperative tracheotomy



Graph 4: The number of patients who had tracheal complications due to varying grades of “tip of cannula” lesions



Graph 5: The number of patients in each category (vide Graph 1) further subclassified into “emergency” and “planned”.

REFERENCES

1. Lim SY, et al. Prognostic factors for endotracheal silicone stenting in the management of inoperable postintubation tracheal stenosis. *Yonsei Med J* 2012;53(3):565-570.
2. Bacon JL, et al. Indications and interventional options for non-resectable tracheal stenosis. *J Thoracic Dis* 2014;6(3):258-270.
3. Tsakiridis K, et al. Management of complex benign post-tracheostomy tracheal stenosis with bronchoscopic insertion of silicon tracheal stents, in patients with failed or contraindicated surgical reconstruction of trachea. *J Thoracic Dis* 2012;4(S1):32-40.
4. Hashemzadeh S, et al. Surgical Treatment of postintubation tracheal stenosis: Iranian experience of effect of previous tracheostomy. *Int J Gen Med* 2012;5:93-98.
5. Anand VK, Alemar G, Warren ET. Surgical considerations in tracheal stenosis. *Laryngoscope* 1992;102:237-243.
6. Pearson FG, Andrews MJ. Detection and management of tracheal stenosis following cuffed tube tracheotomy. *Ann Thorac Surg* 1971;12:359-374.
7. Sarper A, et al. Tracheal stenosis after tracheotomy or intubation: review with social regard to cause and management. *Tex Heart Inst J* 2005;32:154-158.
8. Pearson FB, Fairley HB. Tracheal stenosis complicating tracheotomy with cuffed tubes. *Int Anesthesiol Clin* 1970;8:889-905.
9. Grillo H. *Surgery of the trachea and bronchi: preoperative considerations*. BC Decker Inc. 2004. p. 445. ISBN 1-55009-058-5 USA.

