

# Anesthesia for Middle Ear Surgeries and Cochlear Implant

<sup>1</sup>Harprit Kaur Madan, <sup>2</sup>Suchita Kosare

## ABSTRACT

The attending anesthesiologist face several challenges in safe conduction of anesthesia for middle ear and cochlear implantation surgeries. Preoperative challenges includes counseling elderly patients with impaired hearing and counseling the parents of children with congenital ear anomalies, thorough evaluation of these patient with several comorbidities. Intraoperative challenges are to provide bloodless field, head positioning, effect of nitrous oxide on middle ear, facial nerve monitoring and avoid electrical disturbances due to electrocautery during stimulation of the cochlear implant electrode assembly. Postoperative challenges includes smooth and calm recovery, prevention and treatment of postoperative nausea and vomiting (PONV) and excellent analgesia. A close understanding and cooperation between the anesthesiologist and surgeon is the key for a positive outcome.

**Keywords:** Cochlear implant, Mastoidectomy, Middle ear, Tympanoplast.

**How to cite this article:** Madan HK, Kosare S. Anesthesia for Middle Ear Surgeries and Cochlear Implant. *Int J Otorhinolaryngol Clin* 2015;7(1):1-9.

**Source of support:** Nil

**Conflict of interest:** None

## INTRODUCTION

The ear is composed of three compartments: the external ear, the middle ear, and the inner ear. The auricle (visible part of ear) is composed mainly of yellow elastic cartilage covered by skin and consists of the helix, antihelix, lobule, tragus, and concha. The ear contains two specialized sensory organs, the cochlea and the vestibular apparatus, enclosed in the extremely hard protective casing of the temporal bone (Fig. 1).<sup>1</sup>

The middle ear refers to an air-filled space between the tympanic membrane and the oval window. It is connected to the nasopharynx by the eustachian tube and is in close proximity to the temporal lobe, cerebellum, jugular bulb, and the labyrinth of the inner ear. The middle ear contains three ossicles—the malleus, incus

and stapes—which are responsible for transmission of sound vibration from the eardrum to the cochlea. This air-filled cavity is traversed by the facial nerve before it exits the skull via the stylomastoid foramen.<sup>2,3</sup> The facial nerve provides motor innervation to the muscles of facial expression.<sup>4</sup>

## Nerve Supply

Four sensory nerves supply the external ear (Fig. 2).<sup>1,4</sup>

- The auriculotemporal nerve originates from the mandibular branch of the trigeminal nerve. It innervates the anterosuperior and anteromedial aspects of the auricle, thus supplies the outer auditory meatus
- The great auricular nerve supplies the medial and lower aspect of the auricle and part of the external auditory meatus
- The auricular branch of the vagus nerve (Arnold's nerve) supplies the concha and the external auditory meatus
- Lesser occipital nerve innervates a small portion of the helix.

## Other Nerves

- The tympanic nerves supply the tympanic cavity. Knowledge of the nerve anatomy is critical in understanding anesthesia of the ear.

Ear surgery includes:

External ear: otoplasty

External auditory canal cholesteatoma

External auditory canal (EAC) foreign body, etc.

*Middle ear:* Tympanoplasty (reconstructive surgery for the tympanic membrane or eardrum).

Mastoidectomy for removal of infected air cells within the mastoid bone.

Myringotomy (myringoplasty is a technique for reconstructing a vibrating tympanic membrane).

Stapedectomy or ossiculoplasty for otosclerosis

*Grommet insertion:* An operation to insert ear grommets is a common treatment for glue ear, which occurs in children who suffer from repeated ear infections.

*Inner ear:* Cochlear implantation

Endolymphatic sac surgeries.

*Middle ear:* Common middle ear surgeries in adults:<sup>3</sup>

- Tympanoplasty
- Stapedectomy

<sup>1,2</sup>Assistant Professor

<sup>1,2</sup>Department of Anesthesia, HBT Medical College and Dr RN Cooper Municipal General Hospital, Mumbai, Maharashtra, India

**Corresponding Author:** Harprit Kaur Madan, Assistant Professor Department of Anesthesia, HBT Medical College and Dr RN Cooper Municipal General Hospital, Mumbai, Maharashtra, India Phone: 9870091313, e-mail: drpreet@hotmail.com

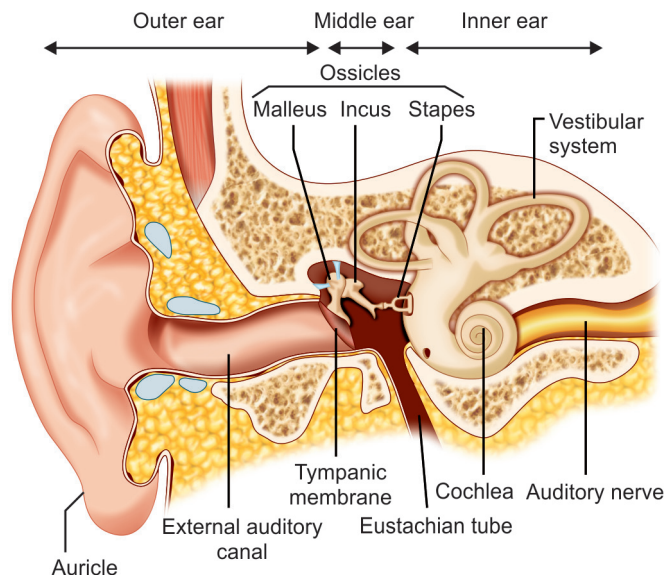


Fig. 1: Anatomy of ear

- Ossiculoplasty
  - Mastoidectomy
  - Cholesteatoma surgery via intact ear canal<sup>2,3</sup>
- Common middle ear surgery in children includes:<sup>3</sup>
- Tympanoplasty
  - Mastoidectomy
  - Myringotomy
  - Grommet insertion.

### CHOICE OF ANESTHESIA FOR MIDDLE EAR SURGERIES

Some of these procedures can be performed under local anesthesia with or without sedation, although all surgeries can be performed under general anesthesia if necessitated by surgical or patient factors.

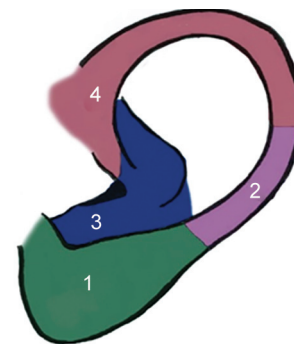
#### Local Anesthesia

##### Surgical Factors

- Uncomplicated middle ear surgery can be performed under local anesthesia.<sup>4</sup>
- Tympanoplasty
- Insertion of grommet
- Myringoplasty
- Stapedotomy
- Stapedectomy
- Ossiculoplasty
- Modified radical mastoidectomy
- Cholesteatoma surgery via intact ear canal

##### Patient Factors

- Adult
- Patients who are able to understand the procedure, and to communicate and cooperate throughout the procedure, are suitable candidates for local anesthesia with or for foregoing sedation.<sup>4</sup>



Key:  
 1. Great auricular nerve  
 2. Lesser occipital nerve  
 3. Auricular branch of vagus nerve  
 4. Auriculotemporal nerve

Fig. 2: Nerve supply of ear

Many surgeons prefer local anesthesia due to less bleeding cost effectiveness, postoperative analgesia, mobilization of the patient in a short time, reduced aspiration risk because of a normal cough reflex and that the hearing can be tested during the surgery. Preoperative sedation and local anesthesia allows the patient to undergo a comfortable procedure.<sup>5</sup>

#### For General Anesthesia<sup>4</sup>

##### 1. Surgical Factors

- Surgery might be better performed under general anesthesia
- Long operations
- Complicated surgery (e.g. extensive scar tissue in middle ear).

##### 2 Patient Factors<sup>4</sup>

- Mentally unstable, uncooperative patients who will not cooperate for local anesthesia
- Children
- Patients who request general anesthesia.

### ANESTHESIA CONSIDERATIONS OF MIDDLE EAR SURGERIES

For adults, simple middle ear surgery can be performed under local or general anesthesia, although complicated or long procedures should be performed under general anesthesia.

Given the unique location, size, and delicate content of the middle ear, great care must be taken during the perioperative period. Special considerations taken during middle ear surgeries include:<sup>3,4,6</sup>

- Provision of a bloodless surgical field: A bloodless surgical field is ideal, as even small amounts of blood will obscure the surgeon's view in microsurgery.
- Attention to patient's head positioning, attention to patient's head positioning is important to avoid venous

obstruction and congestion. Extreme hyperextension or torsion can cause injury to the brachial plexus and the cervical spine and to allow optimal exposure of the surgical field while maintaining the patient safe.

- Airway management
- Facial nerve monitoring: It is done in closed and open mastoido-epitympanectomy, revision surgery after radical mastoidectomy, tympanoplasty in atretic ears.
- The effect of nitrous oxide on the middle ear
- Avoidance of intratympanic pressure fluctuations
- A smooth and calm recovery
- Prevention of postoperative nausea and vomiting (PONV).

### PREOPERATIVE CONSIDERATIONS

Patients undergoing middle ear surgery often suffer from extensive hearing loss, thus hindering their ability to cooperate, and in this situation, hearing aid *in situ* in the nonsurgical ear before induction and replacement before emergence may help to minimize anxiety and ease communication<sup>7</sup>

- Oral anxiolytics premedication with benzodiazepines can be considered or standard sedation regimens.
- A history of cardiovascular disease, hypovolemia, and anemia will limit the degree of hypotension possible.
- In pediatric patients, in addition to the usual components of preoperative assessment, it is important to check for coexisting syndromes and recent upper respiratory tract infection.<sup>7</sup>
- Antiemetics to prevent PONV.

### INTRAOPERATIVE CONSIDERATIONS

Tympanoplasty and mastoidectomy are two of the most common procedures performed on the middle ear and accessory structures.

- *Head positioning*: To gain access to the surgical site, the head is positioned on a head rest, which may be lower than the operative table, and extreme degrees of lateral rotation may be required. Extreme tension on the heads of the sternocleidomastoid muscles must be avoided. The laxity of the ligaments of the cervical spine and the immaturity of odontoid process in children make them especially prone to C1–C2 subluxation.<sup>8</sup>
- Maintenance of a stable, adequate plane of anesthesia at all times.<sup>9</sup>
- *Sedation*: A wide variety of drugs are available for providing sedation, anxiolysis and analgesia like midazolam, diazepam, propofol, ketamine, fentanyl, dexmedetomidine. An ideal drug for sedation should have a rapid onset of action, predictable dose effect

relationship, minimum excitatory effects and minimal cardiorespiratory depression. It should produce anxiolysis, amnesia and should have a rapid recovery following discontinuation of its administration.<sup>10</sup>

- *Local anesthesia*: Concentrated epinephrine solution, often 1:1,000, can be injected in the area of the tympanic vessels to produce vasoconstriction. Close attention should be paid to the volume of injected epinephrine to avoid dysrhythmias and wide swings in blood pressure.<sup>5</sup> In ear surgeries, excellent analgesia is achieved by blocking the branches of the great auricular nerve (retroauricular infiltration) and tympanic branch of auriculotemporal nerve (V-shaped infiltration). The mastoid cells are devoid of sensations, so drilling is not painful for the patient. Pain sensation depends not only on the extent of surgical trauma and infiltration technique, but also on the patient's emotional status and previous experiences. Careful explanation of the procedure in the preoperative visit reduces the anxiety.<sup>11</sup>

Under local anesthesia patients may experience various discomforts like a sense of noise, anxiety, dizziness, backache, claustrophobia or earache.<sup>12</sup>

- *Bloodless field*: A bloodless operative field is essential in microsurgery because even a few drops of blood can obscure the surgical field. Physical and pharmacologic techniques are used.<sup>4</sup>
- *Head-up tilt 15 to 20 degrees*: A slightly elevated position of the head reduces arterial and venous pressures in areas above the heart; however, it increases the risk of air embolism. In the presence of hypotension, elevating the head will further compromise perfusion of the head and neck region.
- Avoidance of venous obstruction
- Normocapnia
- Controlled hypotension.

*Pharmacologic agents used*: Inhalation anesthetics (sevoflurane, desflurane) opioids (fentanyl), alpha-2 adrenergic agonists (clonidine and dexmedetomidine), beta adrenoceptor antagonists (labetalol and esmolol) and vasodilators. However, controlled hypotension is not without risk; in addition to the adverse effects of certain pharmacologic agents, it can cause tissue hypoxia by reducing microcirculatory autoregulation of vital organs.<sup>4</sup>

- Effects of nitrous oxide

The use of nitrous oxide in middle ear surgery is particularly controversial.<sup>4</sup> The middle ear and sinuses are air-filled, non-distensible cavities. An increase in the volume of gas in these structures results in an increase in pressure. N<sub>2</sub>O diffuses along a concentration gradient into the air-filled middle ear spaces more rapidly than nitrogen moves out. Passive venting occurs at

20 to 30 cm H<sub>2</sub>O pressure, and it has been shown that use of N<sub>2</sub>O results in pressures that exceed the ability of the eustachian tube to vent the middle ear within 5 minutes, leading to pressure build-up.<sup>13</sup>

During tympanoplasty, the middle ear is open to the atmosphere; thus there is no build-up of pressure, but once a tympanic membrane graft is placed the continued use of nitrous oxide might cause displacement of graft. At the end of surgery, when it is discontinued, nitrous oxide is rapidly absorbed, which may then result in negative pressure also possibly resulting in graft dislodgement, serous otitis media, disarticulation of the stapes, or impaired hearing.<sup>4,14</sup> This may last up to 6 weeks after surgery.<sup>11</sup> Nitrous oxide can be used in general balanced anesthesia with discontinuation 15 to 45 minutes before insertion of the tympanic membrane and completion of middle ear surgery.<sup>15</sup>

- *Smooth emergence from anesthesia, without bucking, coughing, or straining:*<sup>9</sup> Coughing on the endotracheal tube during emergence will increase venous pressure and may cause bleeding (as well as increased middle ear pressure), deep extubation is often utilized. After mastoidectomy, a head bandage will be applied and there can be much movement of the head resulting in coughing and bucking on the endotracheal tube. This is not desirable due to the risk of bleeding, so a deep plane of anesthesia is maintained until the bandage has been applied.<sup>8</sup>
- Avoidance of PONV.<sup>9</sup> Postoperative nausea and vomiting can disrupt grafts and prostheses and needs to be controlled.<sup>4</sup>
- Fast-tracking patients for discharge from the recovery room, where appropriate.<sup>9</sup>

## POSTOPERATIVE CONSIDERATIONS

- *Postoperative nausea and vomiting:*<sup>4,6,9,14</sup> Middle ear surgery is associated with a high incidence of PONV. In the absence of antiemetic treatment, 62 to 80% of patients will be afflicted. The etiology of PONV is multifactorial and depends on various factors, including patient demographics, history of PONV, anesthetic technique, use of nitrous oxide, duration of anesthesia and operation, and even surgical experience. Total intravenous anesthesia (TIVA) reduces PONV compared with using volatile agents. Use of nitrous oxide is associated with a higher incidence of PONV, which is a direct result of negative middle ear pressure during recovery. The vestibular system is stimulated by traction placed on the round window by the negative pressure that is created. Although all patients have the potential for nausea and vomiting after surgery, children younger than

8 years of age seem to be most affected.<sup>13</sup> Prophylactic administration of antiemetic medication decreases the incidence of PONV.

- *Vertigo:* Patients undergoing ear surgery should be carefully assessed for vertigo postoperatively in order to minimize the risk of falling during ambulation secondary to an unsteady gait.
- *Facial nerve injury:*<sup>3,6,14</sup> Facial nerve injury is perhaps the most devastating complication of otologic surgery and is preventable in the majority of cases. The facial nerve is at greatest risk during mastoidectomy, although it can be injured during tympanoplasty also. Early facial paralysis may be secondary to local anesthetic, and a few hours should suffice to allow the anesthetic effect to subside. In those cases in which the nerve has been positively identified and is known not to have been injured, the paralysis should be managed expectantly. Corticosteroids may be helpful. In the majority of such cases, the paralysis will resolve with no need for surgical intervention.

*Intraoperative complications:*

- Injury to chorda tympani
- Bleeding
- Facial nerve injury (if dehiscence)

*Postoperative complications:*<sup>16</sup>

*Early complications are:*<sup>14</sup>

- Facial nerve injury
- Sensorineural hearing loss
- Disequilibrium
- Chorda tympani nerve injury
- Wound infection
- Perichondritis
- Injury of the sigmoid sinus, jugular bulb, and dura
- Cerebrospinal fluid leakage.

*Late complications include:*<sup>16</sup>

- Recurrent cholesteatoma
- Graft failure, blunting of the anterior tympanomeatal angle
- Stenosis of the external auditory canal
- Prosthesis displacement/extrusion.

## COCHLEAR IMPLANT AND ANESTHESIA CONSIDERATIONS

### Introduction

The advancement in the technology of the cochlear implants has resulted in increasing trend of cochlear implantation in both the children and elderly population. The anesthesiologist is faced with the task of smoothly conducting the surgery without any interference in the stimulation techniques used. The preoperative evaluation is mainly focused on the presence of any congenital anomalies in these patients which may affect anesthetic



technique. The reduction of anxiety of the patient as well as the parents of small children is an important aspect of the preoperative visit. Intraoperatively, the anesthetics technique chosen should not interfere with the stimulation of the cochlear implant electrode assembly. The postoperative management is mainly focused at prevention of agitation and good analgesia. A close cooperation between the surgeon and the anesthesiologist is essential for a positive outcome in this surgery.<sup>17</sup>

A cochlear implant (CI) (Figs 3A and B) is an electrical device that is surgically implanted to provide sound for patients with bilateral severe sensorineural deafness. Its goal is to improve hearing, but unlike a hearing aid, which amplifies sound, the cochlear implant bypasses the damaged portion of the ear and directly stimulates the auditory nerve by way of an electrical impulse.<sup>18</sup> Normal hearing is not fully restored by a CI, but the representation of sound that it provides is adequate for the patient to understand speech and environmental sounds. Studies have shown significant improvements in quality of life for postlingual deafness CI recipients.<sup>19,20</sup>

Cochlear implants are considered to be an important landmark development in otology.<sup>21</sup> As such role of the anesthesiologist is crucial during such expensive surgical procedures for a better outcome.

### Selection of Patient

The most common candidates for CI surgery are children but adults and sometimes elderly people, with failure of hearing aids may be considered for this surgery.

### Elderly Patients

Presbycusis, or age-related sensorineural hearing loss, is a common disorder that affects approximately 40 to 50% of people over the age of 75.<sup>22</sup> Hearing loss is typically bilateral and symmetrical and affects the higher range of frequencies first.<sup>23</sup> An individual with presbycusis

will have decreased hearing sensitivity and speech understanding, in addition to poor sound localization.

*Causes generally include*

- Accumulated noise exposure
- Medical conditions, such as heart disease, vascular disease, and diabetes
- Some medications
- Ontological disorders
- Genetic susceptibility.

### Pediatrics Patients

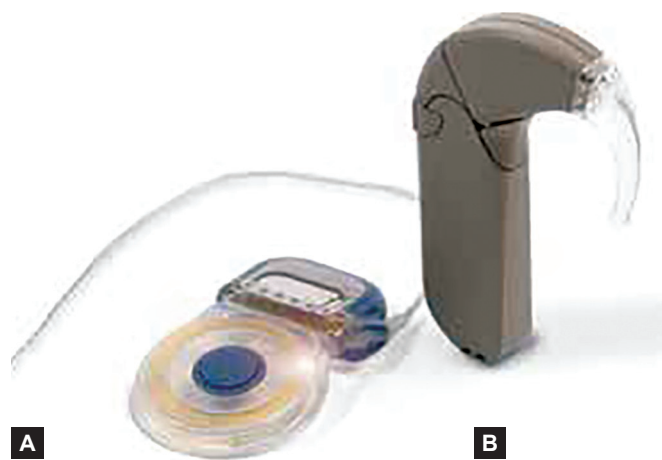Early detection of hearing impairment in childhood is essential for proper development of learning and listening skills and early implantation of cochlea leads to acquisition of these skills and thus also helps in mental and intellectual development of the child. It has been found that proper development of both the speech as well as vocabulary occurs if the child receives the cochlear implant before 2.5 years of age.<sup>24</sup> Surgical procedure itself needs the facial nerve to be identified and for which proper development of facial ridges is important which usually develops by 2 years of age.

Approximately 50% of the cases have acquired hearing loss mostly because of perinatal infections with TORCH group of organisms.

Preoperatively, it is essential to screen for the presence of various congenital syndromes leading to deaf-mutism as the systemic involvement in these syndromes may affect the anesthetic management. Also, the various types of dysplasia of temporal bone and cochlea associated with these syndromes may render the surgeons to change the surgical technique of cochlear implantation.

*The various congenital syndromes and their anesthetic implications.*

- Usher syndrome
  - Associated with impaired vision because of congenital cataracts, it should be corrected preoperatively so that maximum help can be obtained with lip-reading during postsurgical auditory rehabilitation.
- Treacher Collins syndrome
  - Abnormalities in facial appearance and therefore difficult airway
- Klippel-Feil anomaly
  - Associated with fusion of the cervical vertebrae making the intubation of the trachea a difficult proposition.
- Alport syndrome
  - Associated with renal failure and endocrinal abnormalities
- Pendred syndrome
  - Associated with goiter and metabolic disorders
- Jervell and Lange-Nielsen syndrome



**Figs 3A and B:** Cochlear Implant: (A) Implant inserted during a surgical procedure and (B) external sound processor worn over the ear

- Usually associated with a history of syncopal attacks or fits, especially a syncopal episode requiring placement of an automatic pacemaker and defibrillator subsequently, during auditory rehabilitation<sup>25</sup>
- Prolonged QT interval on the ECG leading to dangerous ventricular arrhythmias. Therefore, these patients could be treated with beta blockers prior to cochlear implant surgery.
- Increase incidence of hypoglycemic episodes during preoperative period.

## INVESTIGATIONS

Objective assessment of hearing:

- Steady state evoked potential
- Auditory brainstem evoked potential
- Electrocochleography
- Radiographs of skull
- High resolution computed tomographic scan (HRCT) of the temporal bone
  - To visualize the basal turn of cochlea, its patency and any abnormal ossification within it
  - Degree of pneumatization of mastoid
  - Any congenital abnormality in inner ear, and any fluid accumulation in middle ear.
- Magnetic resonance imaging (MRI)
  - Identification of sequelae of labyrinthitis with fibrous tissue filled cochlea where the placement of electrodes may be difficult.<sup>26</sup>

## CONTRAINDICATION

The presence of acute or chronic suppurative otitis media with or without cholesteatoma was considered contraindication for cochlear implant surgery previously, but now with adequate control of the infection preoperatively and with the measures to prevent recurrence of the disease, it is no longer considered a contraindication.

## CHOICE OF ANESTHESIA

Although CI surgery has been performed under local with monitored anesthesia care,<sup>27,28</sup> as a rule, general anesthesia with endotracheal intubation is the preferred anesthetic.

- LA with sedation in adult and cooperative patients only
- General anesthesia preferred due to
  - *Surgery under microscope visualization*: Slight patient movement adds risk of injury to middle ear structures
  - Pediatric patients
  - Long duration of surgery

## PREOPERATIVE MANAGEMENT

Preoperative examination to assess:

- Presence of any congenital abnormalities
- Developmental milestones
- Cerebral palsy
- Any neuromotor deficits
- Presence of any active upper respiratory infections.

## Counseling

Majority of the patients coming for CI surgery are children with hearing impairment and hence communication with these children is very important to establish a good rapport preoperatively. The children and the parents should be counselled after detailed description of the surgical and anesthetic procedure. This also helps in allaying anxiety of both the child as well as the parents.

## Premedication

Premedication with benzodiazepines given prior to anesthesia induction helps in reduction in separation and induction anxiety in children with a favorable pharmacokinetic profile and minimal effects on recovery profiles.<sup>29</sup>

Most CI surgeons use prophylactic antibiotics that should be given intravenously before the first incision.

Preoperative preparation may include the administration of a broad-spectrum antibiotic to help reduce the chance of wound infection.<sup>30,31</sup>

A multifactorial approach to prophylaxis for PONV should also be taken.

## INTRAOPERATIVE MANAGEMENT

*Anesthesia induction*: The intraoperative monitoring should include electrocardiogram, pulse oximetry, noninvasive blood pressure, capnography, and neuromuscular monitoring.

Induction of anesthesia can occur in the standard manner in adults using thiopentone or propofol intravenously with the analgesia given by opioid intravenously. The induction in children can be done by sevoflurane induction. Tracheal intubation is achieved after neuromuscular blockade and appropriate sized endotracheal tube is then secured in place after confirming bilateral equal air entry. Attenuation of pressor response with preoperative dexmedetomidine in a dose of 1 µg/kg not only provides stable hemodynamics during induction and intraoperative period enabling a smoother control to provide a bloodless field during surgery, but also decreases the requirement of anesthetic drugs during perioperative period.<sup>32</sup>

## Intraoperative Surgical Complications

### Facial Nerve Injury

- Can be minimized by using electromyographic neuromonitoring during surgery.
- Neuromuscular blockers and local anesthetics may interfere with transmission of signals and should therefore be allowed to wear off before the mastoidectomy part of the operation.<sup>33</sup>

### Dural Injury

- The high-speed mastoid drill can injure the dura resulting in a bleed and cerebrospinal fluid (CSF) leak.

### Treatment

- Lowering CSF pressure by hyperventilating the patient to an ET CO<sub>2</sub> of 27 to 29 mm Hg
- Repairing the defect with tissue and bone wax.
- Administration of mannitol
- Placement in the reverse Trendelenburg position.<sup>34</sup>

### Bleeding

- Usually minor
- Unless the sigmoid sinus is injured, in which case there is a risk of air embolism and sudden right-sided heart failure.

Treatment of air embolism:

Immediate occlusion of the venous bleeding with pressure or saline

- Turning the patient on the left side
- Aspirating the embolus
- Administering 100% oxygen, discontinuing nitrous oxide
- Positioning the patient in Trendelenburg position,
- Providing cardiac support as necessary.<sup>35</sup>

### Infection

- Most CI surgeons use prophylactic antibiotics that should be given intravenously before the first incision.

## Intraoperative Considerations

*Facial nerve preservation:* Preservation of facial nerve is an important step. The facial nerve may be identified intraoperatively by electrical stimulation thus precluding the use of muscle relaxants. This should be used after the effect of the muscle relaxant used for intubation has weaned off as assessed by the response on the train of four stimulation and during this process the anesthesia can be maintained by propofol infusion.<sup>1</sup> An injection of steroid is given to prevent edema of the facial nerve.

*Use of electrocautery:* Cochlear implant is an electrical device, thus can easily be damaged by static electrical

discharges from electrocautery. Thus, the use of electrocautery should be discouraged once the CI is inserted in place. However, proper hemostasis should be done before placement of CI. At the conclusion of surgery, the integrity of the implant is checked by brainstem auditory evoked responses and by electrically evoked stapedius reflexes. This is very essential for postoperative fitting of external speech processor which may be difficult in small children postoperatively.

*Fluid management:* The surgical duration is usually of less than 4 hours with no significant blood loss. However, sometimes significant blood loss may occur from large noncollapsible mastoid emissary veins. Adequate blood volume is maintained by infusion of crystalloids compensating for fasting and blood losses. Large amounts of fluids should be avoided as it can lead to bladder distension leading to postoperative agitation as usually catheterization is not done in these surgeries. *Smooth recovery:* Sudden coughing and bucking should be avoided at the end of surgery to prevent dislodgement of the electrode array of the implant. The neuromuscular blockade should be reversed and spontaneous respiratory efforts are allowed. The child can be extubated in deeper planes and kept in lateral recovery position to prevent sudden agitation. The child should be monitored in postanesthesia care unit (PACU) in presence of the parents with proper postoperative analgesia.

## POSTOPERATIVE MANAGEMENT

### Prevention of PONV

The various measures employed are:

- Avoidance of nitrous oxide
- Administration of antiemetics
  - Ondansetron 0.1 mg/kg intravenously at the end of surgery
  - Dexamethasone 0.15 mg/kg intravenously at the beginning of surgery
  - Palonosetron, an efficacious antiemetic drug which has got a long duration of action.<sup>36</sup>

### Postoperative Analgesia

- Controlled boluses of opioids like fentanyl or morphine.
- Intravenous or per rectal paracetamol, to prevention of opioid-related side-effects.<sup>37,38</sup>

The patient should be monitored in PACU till the consciousness is regained fully with minimal PONV.

### Complications

The cochlear implant surgery is considered to be relatively safe with minimal or no anesthesia-related complications are reported.

## Early surgical complications

### Minor

- Change in taste
- Minor balance problems
- Transient facial palsy
- Mild flap infection

### Major

- Cerebrospinal leak
- Persistent facial palsy
- Meningitis
- Device failure
- Device migration
- Flap necrosis.<sup>39,40</sup>

## Late Surgical Complications

- Displaced magnet from the receiver pocket by magnetic toys<sup>41</sup>
- Silicone allergy
- Requirement of reimplantation can occur late and are less frequent and thus these patients should be followed for long-term.<sup>42</sup>

Anesthesia considerations for incidental surgery in patients with CI

- Avoid electrocautery
  - The electrical interference caused by electrocautery
  - Monopolar cautery should be avoided near head and neck areas
  - Even the bipolar cautery should be avoided directly over the extracochlear electrodes to avoid damage.
- Avoid use of electroconvulsive therapy
- Avoid use of radiotherapy directly over the implant
- Magnetic resonance imaging (MRI) is contraindicated
  - Can lead to tissue damage and implant migration.
  - However, if MRI is deemed to be necessary, the external magnet can be removed by a minor surgery, and thus MRI can be performed and the magnet can be replaced postprocedure.<sup>43</sup>

## CONCLUSION

In conclusion, with careful patient selection, local anesthesia with sedation is a good alternative to general anesthesia for simple middle ear surgery. General anesthesia provides a better recovery profile and less nausea and vomiting. Special considerations are a bloodless surgical field, attention to patient's head positioning, airway management, facial nerve monitoring, the effect of nitrous oxide on the middle ear, a smooth and calm recovery, and prevention of PONV.

The cochlear implantation surgery has gained popularity over the last decade and thus the attending anesthesiologist is faced with the responsibility of safely conducting the surgery. The anesthetic techniques have

implications on the method of stimulation of the facial nerve in CI. Moreover, most of these patients are children and it is the responsibility of anesthesiologist to prevent an agitation and smooth induction and emergence from anesthesia. A close cooperation between the anesthesiologist and surgeon is essential for a positive outcome.

## REFERENCES

1. Available at: <http://emedicine.medscape.com/article/82698-overview>.
2. Moore KL, Dalley AF. Clinically orientated anatomy. 4th ed. Philadelphia: Lippincott Williams and Wilkins; 1999; 967-971.
3. Deacock AR. Aspects of anaesthesia for middle ear surgery and blood loss during stapedectomy. Proc R Soc Med 1971; 64(12):1226-1228.
4. Liang S, Irwin MG. Review of anesthesia for middle ear surgery. Anesthesiol Clinics 2010 Sep;28(3):519-528.
5. Caner G, Olgun L, Gültekin G, Aydar L. Local anesthesia for middle ear surgery. Otolaryngol Head Neck Surg 2005 Aug;133(2):295-297.
6. Miller RD. Miller's anesthesia. 6th ed. Hershey (PA): Elsevier Churchill Livingstone; 2005; vol. 2. 2548-2549.
7. Bailey CR. Management of outpatient ear, nose and throat surgery. Curr Opin Anaesthesiol 2001;14(6):617-621.
8. Paul BG, Bruce CF, Robert SK. Clinical anesthesia. 5th ed. 2006. p. 2076-2078.
9. Vladimir N. Anesthesia for otologic and neurotologic surgery, anesthesia for otolaryngologic surgery. Ed. Basem Abdelmalak and John Doyle. 1st ed. Cambridge: Cambridge University Press, 2012. pp. 271-296. Cambridge Books Online. Web. 18 October 2015. Available at: <http://dx.doi.org/10.1017/CBO9781139088312.032>
10. Degoute CS. Controlled hypotension: a guide to drug choice. Drugs 2007;67(7):1053-1076.
11. Thota RS, Ambardekar M. Priyamvada likhate conscious sedation for middle ear surgeries: a comparison between fentanyl-propofol and fentanyl-midazolam infusion 2015;9(2):117-121.
12. Benedik J, Manohin A. Sedation for middle ear surgery: prospective clinical trial comparing propofol and midazolam. Cent Eur J Med 2008;3(4):487-493.
13. Casey WF, Drake-Lee AB. Nitrous oxide and middle ear pressure. A study of induction methods in children. Anaesth 1982 Sept;37(9):896-900.
14. Morgan EG, Mikhail MS, Murray MJ. Clinical anesthesiology. 4th ed. New York: Lange Medical Books/McGraw-Hill; 2006. p. 845-847.
15. Majstorović BM, Radulović RB, Dukić VB, Kastratović DA, Popović NP, Gajić MM. Effects of nitrous oxide on middle ear pressure. Med Pregl 2007 Sep-Oct;60(9-10):473-478.
16. Glasscock-Shambaugh Surgery of the Ear. 5th ed; 2003. p. 482-483.
17. Bajwa SS, Kulshrestha A. The cochlear implantation surgery: a review of anesthetic considerations and implications. Int J Health Allied Sci (serial online) 2013 (cited 2015 Apr 25);2: 225-229.
18. National Institute on Deafness and Other Communication Disorders. Cochlear implants (NIH Pub. No. 11-4798). Bethesda, MD: National institute on deafness and other communication disorders. National Institutes of Health; 2011.



19. Orabi AA, Mawman D, Al-Zoubi F, Saeed SR, Ramsden RT. Cochlear implant outcomes and quality of life in the elderly: Manchester experience over 13 years. *Clin Otolaryngol* 2006;31(2):116-122.
20. Lassaletta L, Castro A, Bastarrica M, de Sarriá MJ, Gavilán J. Quality of life in postlingually deaf patients following cochlear implantation. *Eur Arch Otorhinolaryngol* 2006;263(3):267-270.
21. Pedersen CB, Jochumsen U, Madsen S, Koefoed-Nielsen B, Johansen LV. Results and experiences with 55 cochlear implantations. *Ugeskr Laeger* 2000;162:5346-5350.
22. National institute on deafness and other communication disorders. Presbycusis (NIH Pub. No. 97-4235). Bethesda, MD: National Institute on Deafness and Other Communication Disorders, National Institutes of Health; 1997.
23. Huang Q, Tang J. Age-related hearing loss or presbycusis. *Eur Arch Otorhinolaryngol* 2010;267(8):1179-1191.
24. Connor CM, Craig HK, Raudenbush SW, Heavner K, Zwolan TA. The age at which young deaf children receive cochlear implants and their vocabulary and speech-production growth: Is there an added value for early implantation? *Ear Hear* 2006 Dec;27(6):628-644.
25. Green JD, Schuh MJ, Maddern BR, Haymond J, Helffrich RA. Cochlear implantation in Jervell and Lange-Nielsen syndrome. *Ann Otol Rhinol Laryngol Suppl* 2000 Dec;185:27-28.
26. Trimble K, Blaser S, James AL, Papsin BC. Computed tomography and/or magnetic resonance imaging before paediatric cochlear implantation? Developing an investigative strategy. *Otol Neurotol* 2007 Apr;28(3):317-324.
27. Djalilian HR, Roy S, Benson AG, Regala C, McDonald TB, Leman T. Transcanal cochlear implantation under monitored anesthesia care. *Otol Neurotol* 2005;26(4):674-677.
28. Hamerschmidt R, Mocellin M, Gasperin AC, et al. Local anesthesia for cochlear implant surgery: a possible alternative. *Braz J Otorhinolaryngol* 2010;76(5):561-564.
29. Cox RG, Nemish U, Ewen A, Crowe MJ. Evidence-based clinical update: does premedication with oral midazolam lead to improved behavioural outcomes in children? *Obstetrical and Pediatric Anesthesia*. *Can J Anaesth* 2006 Dec;53(12):1213-1219.
30. Cunningham CD 3rd, Slattery WH 3rd, Luxford WM. Postoperative infection in cochlear implant patients. *Otolaryngol Head Neck Surg* 2004;131(1):109-114.
31. Hirsch BE, Blikas A, Whitaker M. Antibiotic prophylaxis in cochlear implant surgery. *Laryngoscope* 2007;117(5):864-867.
32. Bajwa SS, Kaur J, Singh A, Parmar SS, Singh G, Kulshrestha A, et al. Attenuation of pressor response and dose sparing of opioids and anaesthetics with preoperative dexmedetomidine. *Ind J Anaesth* 2012 Mar-Apr;56(2):123-128.
33. Dillon FX. Electromyographic (EMG) neuromonitoring in otolaryngology-head and neck surgery. *Anesthesiol Clin* 2010;28(3):423-442.
34. Wootten CT, Backous DD, Haynes DS. Management of cerebrospinal fluid leakage from cochleostomy during cochlear implant surgery. *Laryngoscope* 2006;116(11):2055-2059.
35. Palmon SC, Moore LE, Lundberg J, Toung T. Venous air embolism: a review. *J Clin Anesth* 1997;9(3):251-257.
36. Bajwa SS, Bajwa SK, Kaur J, Sharma V, Singh A, Singh A, et al. Palonosetron: a novel approach to control postoperative nausea and vomiting in day care surgery. *Saudi J Anaesth* 2011 Jan;5(1):19-24.
37. Czarnecki ML, Ferrise AS, Jastrowski Mano KE, Garwood MM, Sharp M, Davies H, et al. Parent/nurse-controlled analgesia for children with developmental delay. *Clin J Pain* 2008 Nov-Dec;24(9):817-824.
38. Czarnecki ML, Salamon KS, Jastrowski Mano KE, Ferrise AS, Sharp M, Weisman SJ. A preliminary report of parent/nurse-controlled analgesia (PNCA) in infants and preschoolers. *Clin J Pain* 2011 Feb;27(2):102-107.
39. Komazec Z, Lemajic-Komazec S, Dankuc D, Vlaski L. Cochlear implantation-risk and complications. *Med Pregl* 2008;61:27-30.
40. Bhatia K, Gibbin KP, Nikolopoulos TP, O'Donoghue GM. Surgical complication and their management in a series of 300 consecutive paediatric cochlear implantations. *Otol Neurotol* 2004 Sept;25(5):730-739.
41. Wild C, Allum J, Probst R, Abels D, Fischer C, Bodmer D. Magnet displacement: a rare complication following cochlear implantation. *Eur Arch Otorhinolaryngol* 2010 Jan;267(1):57-59.
42. Venail F, Sicard M, Piron JP, Levi A, Artieres F, Uziel A, et al. Reliability and complications of 500 consecutive cochlear implantations. *Arch Otolaryngol Head Neck Surg* 2008 Dec;134(12):1276-1281.
43. Chakrabarty A, Tarneja VK, Singh Adm VK, Roy PK, Bhargava AK, Sreevastava DK. Cochlear implant: anaesthesia challenges. *Armed Forces Med J India* 2004 Oct;60(4):351-356.