

## CASE REPORT

# Glial Heterotopia of Sphenoid in Association with a Patent Sternberg's Canal presenting with Meningitis

<sup>1</sup>R Suma, <sup>2</sup>KJ Jeena, <sup>3</sup>VM Pavithran, <sup>4</sup>A Govindan, <sup>5</sup>K Ramachandran

## ABSTRACT

Ectopic glial tissue, presenting at various sites of body is a rare embryonic developmental anomaly. Very few cases are reported in adults, most being incidentally detected, revealed only by histopathological findings. One of the rarest locations is the sphenoid sinus.

We present here the case of a middle aged female, presenting with spontaneous cerebrospinal fluid (CSF) rhinorrhea and meningitis. With the radiological finding of a soft tissue density in sphenoid sinus with erosion of left temporal skull base, she underwent lateral craniotomy, with excision of the mass and middle cranial fossa floor repair. Histopathology revealed a heterotopic glial tissue. Peroperative finding of a well-defined defect in the lateral wall of an extensively pneumatized sphenoid showed typical features of a patent Sternberg's canal.

This case could be a living proof for the existence of this rare developmental anomaly. A persisting Sternberg's canal should be considered as the source of spontaneous CSF leaks with or without lesions in sphenoid sinuses with extensive lateral pneumatization. Most of the cases may be treated with an extended endoscopic approach. Extreme lateral lesions like this would benefit most from a craniotomy approach for proper closure of skullbase defect. Three years after successful surgery, she remains symptom free.

**Keywords:** Glial heterotopia, Sternberg's canal, Spontaneous CSF rhinorrhea and meningitis.

**How to cite this article:** Suma R, Jeena KJ, Pavithran VM, Govindan A, Ramachandran K. Glial Heterotopia of Sphenoid in Association with a Patent Sternberg's Canal presenting with Meningitis. *Int J Otorhinolaryngol Clin* 2014;6(2):81-83.

**Source of support:** Nil

**Conflict of interest:** None

## INTRODUCTION

Glial heterotopia is a mass of mature brain tissue found isolated from the cranial cavity or spinal canal.<sup>1</sup> Most cases present as mass lesions along the central region of the face,

inside or near the nasal cavity.<sup>2</sup> Most of the cases described in the literature have occurred in patients in the first year of life. Presentation in later life may be due to traumatic or other acquired bony defects or due to a missed congenital lesion. These tumors have slow growth. Skull defects are reported to be unusual.<sup>3</sup> The most important factor that determines the management is its location and persistence of intracranial connection. Timely intervention saves the life of the patient.

## CASE REPORT

A 42-year-old female presented with unilateral profuse watery nasal discharge. As there was no history of preceding trauma or fever, she was being treated for rhinitis, without relief for 2 weeks from a peripheral hospital. And since the symptom appeared only while stooping forward, the patient was not very much concerned. Meanwhile she developed fever, headache, nausea and vomiting, and was immediately subjected to blood investigations and lumbar puncture, which revealed an elevated total white blood cell (WBC) count, with predominant neutrophils. She was referred to our ENT department as a case of cerebrospinal fluid (CSF) rhinorrhea with acute bacterial meningitis.

A high resolution computerized tomographic scan of skull base and paranasal sinus (PNS) revealed a soft tissue density lesion with a fluid level, in the left sphenoid sinus. There was extensive pneumatization of sphenoid extending laterally and there was erosion of adjacent temporal skull base (Fig. 1). She was started on broad spectrum antibiotics and put on measures to reduce CSF leak but there were no signs of spontaneous remission.

Magnetic resonance imaging with contrast revealed an expansile lytic lesion in the root of greater wing of sphenoid with minimal postcontrast enhancement (Fig. 2). The lesion extended up to lateral wall of orbit and hence inaccessible for endoscopic biopsy. At this point, we considered the probabilities of an invasive fungal sinusitis, osseous neoplasm, a chronic granulomatous disease, and even a meningocele. The skull base erosion called for a neurosurgical opinion, who suggested that a lateral craniotomy approach was better than endoscopic because of the uncertainty of diagnosis and its extent though we usually adopt endoscopic approach for closure of skull base defects.

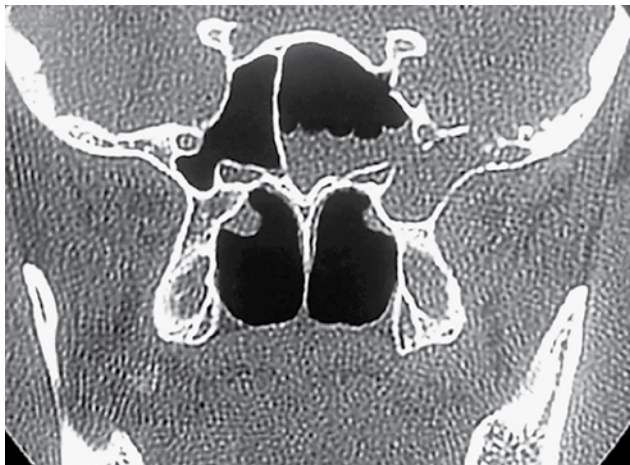
<sup>1,3</sup>Associate Professor, <sup>2</sup>Junior Resident, <sup>4</sup>Assistant Professor  
<sup>5</sup>Professor and Head

<sup>1,2,5</sup>Department of ENT, Government Medical College  
Kozhikode, Kerala, India

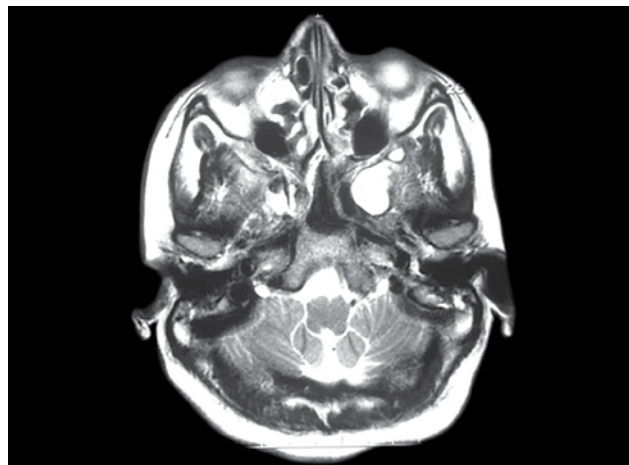
<sup>3</sup>Department of Neurosurgery, Government Medical College  
Kozhikode, Kerala, India

<sup>4</sup>Department of Pathology, Government Medical College  
Kozhikode, Kerala, India

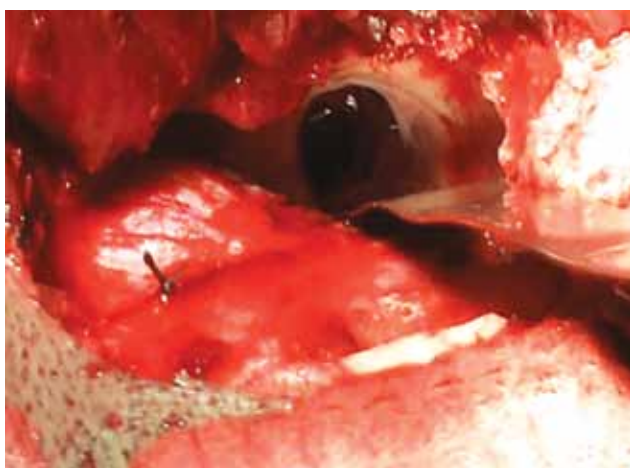**Corresponding Author:** R Suma, Associate Professor, Department of ENT, Government Medical College, Kozhikode, Kerala, India  
Phone: 91-9447158969, 04952358969, e-mail: drsumavijay@gmail.com



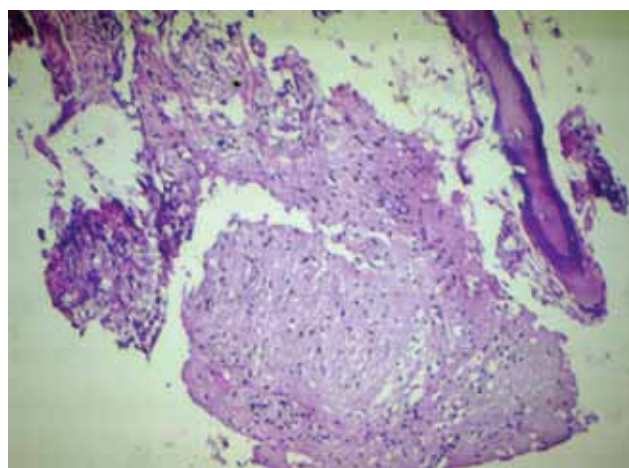
**Fig. 1:** HRCT showing soft tissue density in well-pneumatized sphenoid sinus with erosion of skull base



**Fig. 2:** MRI showing lesion in root of greater wing of sphenoid and lateral wall of orbit



**Fig. 3:** Defect in lateral recess of sphenoid sinus, as seen on retracting temporal lobe, after removal of mass



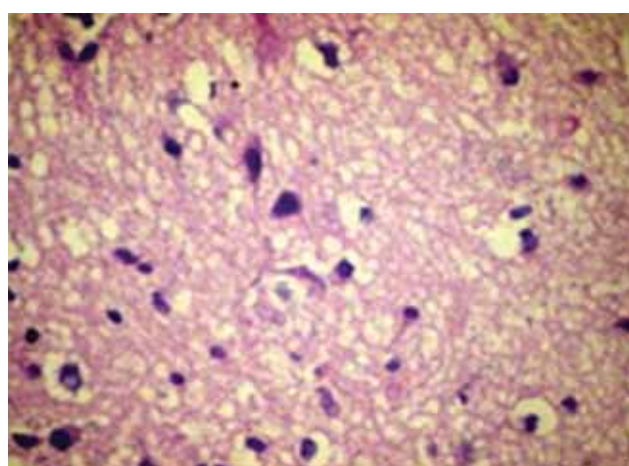
**Fig. 4:** Heterotopic glial tissue beneath the sinus mucosa (H&E, 100x)

She underwent a left temporal craniotomy under general anesthesia. As soon as the temporal lobe was retracted, a large bony defect appeared in the lateral wall of sphenoid sinus, which contained a polypoidal mass separate from the sinus mucosa and meninges. The mass was removed completely and cavity inspected thoroughly, but there was no mucosal involvement. The adjacent dura was slit open to make sure if there were any intracranial pathology, but was found normal. Dura was closed watertight. The sphenoid sinus defect was plugged with fat harvested from thigh and reinforced with fascia lata, and further sealed with fibrin glue (Fig. 3). Post-operative period was uneventful.

The histopathological examination of specimen showed heterotopic glial tissue with neurons, astrocytes and oligodendrocytes (Figs 4 and 5). The patient is on regular follow-up and remains symptom free, 3 years after surgery.

## REVIEW OF LITERATURE WITH DISCUSSION

Heterotopic central nervous system tissue (HCNST) is non-cancerous neuroglial tissue occurring at extracranial



**Fig. 5:** Glial tissue showing neurons, astrocytes and oligodendrocytes (H&E, 400x)

sites, usually along the central region of the face, inside or near the nasal cavity. They are generally present at birth or diagnosed in early childhood. These are thought to originate as protrusions of neuroglial tissue from the developing brain or spinal cord that become isolated during maturation

of the neuraxis.<sup>2</sup> Intracranial extensions can rarely occur through skull base fissures. One constant feature is that there is usually no communication between the heterotopic glial tissue and the adjacent brain or spinal cord. This differentiates it from an encephalocele. The difference between nasal glial heterotopias and encephalocele has not yet been clarified pathologically. Imaging studies are required before excision to differentiate these two entities.<sup>1,4</sup> Apart from presentations as nasal or extranasal mass, rare locations like lips, tongue, scalp, nasopharynx, orbit, paranasal sinuses, middle ear and oropharynx have been reported. Other uncommon sites noted are, intrapulmonary and intraperitoneal.<sup>5</sup> Exact incidence is unknown. Histology shows fibrous tissue with a considerable number of small vessels, astrocytes, oligodendrocytes and occasional neurons. Immunohistochemistry stain positive for S100 and glial fibrillary acid protein.<sup>6-8</sup> Treatment is complete removal via a functional surgical approach, either endoscopic trans-ethmoidal-pterygoid-sphenoidal approach or as in this case a lateral craniotomy approach, depending upon the extent of lesion.<sup>9</sup>

Heterotopic glial tissues in PNS have been extremely rare, most cases being reported from ethmoids. After extensive search in English literature, we could find a single similar case report of a 56-year-old man, who presented with CSF rhinorrhea and had heterotopic glial tissue in the sphenoid sinus.<sup>10</sup>

What puzzled us further was the peroperative finding of a well-defined anatomical defect in the lateral wall of sphenoid sinus. Our search for the abnormal foramina of skull base showed us an anatomical entity called Sternberg's canal (craniopharyngeal canal) described by Sternberg in 1888. It is described as a defect in the lateral wall of the sphenoid sinus, seen between the maxillary division of cranial nerve V and Vidian N. It is usually associated with extensive pneumatization of sphenoid into the greater wing. Cases usually present with spontaneous cerebrospinal fluid (CSF) leaks. A patent Sternberg's canal is found in about 4% of adults.

Heterotopic glial tissue in the sphenoid sinus presents a surgical challenge to ENT surgeon. Its presentation as CSF rhinorrhea and meningitis poses significant morbidity. A persisting Sternberg's canal should be considered the source of spontaneous CSF leaks with or without meningo-

encephalocele in sphenoid sinuses with extensive lateral pneumatization, especially when located laterally and below the maxillary nerve. Even though an ENT surgeon would be prompted for an endoscopic approach, a neurosurgical opinion should always be called for. A careful search for any skull base defect and its early correction can offer a permanent cure for the patient. Multilayered reconstruction of the skull base defects must be considered the first option for these kinds of lesion. This case could be a living proof for the possible existence of Sternberg's canal. This is also a case where spontaneous CSF rhinorrhea could have been misdiagnosed as simple rhinitis. This is also the first reported case of glial heterotopias of sphenoid sinus with patent Sternberg's canal, which has been treated successfully. We believe this case report would benefit future patients with similar pathology.

## REFERENCES

1. Chan JK, Lau WH. Nasal astrocytoma or nasal glial heterotopia? Arch Pathol Lab Med 1989;113(8):943-945.
2. Altissimi G, Ascani S, Falcetti S, et al. Central nervous system tissue heterotopia of the nose: case report and review of the literature. ACTA Otorhinolaryngologica Italica 2009;29(4): 218-221.
3. Batsakis JG. Tumours of the head and neck: clinical and pathological considerations; 2nd edn. Williams and Wilkins Co, Baltimore; 1979. p. 16.
4. Kardon DE. Nasal glial heterotopia. Arch Pathol Lab Med 2000 Dec;124(12):1849.
5. Mohanty S, Das K, Correa MA, Cruz AJ. Extranasal glial heterotopia: case report. Neurology India 2003;51(2):248-249.
6. Burger PC, Scheithauer BW. Tumors of the central nervous system. AFIP Atlas of tumor pathology. Series 4. Washington, DC: American Registry of Pathology; 2007. p. 492-493.
7. Cerdà-Nicolàs M, Sanchez Fernandez de Sevilla C, Lopez-Ginés C, et al. Nasalglioma or nasal glial heterotopia? Morphological immunohistochemical and ultrastructural study of two cases. Clin Neuropathol 2002 Mar-Apr;21(2):66-71.
8. Penner CR, Thompson L. Nasal glial heterotopia: a clinico-pathologic and immunophenotypic analysis of 10 cases with a review of the literature. Ann Diagn Pathol 2003;7(6): 354-359.
9. Castelnuovo P, Dallan I, Pistochini A, et al. Endonasal endoscopic repair of Sternberg's canal cerebrospinal, fluid leaks. Laryngoscope 2007;117(2):345-349.
10. Ha Nguyen Chau, Hopkins C, McGilligan A. A rare case of nasal glioma in the sphenoid sinus of an adult presenting with meningioencephalitis. Eur Archives of Otorhinolaryngol 2005; 262(7):592-594.