

CASE REPORT

Skull Base Osteomyelitis Resulting in Petrous Internal Carotid Aneurysm

¹R Suma, ²Vijeyta Dahiya, ³R Chandni, ⁴Ellezhuthil Devarajan, ⁵K Ramachandran

ABSTRACT

Skull base osteomyelitis typically occurs most often as a complication of malignant otitis externa secondary to pseudomonas infection. Common risk factors are increasing age, diabetes mellitus and immunosuppression. If it happens in the absence of external otitis it is called atypical or central type. Medical management is the mainstay of treatment. Surgical management is for a diagnostic biopsy and in some for debridement. Described below is a case report of a 75 years old male patient who was diagnosed to have skull base osteomyelitis and was started on intravenous antibiotics. Following an initial improvement of symptoms, after 4 weeks he developed ear and oropharyngeal bleed. Imaging revealed a massive aneurysm of petrous internal carotid artery with multiple brain infarcts and before we could intervene the patient expired. This case emphasizes a rarity in skull base osteomyelitis and the need for early diagnosis and aggressive treatment.

Keywords: Skull base osteomyelitis, Petrous internal carotid artery aneurysm, Balloon occlusion test, Diabetes mellitus.

How to cite this article: Suma R, Dahiya V, Chandni R, Devarajan E, Ramachandran K. Skull Base Osteomyelitis Resulting in Petrous Internal Carotid Aneurysm. *Int J Otorhinolaryngol Clin* 2014;6(2):71-73.

Source of support: Nil

Conflict of interest: None

INTRODUCTION

Typical skull base osteomyelitis occurs most often as a complication of malignant otitis externa secondary to pseudomonas infection.¹ Skull base osteomyelitis is an aggressive inflammation of bones and soft tissues at the base of skull that requires prompt diagnosis and aggressive management. It occurs mainly in patients with diabetes or immunocompromised conditions. It may occur following

external otitis or sometimes without ear infection. The latter called central or atypical² skull base osteomyelitis presents by headache and cranial nerve palsies and continues to be a clinical challenge for early diagnosis. Long hospital stay is needed for intravenous antibiotics therapy and control of diabetes. Follow-up is important to assess the response to treatment. Imaging in the form of CT and MRI is the initial investigation. The best imaging for prognosis is gallium scan. In unresponsive cases the fungal cause has to be excluded. So, the biopsy material should also be sent for microbiological examination for fungus. Petrous Internal carotid artery aneurysm associated with skull base osteomyelitis is a very rare complication. The only sign may be an ear bleed or epistaxis.³ Rupture of aneurysm leads to seizures and focal neurological signs. This needs evaluation by angiography and usually requires endovascular surgeries. We report the present case because of its rarity and the need for early diagnosis and prompt treatment.

CASE REPORT

Seventy-five years-old male was admitted in medical ward for altered sensorium which was thought to be due to hyponatremia and uncontrolled diabetes. The patient was sent to Otorhinolaryngology department for right sided purulent ear discharge and severe earache of 4 months duration. He also gave history of facial deviation to left side for 1 month (Fig. 1). We transferred the patient to otorhinolaryngology department suspecting malignant otitis externa. Right ear examination showed classical granulations at bony-cartilaginous junction of external auditory canal. There was right facial palsy and palatal palsy. High resolution CT (Fig. 2) temporal bone showed a soft tissue density completely filling the right external auditory canal, middle ear cavity, aditus, mastoid antrum and second genu of facial nerve. There was erosion of floor of external auditory canal, promontory, petrous apex and jugular fossa with possible involvement of lower cranial nerves (Fig. 3). Blood investigations showed low hemoglobin, normal total and differential count and very high ESR (110 mm/1st hour). C-reactive protein was positive (1.2 mg/l) and diabetic status uncontrolled with HbA1C of 7.43%. Ear swab was sterile. Examination under microscope revealed granulations and small central perforation in tympanic membrane. Biopsy of granulations

¹Associate Professor, ²Junior Resident, ³Additional Professor
⁴Professor, ⁵Professor and Head

^{1,2,5}Department of ENT, Government Medical College, Calicut Kerala, India

³Department of Medicine, Government Medical College, Calicut Kerala, India

⁴Department of Radiodiagnosis, Government Medical College Calicut, Kerala, India

Corresponding Author: R Suma, Associate Professor Department of ENT, Government Medical College, Calicut Kerala, India, e-mail: drsumavijay@gmail.com

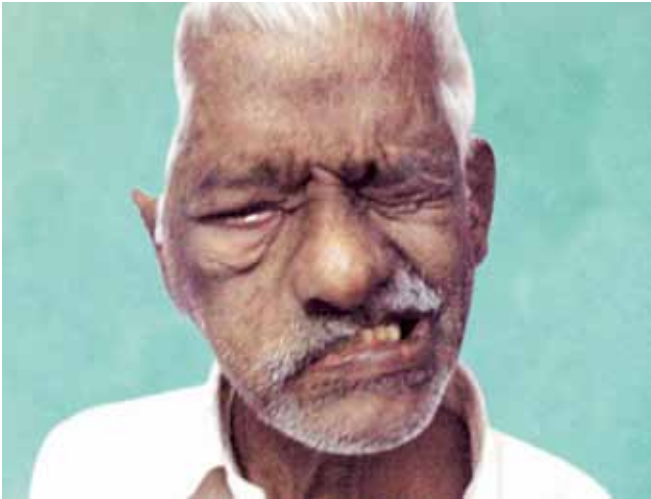

Fig. 1: Patient with right facial palsy

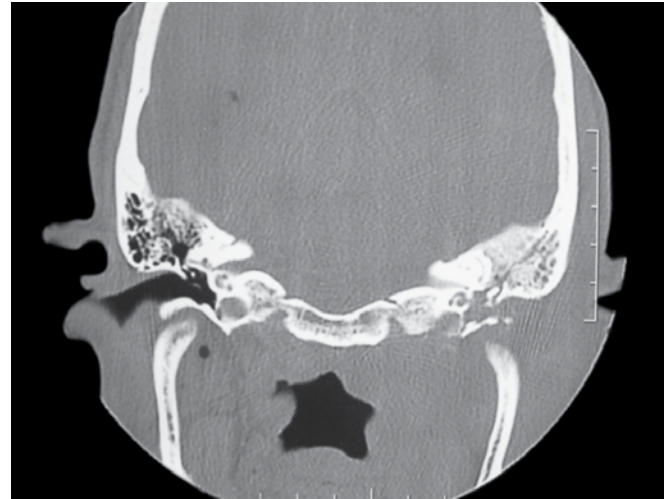

Fig. 2: HRCT temporal bone coronal showing soft tissue density right EAC, destruction of tympanic part of temporal bone and soft tissue thickening skull base

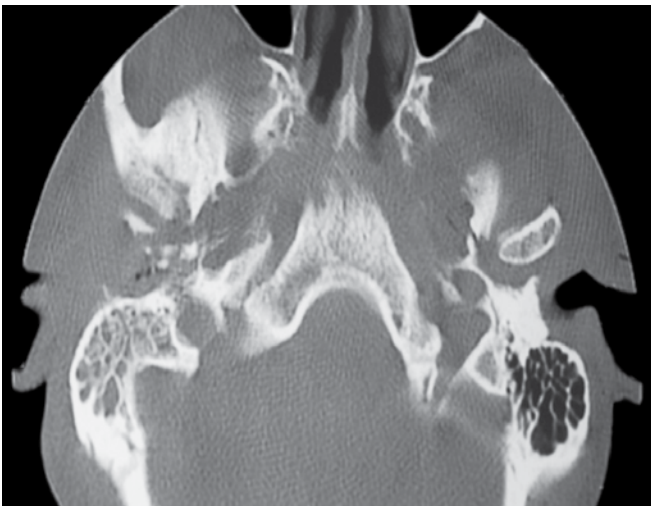


Fig. 3: HRCT axial showing involvement of petrous apex with bone destruction around lower part of carotid canal

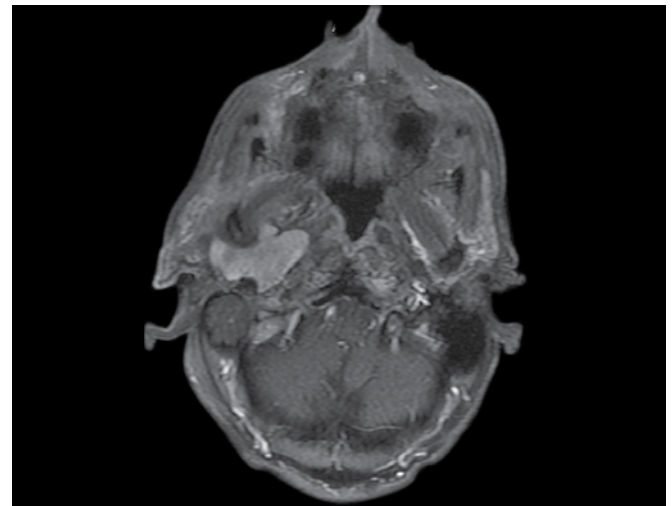


Fig. 4: MRI brain axial T1 contrast showing massive right petrous ICA aneurysm

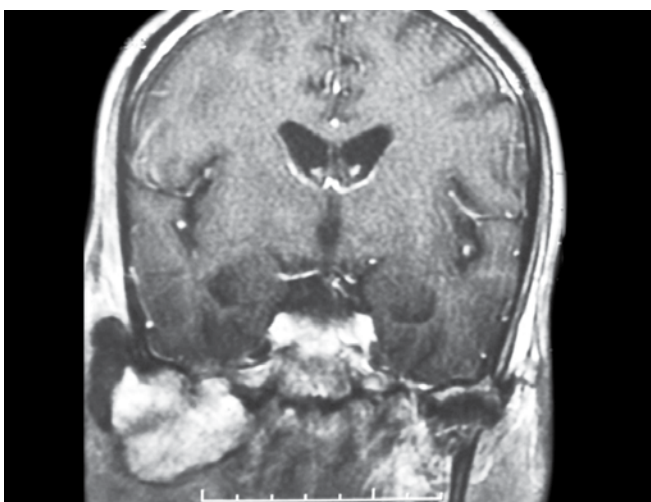


Fig. 5: MRI T1 contrast coronal view showing large right ICA aneurysm

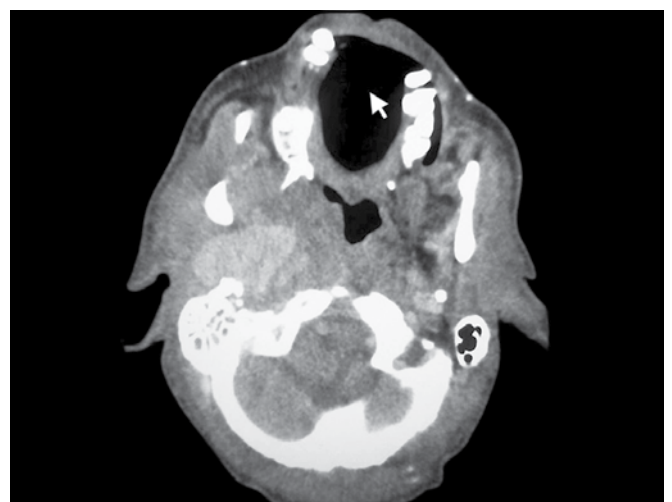


Fig. 6: Repeat CT contrast showing large pseudoaneurysm

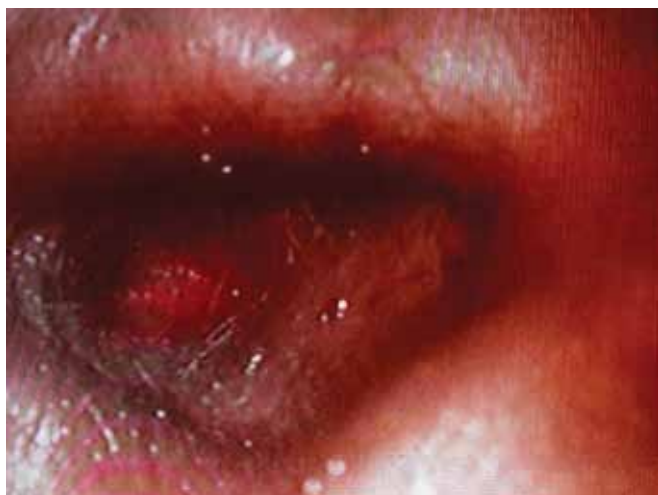

Fig. 7: Right EAC showing pulsating ICA

was inconclusive. Patient was treated with broad spectrum antibiotics and insulin. There was improvement in sensorium and ear symptoms.

Four weeks after admission the patient developed two episodes of oropharyngeal and right ear bleed. He also developed swaying to right side with evidence of right cerebellar dysfunction. ESR and CRP were raised further. MRI brain with contrast (Figs 4 and 5) revealed an irregular expansile altered signal intensity of about $3.3 \times 4 \times 3.3$ cm in right infratemporal fossa with a nipple directed toward anterior wall of petrous internal carotid artery. The lesion was hypointense in T1 and hyperintense in T2 with central signal voids and uniform postcontrast enhancement. It was extending from skull base to C2 level and bulging into external auditory canal. Bone destruction noted in carotid canal, adjacent sphenoid, glenoid fossa, middle ear and external auditory canal. In addition, there were multiple infarcts in supratentorial and infratentorial brain parenchyma due to septic emboli. Results were confirmed by CT also (Fig. 6). We repeated examination under microscope which revealed a reddish pulsating mass in right external auditory canal which was not there before in previous examinations (Fig. 7). That was the pulsating petrous internal carotid artery. We planned for digital subtraction angiography followed by internal carotid artery ligation in view of massive aneurysm in association with neurosurgery department, but before we could do anything the patient succumbed to the illness.

REVIEW OF LITERATURE WITH DISCUSSION

Skull base osteomyelitis is a very aggressive skull base infection and is marked by a fluctuating course. This highlights the importance of repeat imaging to assess the response. CT and MRI both are required as initial imaging of choice but they are not suitable for prognosis as the findings

remain positive for many months.⁴ Technitium⁹⁹ is very sensitive to detect early disease but not specific. Gallium⁶⁷ scan is very specific and is recommended for follow-up. Cultures may be sterile due to previous use of multiple local antibiotics before the diagnosis is made. Biopsies should be sent both for pathological and microbiological examination.

Petrous internal carotid artery aneurysms are very rarely associated with Skull base osteomyelitis. They are usually pseudoaneurysms⁵ with very thin wall. Ear bleed or oropharyngeal bleed in such patients is a warning sign for underlying aneurysm and should be evaluated. Imaging with angiography is the initial investigation for diagnosis. Endovascular surgeries are the mainstay of treatment. They are preceded by digital subtraction angiography to assess brain circulation and collaterals. Preoperative balloon occlusion test is done before occluding the internal carotid artery. Here a small catheter with nondetachable silicon balloon is introduced through the femoral artery into the internal carotid artery and inflated to block the flow. Patient is tested for hand grip, foot movements, language and facial expression. If there are good collaterals, there would not be any brain dysfunction. If there are no collaterals, patient will experience weakness of limbs or difficulty in speaking. Balloon is usually kept for 30 minutes and then removed. Occlusion is done by latex balloons and platinum coils.

Even though we could not intervene in our patient, this case highlights the importance of early diagnosis. Also this rare entity should be kept in mind whenever we are evaluating a patient with extensive skull base osteomyelitis with lesions close to internal carotid artery.

CONCLUSION

Important aspect of the management of Skull base osteomyelitis is the repeat imaging to assess the response to treatment and to detect the complications early. Petrous internal carotid artery aneurysm is a rare complication and the only way to save the patient is by early diagnosis and prompt treatment.

REFERENCES

1. Chandler JR. Malignant external otitis and osteomyelitis of base of skull. *Am J Otol* 1989 March;10(2):108-110.
2. Grobman LR, Ganz W, Casiano R, Goldberg S. Atypical osteomyelitis of the skull base. *Laryngoscope* 1989;99(7):671-676.
3. Constantino PD, Russel E, Reisch D, Breit RA, Hart C. Ruptured petrous carotid aneurysm presenting with otorrhagia and epistaxis. *Am J Otol* 1991;12(9):378-383.
4. Patrick JT. Magnetic resonance imaging of petrous carotid aneurysms. *J Neuroimaging* 1996;6(7):177-179.
5. Sedwitz MM, Hye RJ, Stabile BE. The changing epidemiology of pseudoaneurysm. *Arch Surg* 1988;123(4):473-476.