

CASE REPORT

A Rare Case of Rhinofacial Zygomycosis due to *Conidiobolus* Infection

¹Arunabha Chakravarti, ²Meenakshi Mishra

ABSTRACT

Background: Rhinofacial zygomycosis is the infection of subcutaneous tissues of maxillofacial region caused by zygomycetes class of fungi. It is commonly caused by the order mucorales and is acute and fulminant. Infections by the order entomophthorales are rare but indolent.

Case report: We report an unusual case of rhinofacial zygomycosis due to *Conidiobolus coronatus* of the order Entomophthorales in an immunocompetent adult male to highlight the clinical presentation, diagnosis and treatment. We treated the patient with multiple drugs, that is amphotericin-B, cotrimoxazole, and itraconazole along with endoscopic debridement of nasal polyps with excellent result.

Conclusion: Rhinofacial zygomycosis due to entomophthorales is rare but treatable condition. Appropriate histopathological diagnosis and a multipronged approach with timely medical as well as surgical management is the key to clinical cure.

Keywords: Rhinofacial zygomycosis, *Conidiobolus coronatus*, Entomophthorales, Mucorales.

How to cite this article: Chakravarti A, Mishra M. A Rare Case of Rhinofacial Zygomycosis due to *Conidiobolus* Infection. Int J Otorhinolaryngol Clin 2014;6(2):65-67.

Source of support: Nil

Conflict of interest: None

INTRODUCTION

Zygomycetes class of fungi is divided into two orders—entomophthorales and mucorales.¹⁻³ Infections caused by entomophthorales are rare, and are known to be indolent, chronic, associated with granulomatous inflammation and a protracted clinical course. Entomophthorales comprises of two species, namely conidiobolus and basidiobolus. *Conidiobolus* species generally causes rhinofacial zygomycosis which is a chronic granulomatous infection of nose and face. We present here a case of rhinofacial zygomycosis in a healthy adult male caused by *conidiobolus coronatus*.

¹Professor, ²Senior Resident

^{1,2}Department of ENT, Lady Hardinge Medical College New Delhi, India

Corresponding Author: Meenakshi Mishra, Senior Resident Department of ENT, Lady Hardinge Medical College, New Delhi India, Phone: 09833625464, e-mail: dr_meenakshi86@yahoo.com

CASE REPORT

A 30-year-old male of low socioeconomic status, junk dealer by profession presented to our outpatient department with progressive bilateral nasal obstruction (more on right side) and nasal discharge since last one and a half years. He also had swelling over right side face which appeared 1 year back, and gradually involved dorsum of nose, left side of the face and forehead. He had a history of episodic spontaneous nasal bleeding, dull persistent headache and low grade fever for last 6 months. He had been treated previously by local practitioners without any symptomatic relief.

Examination revealed a tender woody swelling over dorsum of nose causing broadening of dorsum, obliterating the nasofacial grooves on both sides, involving bilateral cheeks upto the zygomatic prominence and both alae nasi. Swelling over nasion and glabella was fixed to the overlying skin which was hyperpigmented. There was markedly reduced air entry in bilateral nostrils. Rigid nasal endoscopy showed thick mucopurulent discharge and bilateral nasal polyposis. There was no cervical lymphadenopathy. Rest of the evaluation revealed no abnormal findings.

Blood examination revealed an elevated ESR (ESR = 50 mm/1st hr) and eosinophilia (AEC = 1280/cumm). Nasal discharge tested negative for acid fast bacilli. The patient was nonreactive for HIV-1 and 2. X-ray of chest was normal. Noncontrast computed tomography (CT) was performed which showed diffuse soft tissue thickening, involving the nose and subcutaneous plane in bilateral infraorbital regions, extending to bilateral superior and inferior eyelids. Skin over the forehead was thickened. There was an evidence of bilateral frontal, maxillary and ethmoid sinusitis with nasoethmoidal polyposis (Fig. 1). The incisional biopsy specimen from skin on direct microscopic examination revealed spores with prominent broad projection attached to the spongiophore and culture showed flat, cream colored and glabrous colonies covered by fine, powdery, white surface mycelium and conidiophores with satellite colonies. The findings of the incisional biopsy were consistent with *conidiobolus* species infection. A diagnosis of rhinofacial zygomycosis due to *conidiobolus coronatus* was thus reached (Fig. 2).

The patient was put on amphotericin-B 1 mg/kg/day (50 mg intravenous infusion/day), and septran 800 mg

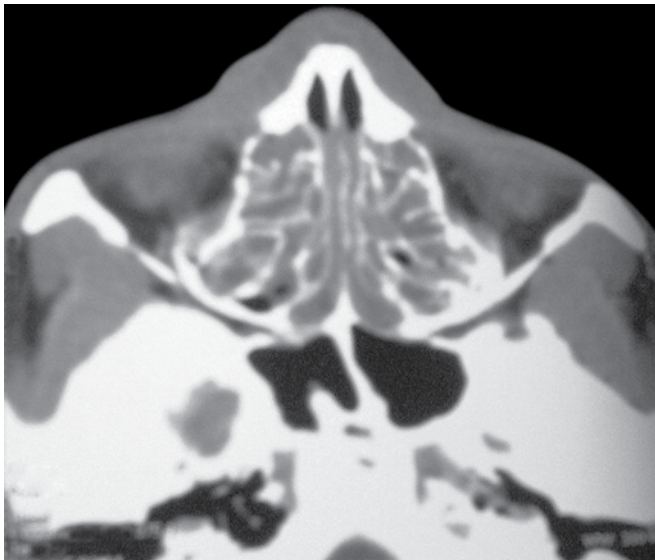


Fig. 1: Noncontrast CT scan showing bilateral ethmoidal polyposis

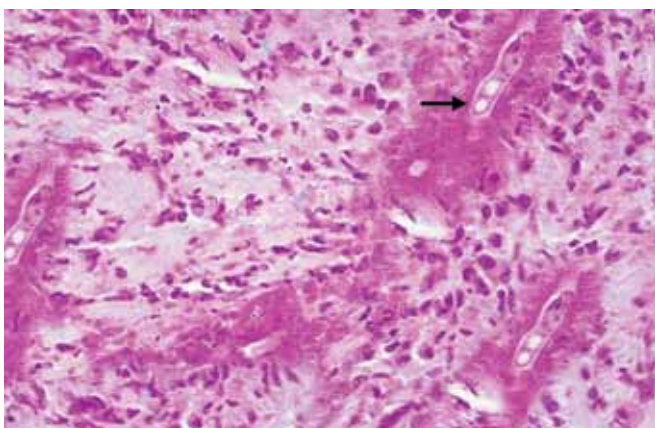


Fig. 2: Photomicrograph showing fungal elements with splendore-hoepli phenomenon (H&E, x400)

orally every 12 hours. Renal function tests were monitored closely. Endoscopic debridement of the nasal mass was performed and sent for fungal staining and histopathological examination which revealed granulomatous inflammation with fungal hyphae surrounded by eosinophilic precipitate. The report was consistent with conidiobolus zygomycosis. Injection amphotericin was given for 3 weeks till cumulative dose of 1 gm was reached after which the patient developed increased blood urea (60 mg/dl) and serum creatinine (5 mg/dl). Patient was then put on oral itraconazole 200 mg twice daily for duration of 4 months. Patient has been on regular follow-up since then and has shown no recurrence till date.

REVIEW OF LITERATURE AND DISCUSSION

Zygomycosis is the infection caused by large, occasionally septate fungi belonging to the class zygomycetes,² which is broadly divided into entomophthorales and mucorales.

Entomophthorales infect immunocompetent patients and cause chronic, indolent type of disease.^{2,3} Mucorales cause mucormycosis, also known as rhinocerebral mucormycosis which is a fulminant fungal infection seen in immunocompromised patients and is a well-known clinical entity.^{2,3}

Basidiobolus infection typically involves the leg, thigh, and buttocks.^{4,5} Infection caused by conidiobolus affects the upper respiratory tract, with involvement of nasal and paranasal mucosa and extension to the skin of the nose, superior lip and frontoglabellar region.^{1,2} The first human case was reported by Lie kyan Joe in Indonesia in 1960.³ Since then, few isolated case reports of the disease have been reported from West Africa, Central Africa, America and Asian sub-continent.⁶⁻⁹

Conidiobolus zygomycosis usually affects males in the age group of 20 to 50 years with outdoor activities. The mode of infection is not precisely known but, traumatic implantation or transmission by infected insect have been proposed.⁶ The disease begins in inferior turbinate and shows submucosal spread. It can extend through the natural ostia to the paranasal sinuses and to the subcutaneous tissues of the face (forehead, periorbital region and upper lip).⁹ Severe facial deformity and epistaxis are often the presenting symptoms.^{2,4} Our patient had severe nasal deformity, bilateral nasal obstruction, extensive nasal polyposis and epistaxis.

Histologically, entomophthorales are characterized by sparse, occasionally septate fungi surrounded by eosinophilic infiltrate referred to as 'Splendore-Hoeppli phenomenon'. Frequently, the hyphae are phagocytosed within the giant cell. This is seen in the field of chronic inflammation.^{2,6}

Treatment of rhinofacial zygomycosis is both medical and surgical. Surgical debridement of affected paranasal sinuses followed by antifungal therapy is the treatment of choice. Various drugs are used for treatment as single agent or in combination therapy. Potassium iodide, cotrimoxazole, imidazoles, amphotericin-B have been used.^{6,7} Treatment should be continued for atleast 1 month after the patient is clinically cured.¹ In our case, we tried multiple drug regime with amphotericin-B, cotrimoxazole, and itraconazole along with surgical debridement of nasal polyposis with excellent result. Otorhinolaryngologists should be aware of the existence of this entity in order to make a prompt and precise diagnosis so that early intervention can be done to reduce the morbidity.

REFERENCES

1. Thomas MM, Bai SM, Jayaprakash C, Jose P, Ebenezer R. Rhinotomophthoromycosis. *Indian J Dermatol Venereol Leprol* 2006;72(4):296-299.



2. Nayak DR, Pillai S, Rao L. Rhinofacial Zygomycosis caused by *Conidiobolus coronatus*. *Indian J Otolaryngol Head Neck Surg* 2004;56(3):225-227.
3. Nathan MD, Kellar AP Jr, Lerner CJ, Davis JC. Entomophthorales infection of the maxillofacial region. *Laryngoscope* 1982;92(7):767-769.
4. Martinson FD. Chronic phycomycosis of the respiratory tract: Rhinophycomycosis entomophthorae. *Am J Trop Med Hyg* 1971;20(3):449-455.
5. Thammayya A. Zygomycosis due to *conidiobolus coronatus* in West Bengal. *Indian J Chest Dis Allied Sci* 2000;42(4):305-309.
6. Gugnani HC. Entomophthoromycosis due to *conidiobolus*. *Eur J Epidemiol* 1992;8(3):391-396.
7. Ribes JA, Vanover-Sams CL, Baker DJ. Zygomycetes in human disease. *Clin Microbiol Rev* 2000;13(2):236-301.
8. Costa AR, Porto E, Pegas JRP, Silva dos Reis VM, Pires MC, Lacaz CDS, et al. Rhinofacial zygomycosis caused by *Conidiobolus (sic) coronatus* - A case report. *Mycopathologia* 1991;115(1):1-8.
9. Ochoa LF, Duque CF, Velez A. Rhinientomophthoramycosis- Report of two cases. *J Laryngol Otol* 1996;110:1154-1156.