

# Clinicopathological Correlation between Peripheral Blood Eosinophilia and Inferior Turbinate Tissue Eosinophils

<sup>1</sup>UP Santosh, <sup>2</sup>KB Sunil Kumar, <sup>3</sup>Aniketh Shyamsunder Pandurangi

## ABSTRACT

**Background and objectives:** Allergic rhinitis affects up to 20% of the general population and is one of the most common reasons for presentations to the outpatient department. We hereby present a case series which attempts to have a correlation between tissue eosinophilia (inferior turbinate) and increased eosinophil count in blood ( $>440$  cells/mm<sup>3</sup>).

**Materials and methods:** Thirty-six patients presented to the Outpatient Department of Bapuji Hospital and Chigateri General Hospital (Teaching Hospitals attached to JJM Medical College), Davangere, with nasal obstruction and symptoms suggestive of allergic rhinitis with turbinate hypertrophy who were posted for elective bilateral partial inferior turbinectomy with/without submucous resection/septoplasty. These patients had increased absolute eosinophil count in blood. Formalin fixed inferior turbinectomy specimens were routinely processed for histopathology. Eosinophils in the mucosa and submucosal region were counted by method of Shioda and Mishima.

**Results:** Ten patients out of 36 showing increased eosinophil count in blood show 'significant eosinophilia' in turbinates (27.7%).

**Conclusion:** Peripheral eosinophilia does not always correlate with tissue eosinophilia which opens up a possibility of using nasal mucosa biopsy for confirmation of presence of eosinophils. Further studies are needed to explore the demonstration of 'activated' tissue eosinophils in the diagnosis of allergic rhinitis.

**Keywords:** Allergic rhinitis, Tissue eosinophilia, Inferior turbinate.

**How to cite this article:** Santosh UP, Sunil KB, Pandurangi AS. Clinicopathological Correlation between Peripheral Blood Eosinophilia and Inferior Turbinate Tissue Eosinophils. *Int J Otorhinolaryngol Clin* 2014;6(2):58-60.

**Source of support:** Nil

**Conflict of interest:** None

<sup>1</sup>Professor, <sup>2</sup>Associate Professor, <sup>3</sup>Resident

<sup>1,3</sup>Department of ENT and Otolaryngology, JJM Medical College Davangere, Karnataka, India

<sup>2</sup>Department of Pathology, JJM Medical College, Davangere Karnataka, India

**Corresponding Author:** UP Santosh, Professor, Department of ENT and Otolaryngology, JJM Medical College, Davangere Karnataka, India, Phone: 9845155223, e-mail: dr.santoshup@gmail.com

## INTRODUCTION

Allergic rhinitis affects up to 20% of the general population and is one of the most common reasons for presentations to the outpatient department. Recent multinational studies show wide variations in prevalence of using simple 'working definitions' in standardized questionnaires. Although not a severe disorder, allergic rhinitis significantly affects learning performance at school, alters patients' social life and work productivity. The costs incurred by rhinitis are substantial.

This study is an attempt to show evidence of tissue eosinophilia in inferior turbinates in patients with peripheral eosinophilia ( $>440$  cells/mm<sup>3</sup>).

## MATERIALS AND METHODS

### Sample Size (36 Patients)

This study included 36 patients presented to the Outpatient Department of Bapuji Hospital and Chigateri General Hospital (Teaching Hospitals attached to JJM Medical College), Davangere, with nasal obstruction and symptoms suggestive of allergic rhinitis with turbinate hypertrophy who were posted for elective bilateral partial inferior turbinectomy with/without submucous resection/septoplasty. These patients had increased absolute eosinophil count in blood. Formalin fixed inferior turbinectomy specimens were routinely processed for histopathology and 5 micron thick sections were cut and studied. Eosinophils in the mucosa and submucosal region were counted.

Grading of eosinophils in turbinate specimens was done using the following method of Shioda and Mishima:

- +/-: Occasional cells
- +: Few natural cells (Fig. 1)
- ++: Moderate number of cells (Fig. 2)
- +++: Clumps

'++' and '+++' are considered significant. After grading, the results were analyzed.

## OBSERVATIONS AND RESULTS

The histopathological examination was done in all the turbinectomy specimens whose results were as follows:

- +/-: 19 patients



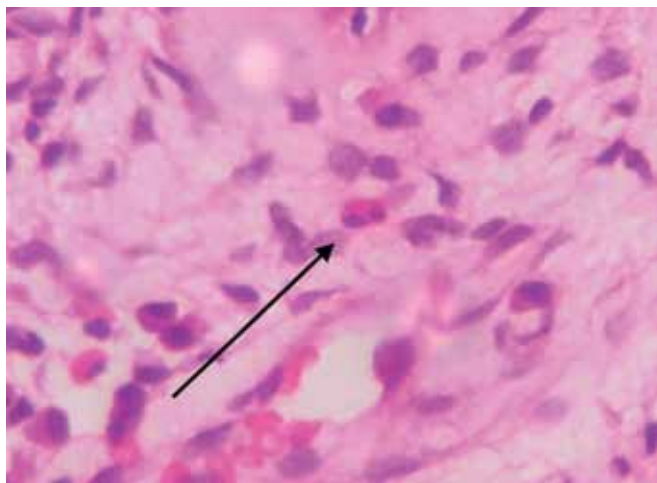


Fig. 1: Few natural cells

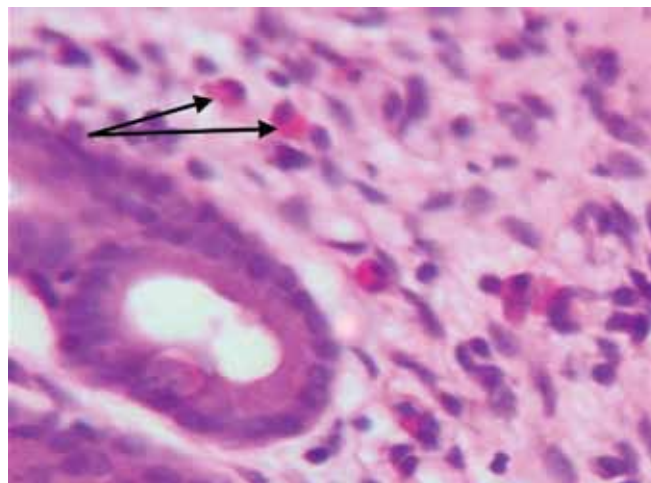


Fig. 2: Moderate number of cells

- +: Six patients
- ++: Nine patients
- +++: One patient
- No eosinophils: 1 patient.

Thus, excluding one patient whose turbinates are not showing eosinophils on histopathological examination, out of 35 patients, 19 showed occasional cells, six showed few natural cells, nine showed moderate no. of cells, one showed clumps in excised turbinates.

Out of 36 patients showing increased eosinophil count in peripheral blood, 10 showed significant tissue eosinophilia in inferior turbinate.

## DISCUSSION

The proinflammatory role of eosinophils is well recognized. In the peripheral blood, they usually represent less than 4% of circulating cells, they migrate into the tissue upon an appropriate signal by a mechanism which involves cytokines, chemokines and adhesion molecules. Once in the tissue, eosinophils mature and remain alive for days or weeks, depending on survival signals from their local environment which retard apoptosis. In allergic rhinitis, eosinophils are the predominant infiltrating cell.<sup>1</sup>

In a study, it was seen that patients with allergic rhinitis exhibit peripheral eosinophilia and basophilia, the magnitude of which correlates with the severity of symptoms. The systemic aspect of allergic rhinitis may be involved in the perpetuation and intensification of its local manifestations, which include acute and chronic inflammation of the nasal mucosa and their functional consequences.<sup>2</sup>

In another study, eosinophil count in peripheral blood, nasal secretion and nasal mucosa were studied in 20 controls and 38 patients with different patterns of allergic rhinitis. Secretion and tissue eosinophilia were pathologically high in a greater number of patients than peripheral blood eosino-

philia. The conclusion was reached that examination of the local site and local secretions for eosinophilia is helpful in the diagnosis and differential diagnosis of allergic rhinitis.<sup>3</sup>

Another study attempted at describing the density characteristics and functional heterogeneity of nasal tissue eosinophils. The density distribution profiles of eosinophils from patients with allergic rhinitis (AR) showed peaks at densities of 1.068 to 1.084 gm/ml, significantly lower than the densities of eosinophils in non-allergic patients with nasal polyps and chronic sinusitis ( $p < 0.01$ ).<sup>4</sup>

The immunohistology of the nasal mucosa was examined in one study where 13 grass pollen sensitive patients and seven normal nonatopic control subjects, before and during the pollen season. Cryostat sections (6  $\mu\text{m}$ ) of biopsy specimens from the inferior turbinate were immunostained with a panel of monoclonal antibodies for eosinophils. Mast cell subtypes were measured with a double sequential immunostaining method, seasonal increases in both total and 'activated' eosinophils were observed in the submucosa for the patients, which were significant when compared with control subject. The results indicate that seasonal allergic rhinitis is associated with local accumulation of activated eosinophils.<sup>5</sup>

In one study, on histopathological examination, nasal polyps and nasal mucosa in allergic rhinitis showed different forms of pseudostratified respiratory epithelium, whereas the dominant characteristic of *lamina propria* is an eosinophilic infiltration. The aim of this study was to compare interleukin (IL)-5 and eosinophilic cationic protein (ECP) levels in the nasal fluid of 42 patients: 12 with allergic rhinitis and nasal septal deviation, 17 non-atopic patients with nasal polyposis, and 13 atopic nasal polyp patients were enrolled in this cross-sectional study. Eosinophilic cationic protein (ECP) levels in nasal fluid and eosinophil counts in tissue specimens correlated well in all the three groups

of patients. Our study has shown that atopic nasal polyp patients have a higher level of eosinophilic inflammation than non-atopic patients with nasal polyps and patients with allergic rhinitis.<sup>6</sup>

## CONCLUSION

Most common cause of eosinophilia in industrialized countries is atopic allergic diseases, seasonal and perennial rhinitis and asthma. Allergic disease results usually in mild increase in eosinophil counts in peripheral blood. Peripheral eosinophilia does not always correlate with tissue eosinophilia which opens up a possibility of using nasal mucosa biopsy for confirmation of presence of eosinophils. Further studies are needed to explore the demonstration of 'activated' tissue eosinophils in the diagnosis of allergic rhinitis.

## REFERENCES

1. Scadding G, Durham S. Allergic Rhinitis. In: Gleeson M, et al, editors. Scott-Brown's Otolaryngology and Head and Neck Surgery. 7th ed. Edward Arnold 2008;2:1386-1407.
2. Togias AG. Systemic immunologic and inflammatory aspects of allergic rhinitis. *J Allergy Clin Immunol* 2000;106(5): S247-250.
3. Bhandari CM, Baldwa VS. Relative value of peripheral blood, secretion and tissue eosinophilia in the diagnosis of different patterns of allergic rhinitis. *Ann Allergy* 1976 Oct;37(4): 280-284.
4. Masuyama K, Samejima Y, Ishikawa T. Nasal tissue eosinophils in allergic rhinitis. *Auris Nasus Larynx* 1993;20(3):205-213.
5. Bentley AM, et al. Immunohistology of the nasal mucosa in seasonal allergic rhinitis: increases in activated eosinophils and epithelial mast cells. *J Allergy Clin Immunol* 1992 April; 89(4):877-883.
6. Peric A, et al. Inflammatory mediators in allergic rhinitis and nasal polyposis. *Arh Hig Rada Tokiskol* 2011;62:341-348.