

# Ultrasound Imaging of Thyroid Gland

<sup>1</sup>Rajesh C Kamble, <sup>2</sup>Alpana N Joshi, <sup>3</sup>Pravin Mestry, <sup>4</sup>Mohit Shah

**Keywords:** Ultrasound, Thyroid, Isthmus, Thyroid nodule.

**How to cite this article:** Kamble RC, Joshi AN, Mestry P, Shah M. Ultrasound Imaging of Thyroid Gland. Int J Otorhinolaryngol Clin 2014;6(1):35-46.

**Source of support:** Nil

**Conflict of interest:** None

## INTRODUCTION

With advent of high frequency linear transducers in field of ultrasound, the imaging of superficial structures has dynamically changed. The thyroid gland is an endocrine gland, superficial in location can be evaluated in day-to-day clinical practice for all thyroid diseases. The most common clinical presentation is a nodule. Clinical examination is unable to identify the true nature of the nodule. The aim of imaging is basically to distinguish a benign from malignant nodule.

The normal gland having a homogeneous structure is demarcated by clear anatomic structures, such as common carotid artery and internal jugular vein and hence can be evaluated with greater accuracy. Today other than evaluation of nodules, ultrasonography guided fine needle aspiration cytology (FNAC) can provide all answers in investigation of thyroid nodules.

## ANATOMY OF THYROID GLAND

The thyroid gland consists of right and left lobes connected in the midline by a narrow isthmus.

The gland is surrounded by a sheath derived from pretracheal layer of deep fascia which anchors the gland to trachea and larynx.

The pyramidal lobe (10-30%) is an accessory lobe arising from isthmus and runs upward in the midline anterior to the thyroid cartilage.

## Relations of Thyroid Gland

### *Anterior and Lateral*

- Strap muscles (sternohyoid and sternothyroid)
- Sternocleidomastoid muscle
- Superior belly of omohyoid.

### *Posterior and Lateral*

- Carotid sheath containing the common carotid artery (CCA), internal jugular vein (IJV) and vagus nerve
- Scalenus anterior muscle.

### *Medial and Posterior*

- Larynx and trachea
- Esophagus
- Longus colli muscle
- Recurrent laryngeal nerve in tracheoesophageal groove.

## Relations of Isthmus

### *Anterior*

- Strap muscles
- Anterior jugular vein
- Fascia
- Skin.

### *Posterior*

Tracheal cartilage—2nd to 4th rings.

## BLOOD SUPPLY

### **Arterial**

- Superior thyroid artery branch of external carotid artery
- Inferior thyroid artery arising from thyrocervical trunk
- Thyroidea ima artery arises from aortic arch/brachiocephalic trunk.

### **Venous**

- Superior, middle and inferior thyroid veins originate from perithyroid venous network

<sup>1-4</sup>Consultant

<sup>1-3</sup>Department of Radiodiagnosis, Shobha Diagnostic Centre Mumbai, Maharashtra, India

<sup>4</sup>Department of Radiodiagnosis, Abhipray Diagnostic Centre Mumbai, Maharashtra, India

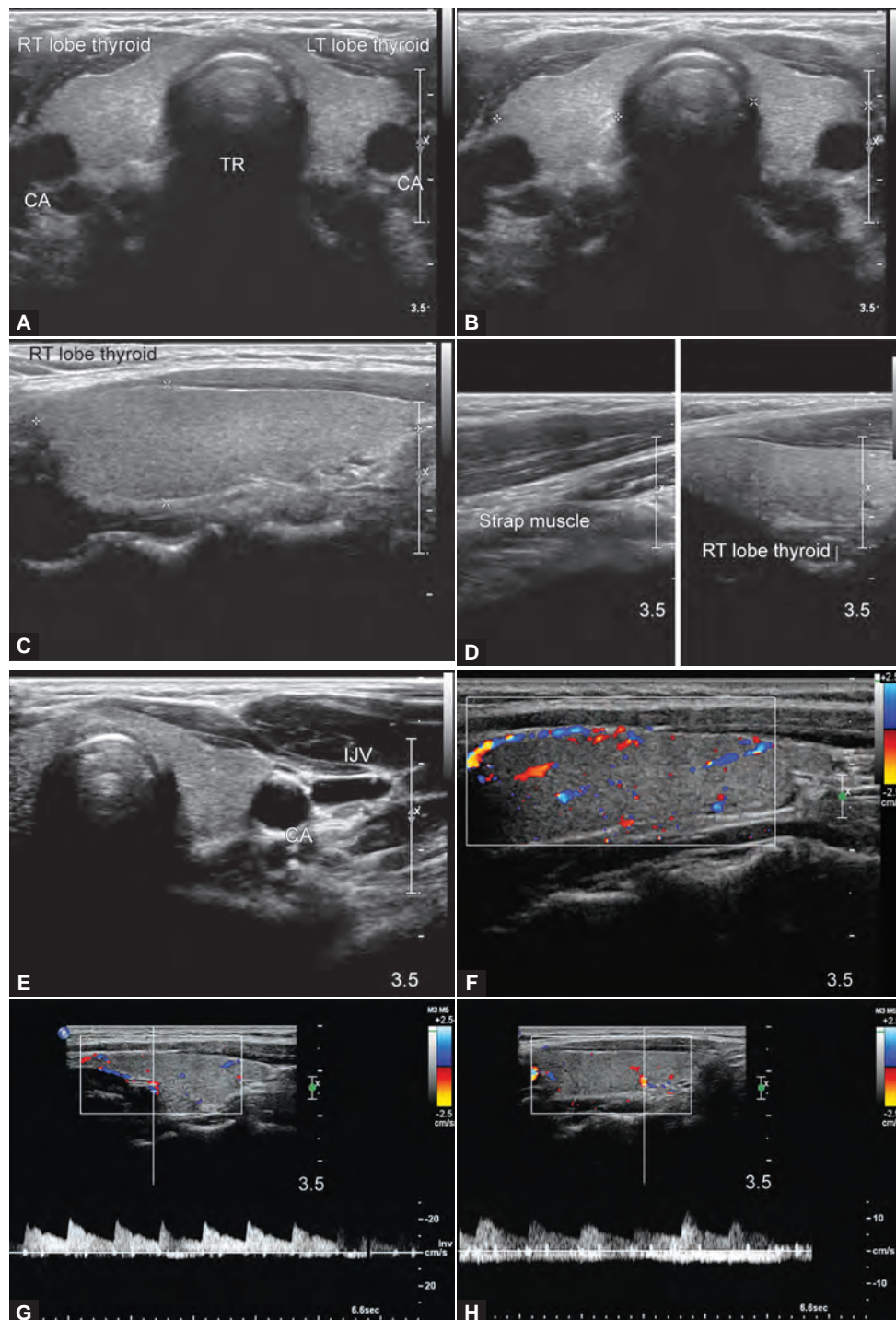
**Corresponding Author:** Rajesh C Kamble, Consultant, Department of Radiodiagnosis, Shobha Diagnostic Centre, Shop No. 2A Wing Dhiraj Chsl, Poddar Road, Opp Shanti Park, Malad East Mumbai, Maharashtra, India, e-mail: docrajkamble@yahoo.com drrajeshkamble@gmail.com

- Superior and middle veins drain into ipsilateral IJV
- Inferior thyroid vein receives tributaries from isthmus and anastomose with inferior thyroid vein from opposite side and drain into brachiocephalic vein.

## Lymphatics

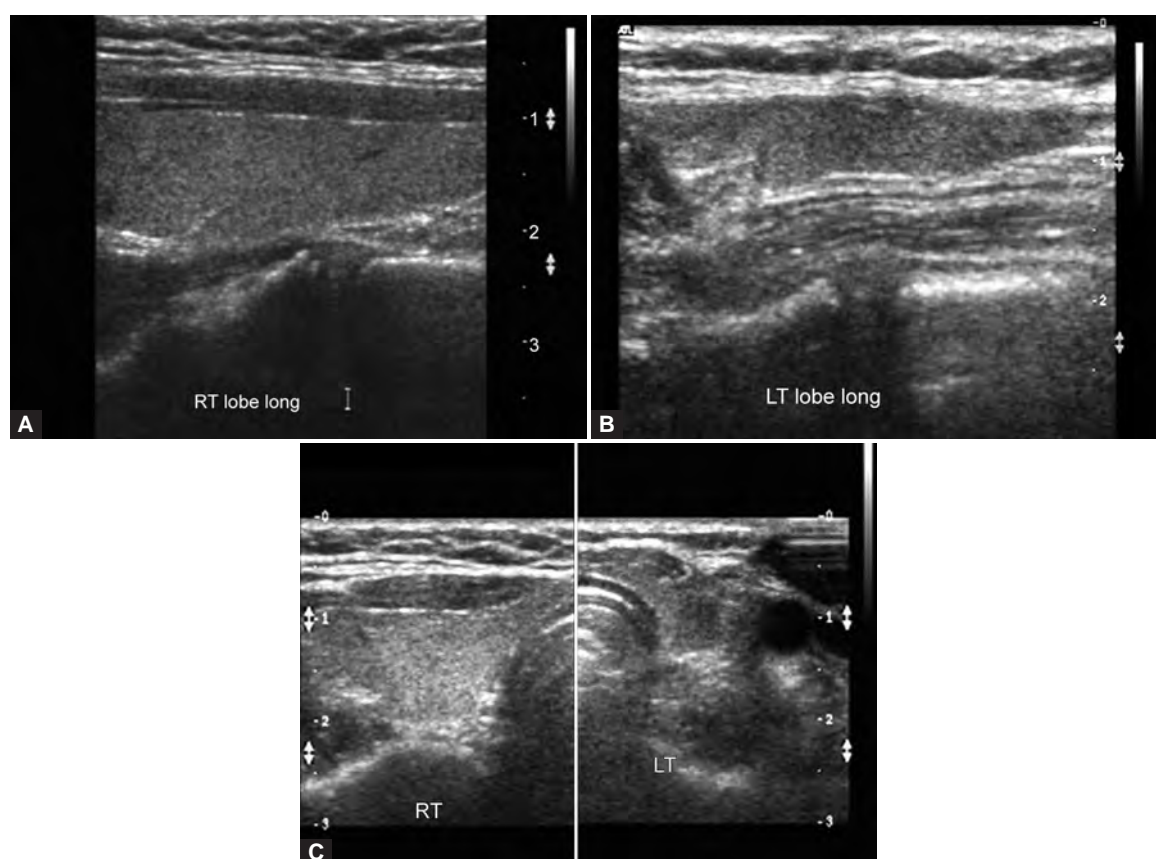
Lymphatic vessels from thyroid form subcapsular network and give rise to lateral and medial collecting trunks which drain into anterior and lateral chain of nodes along the IJV (deep cervical chain) and pretracheal, paratracheal nodes.

## NORMAL THYROID ANATOMY IMAGES



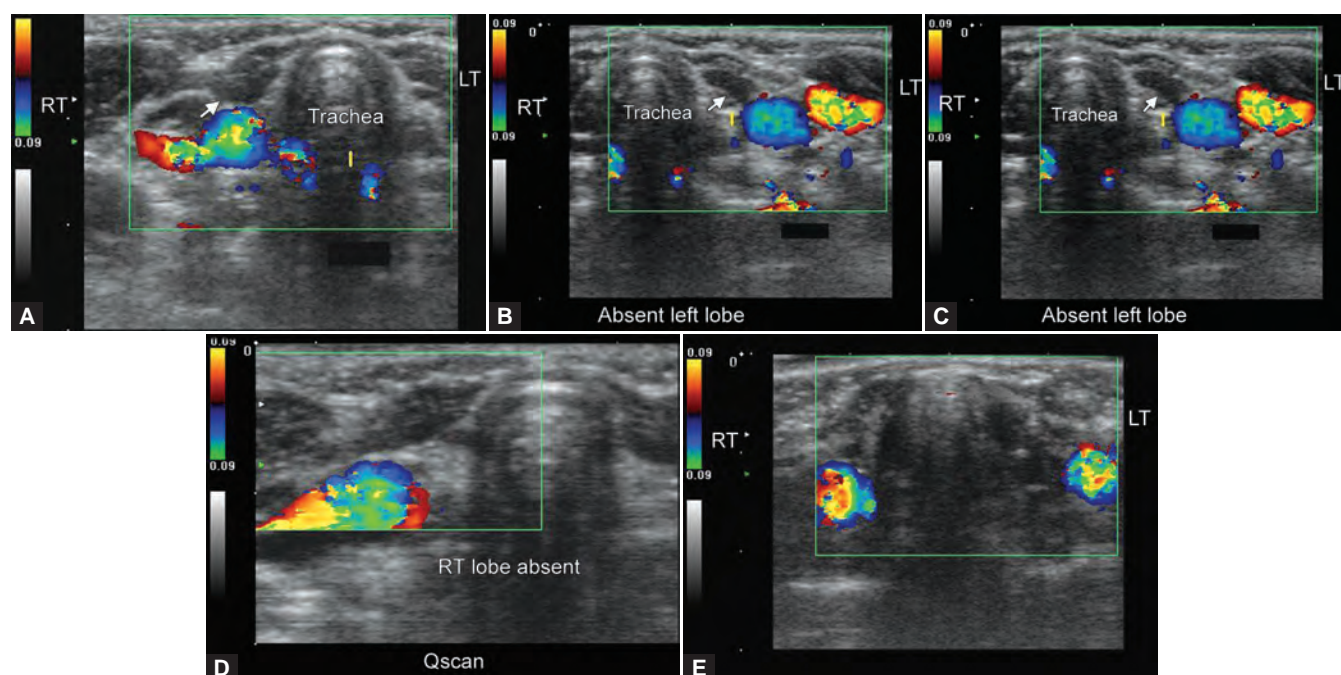
**Figs 1A to H:** (A) Panoramic transverse view of whole thyroid gland with trachea (tR) in the midline, (B and C) B-mode transverse and longitudinal images of the thyroid gland, (D and E) relations of thyroid gland with surrounding structures [strap muscles, internal jugular vein (IJV) and carotid artery (CA)], (F) color Doppler image of thyroid showing normal vascularity. (G and H) showing spectral Doppler flow and tracings in the superior thyroid artery (G) and intrathyroidal flow (H)

## CONGENITAL THYROID ABNORMALITIES



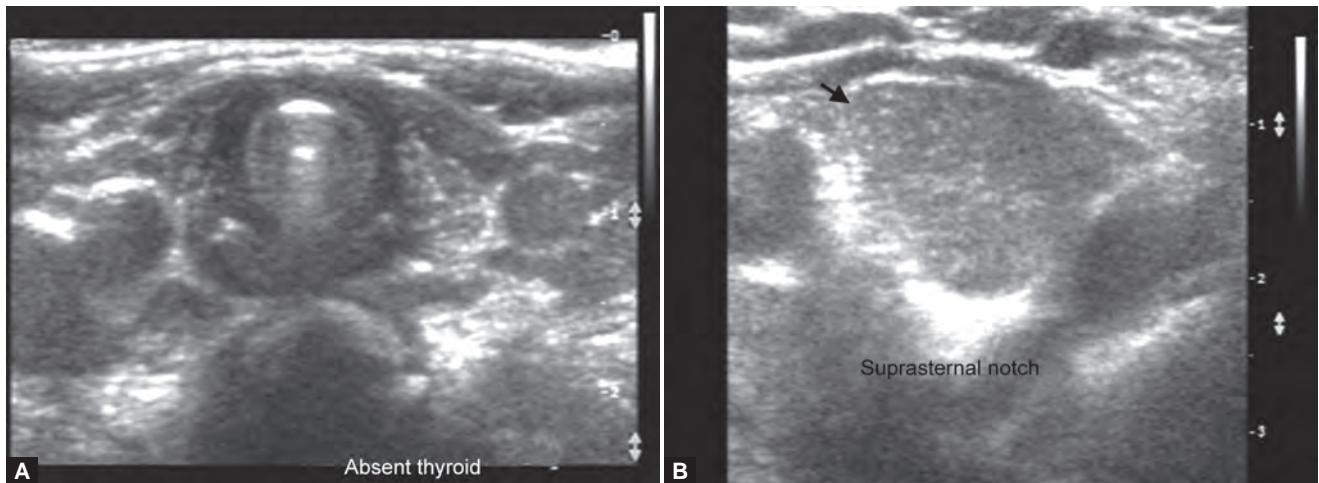
**Figs 2A to C:** Congenital hypoplasia of thyroid gland (the left lobe of thyroid gland is small in size in this 20-year-old female as compared to the contralateral gland): (A) normal sized right lobe of thyroid gland, (B) hypoplastic left thyroid gland and (C) panoramic view confirming hypoplastic left thyroid gland

## AGENESIS OF THE THYROID GLAND



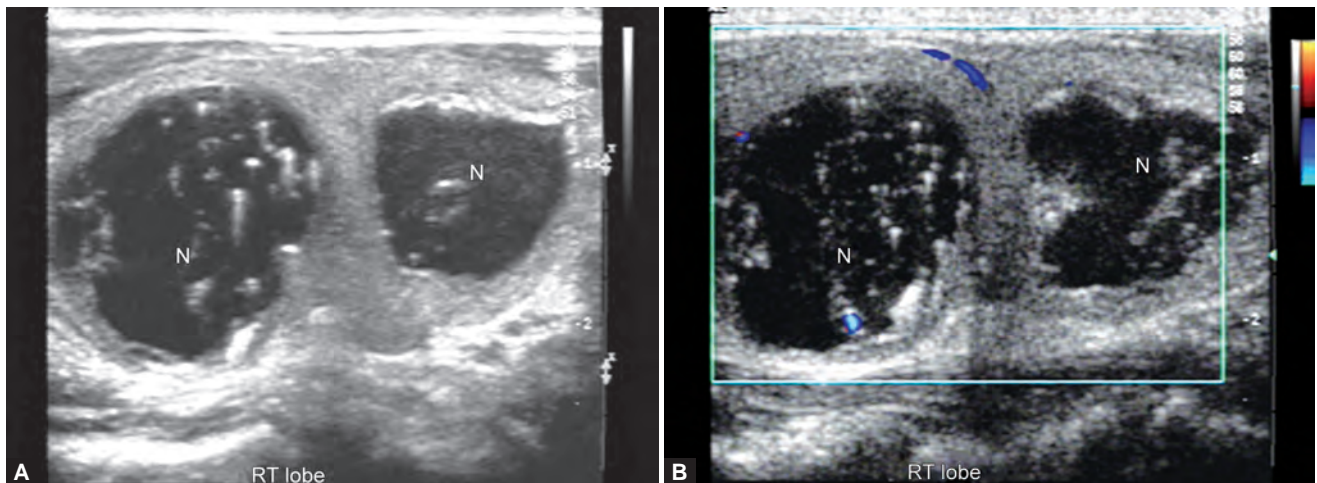
**Figs 3A to E:** Sonography of the thyroid in this 18 months old female child revealed congenital absence of the entire thyroid. Note the empty fossae where the right and left lobes would normally lie (A and B), the carotid artery and jugular vein of both sides are seen in the color Doppler images (C to E). These ultrasound and color Doppler images suggest congenital agenesis of the thyroid



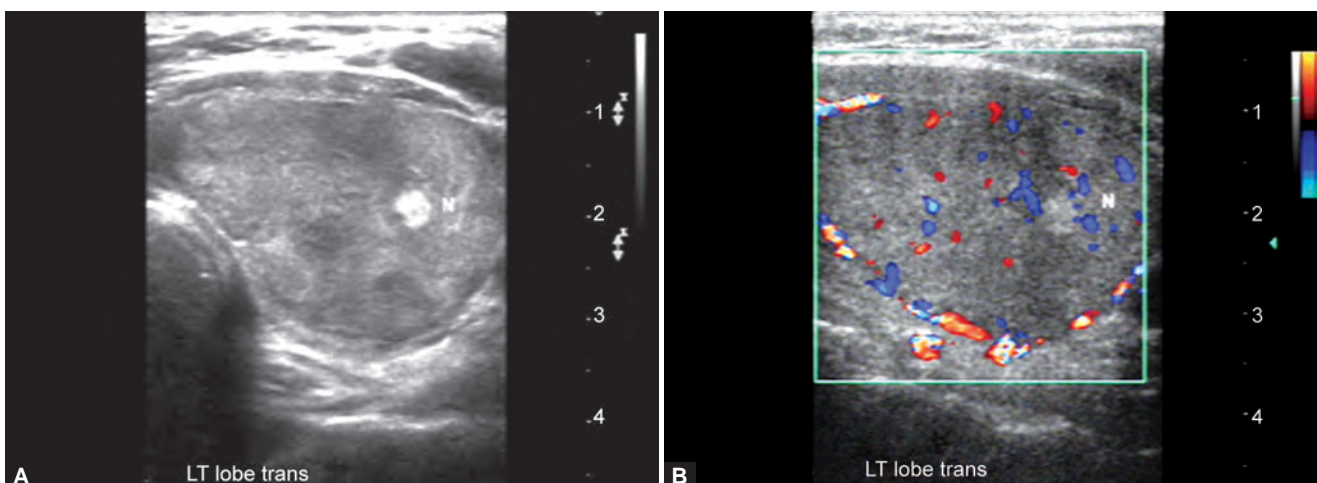


**Figs 4A and B:** Ectopic thyroid gland (the both thyroid fossae were empty with ectopic thyroid gland seen in the suprasternal notch in the midline): (A) empty thyroid fossae and (B) ectopic thyroid located in the midline suprasternal notch

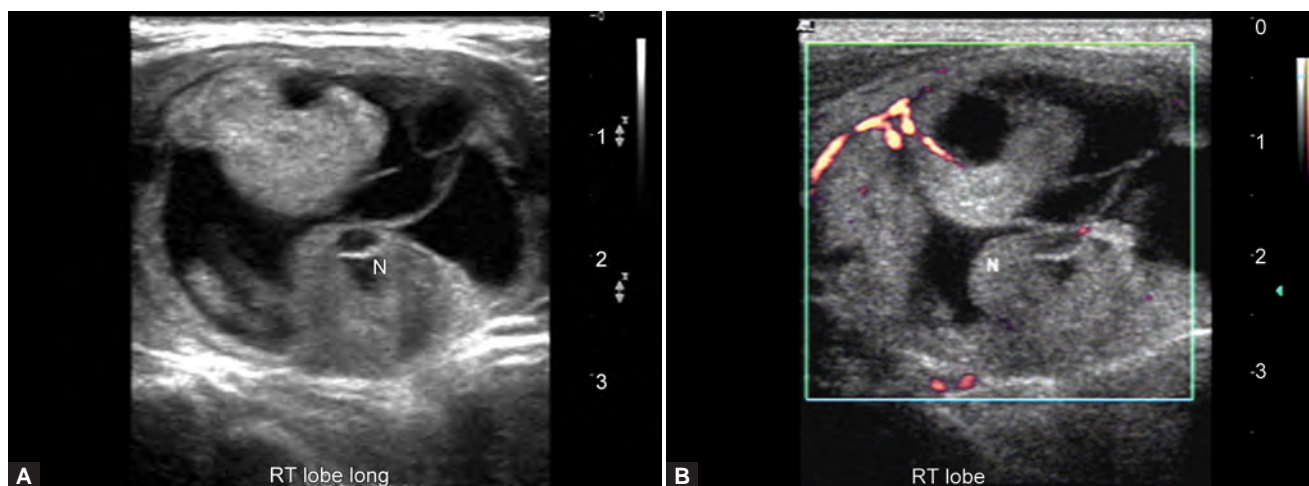
## NODULAR THYROID DISEASES



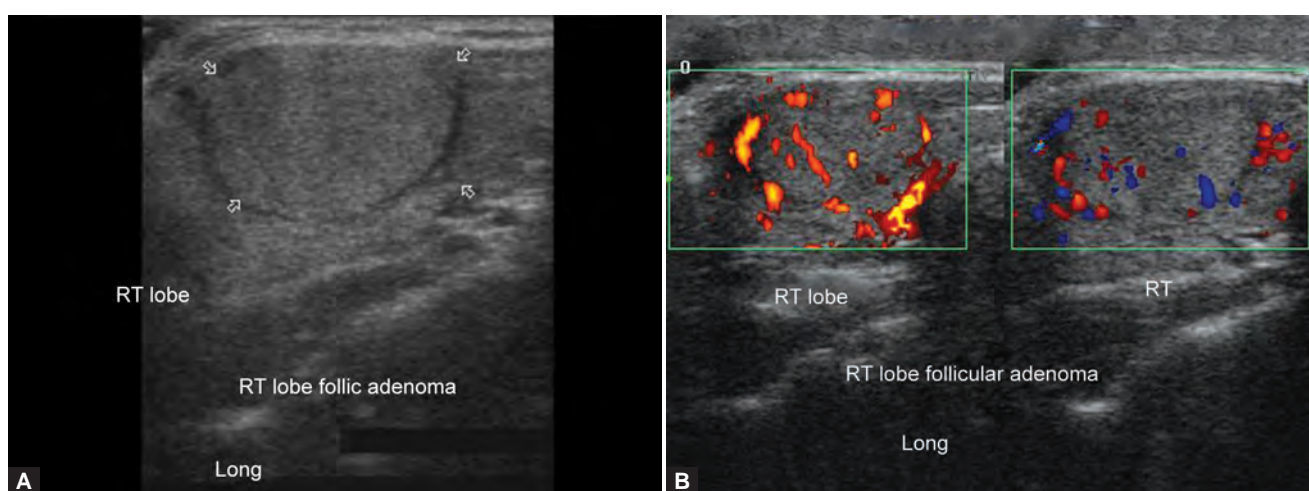
**Figs 5A and B:** Solitary thyroid nodule showing colloid degeneration and classic 'comet tail artifacts': (A) B-mode image and (B) color Doppler image



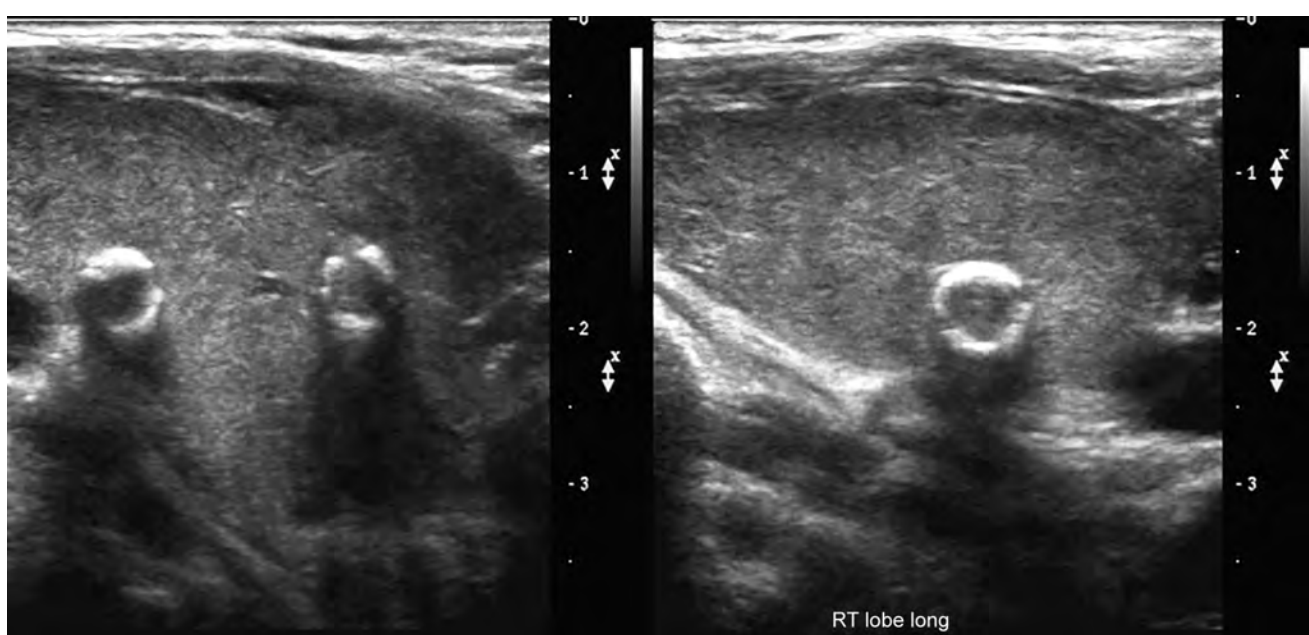
**Figs 6A and B:** Solitary adenomatous thyroid nodule: (A) B-mode image shows homogeneous isoechoic thyroid nodule and (B) color Doppler image showing perinodular flow favor benign lesion



**Figs 7A and B:** Adenomatous nodule with colloid degeneration: (A) B-mode and (B) power Doppler images

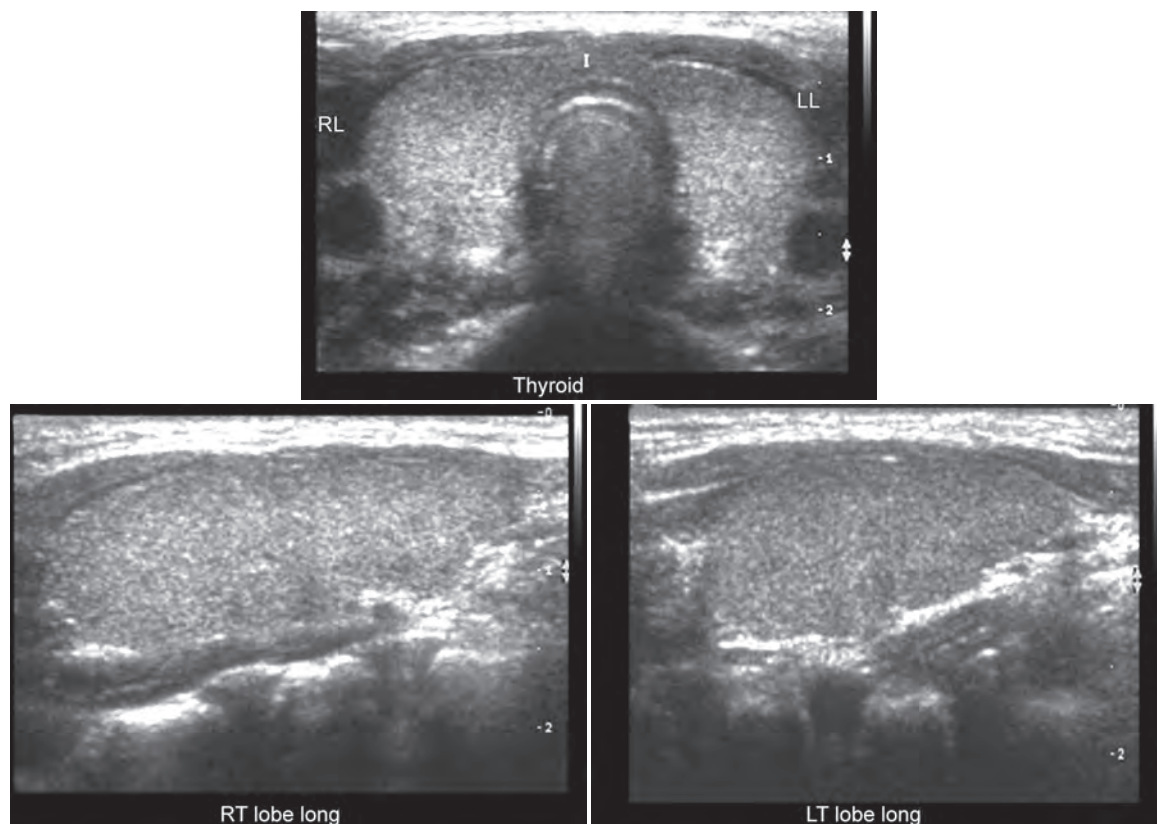


**Figs 8A and B:** Benign follicular adenoma 45-year-old female: (A) A very well-defined hyperechoic lesion involving the right lobe. The lesion classically shows a hypoechoic halo surrounding it (secondary to fibrous capsule and blood vessels) and (B) color Doppler image of the same with appearance of classic—spoke and wheel like appearance



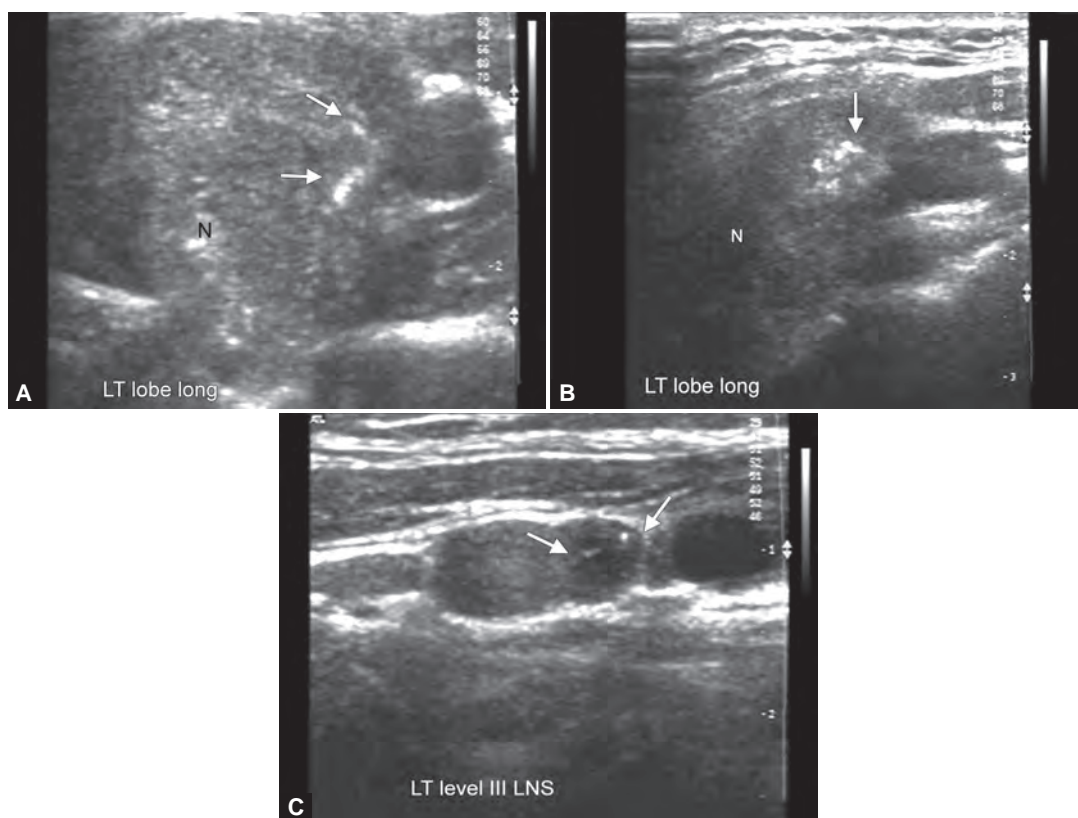
**Fig. 9:** Thyroid nodule with egg shell calcifications favors benign lesions



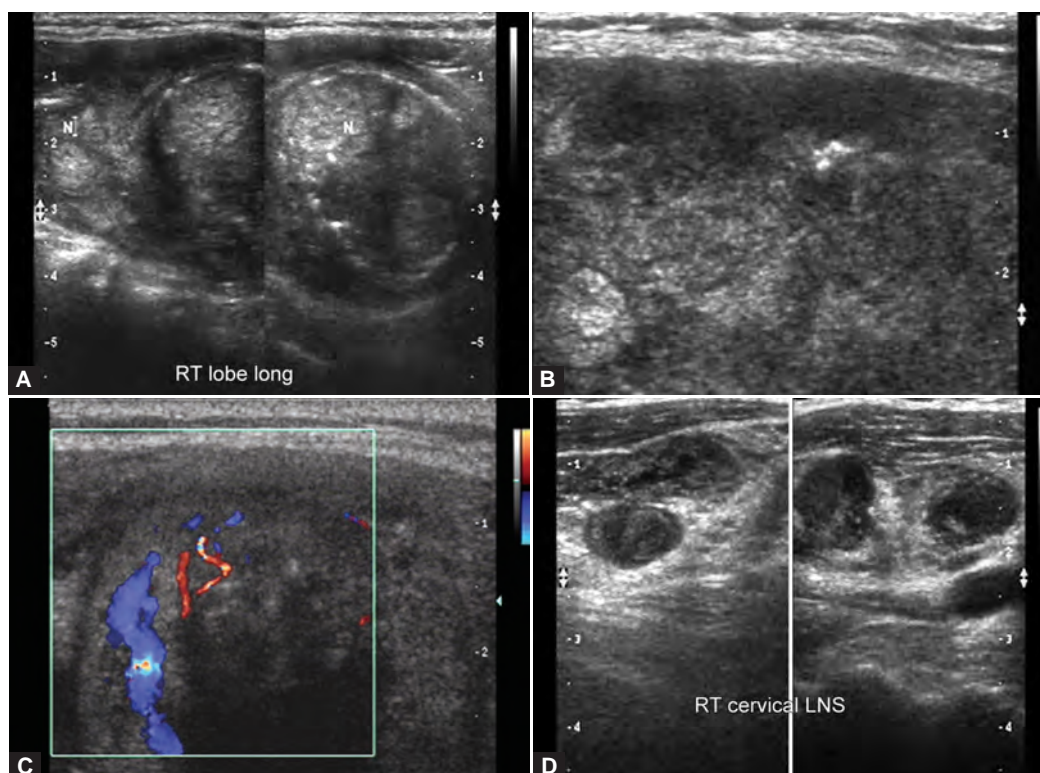


**Fig. 10:** Benign hyperplasia of the gland: goiter

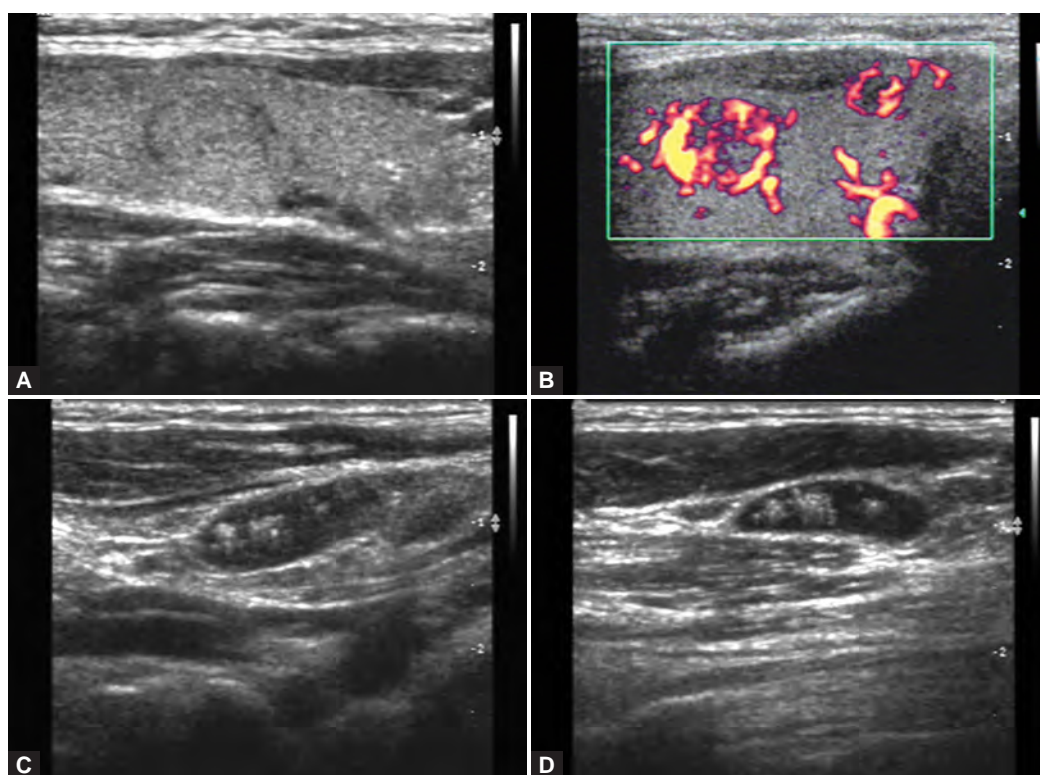
## MALIGNANCIES INVOLVING THE THYROID GLAND



**Figs 11A to C:** Papillary carcinoma: (A) Hypoechoic solid nodule showing multiple tiny punctate echogenic foci. This is classic appearance of papillary carcinoma, (B) arrows pointing to echogenic foci and (C) left sided level III metastatic lymph nodes

**ANAPLASTIC CARCINOMA**

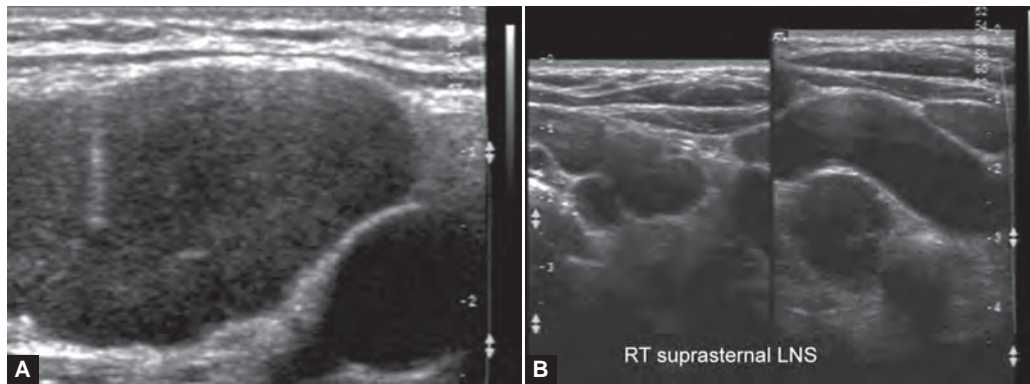
**Figs 12A to D:** This was a case of 75-year-old female with cytology proven anaplastic carcinoma: (A and B) show heterogeneous solid hypoechoic mass lesion seen involving the entire right lobe of thyroid gland, (C) shows chaotic internal vascularity within the heterogeneous gland and (D) metastatic enlarged right cervical lymph nodes

**MEDULLARY CARCINOMA**

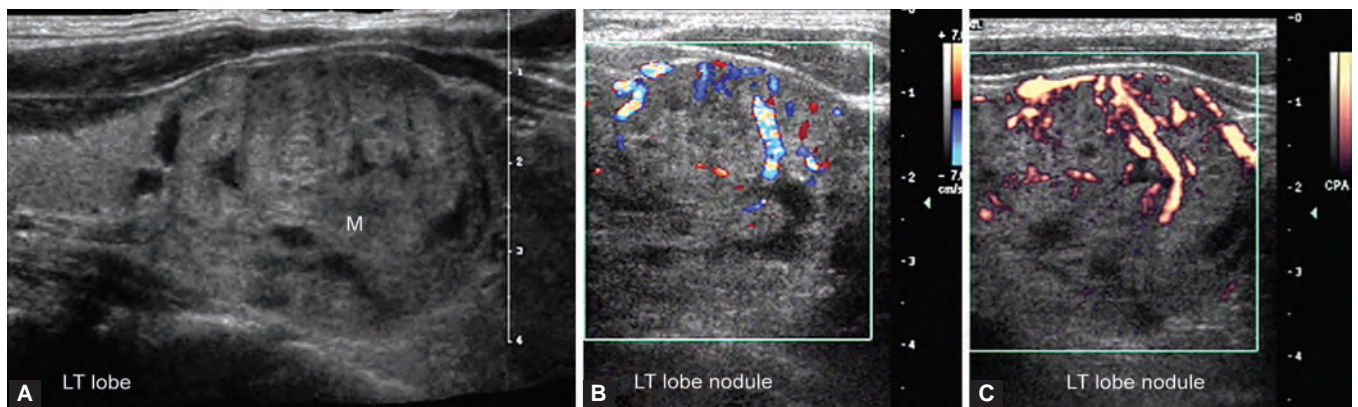
**Figs 13A to D:** This was a known case of multiple endocrine neoplasia (MEN) type II syndrome: (A) shows iso-hyperechoic nodule within the right thyroid gland, (B) power Doppler shows intranodular hypervascularity (internal), (C and D) metastatic cervical lymph nodes. These nodes show punctate hyperechoic foci within (proven on FNAC)



## THYROID LYMPHOMA



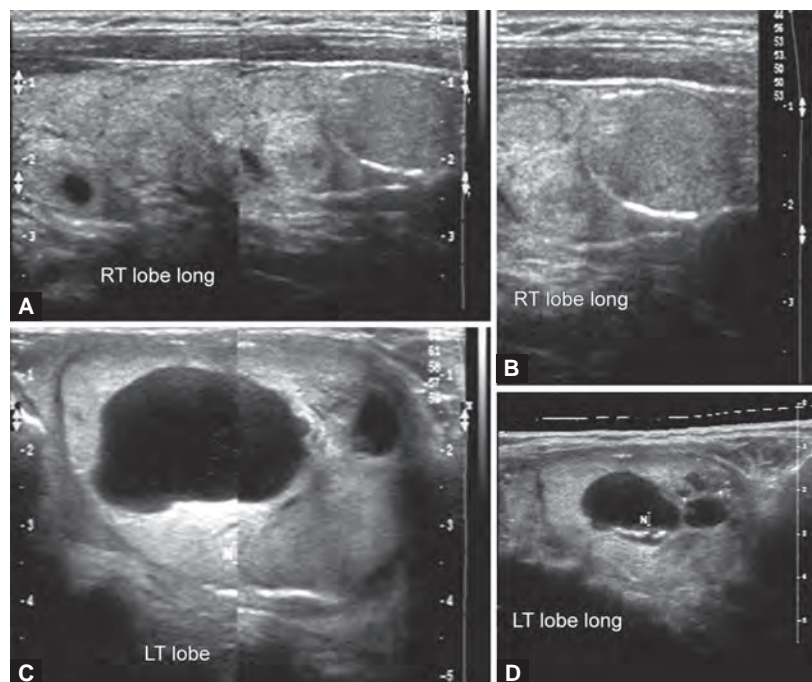
**Figs 14A and B:** A 50 years old female patient showed thyroid involvement in a case of lymphoma: (A) Shows solid hypoechoic lesion seen involving the entire right lobe of right thyroid gland (biopsy proven lymphoma) and (B) multiple diffuse hypoechoic non-necrotic enlarged right cervical lymph nodes consistent with lymphoma



**Figs 15A to C:** A 55-year-old female with palpable nodule in the left lobe: (A) B-mode image shows an ill-defined solid hyperechoic lesion in the left lobe of thyroid gland with hypoechoic areas within. Color Doppler images (B and C) show internal vascularity with chaotic arrangement of blood vessels. This was follicular carcinoma. There are no unique features to distinguish follicular adenoma from carcinoma

## FOCAL AND DIFFUSE THYROID DISEASES

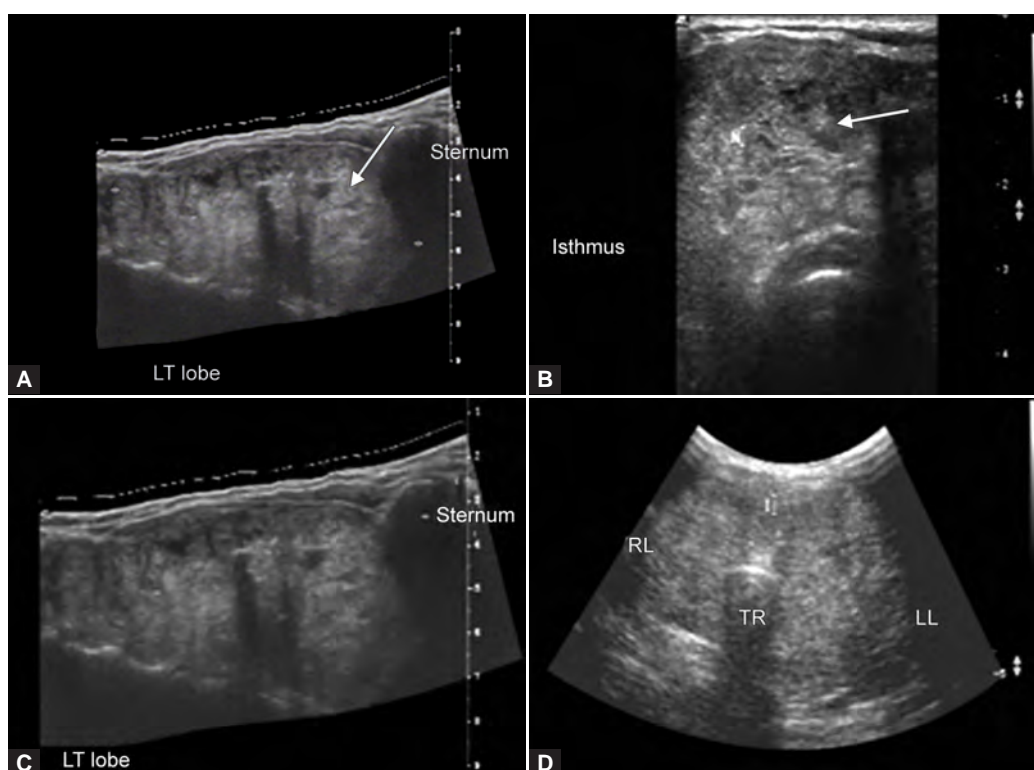
### Multinodular Goiter



**Figs 16A to D:** A 45-year-old female shows multiple iso-hyper-reflective nodules seen within the right thyroid gland (A and B), the nodules in the left lobe show cystic degeneration (C and D)

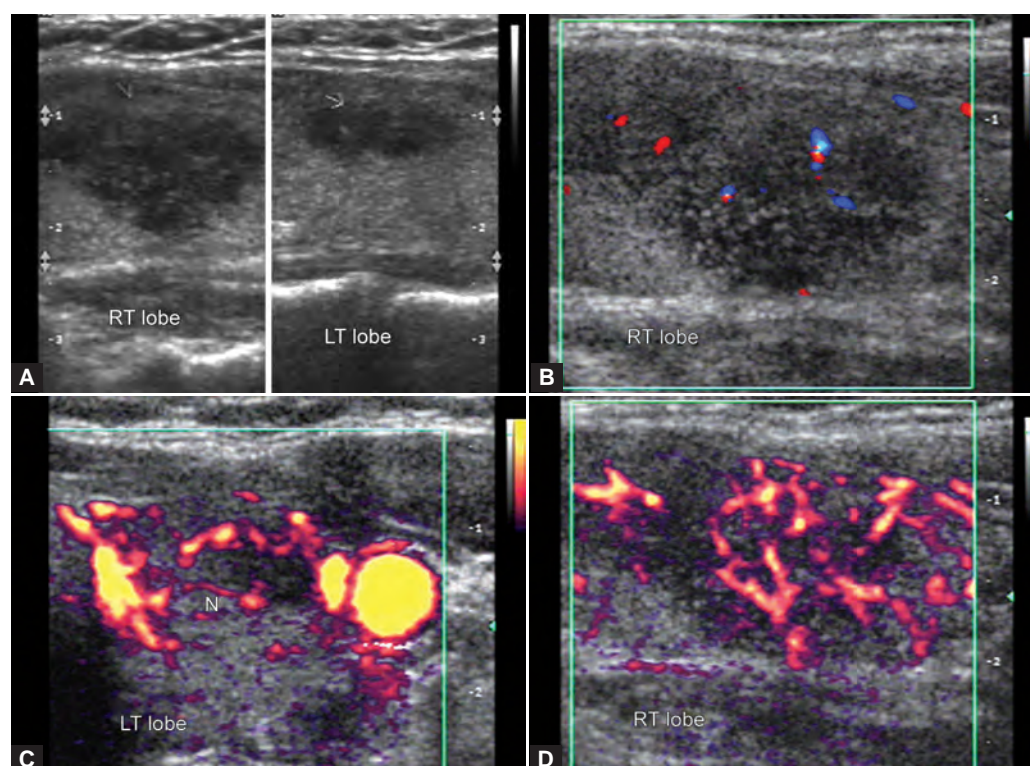


## MULTINODULAR GOITER WITH RETROSTERNAL EXTENSION

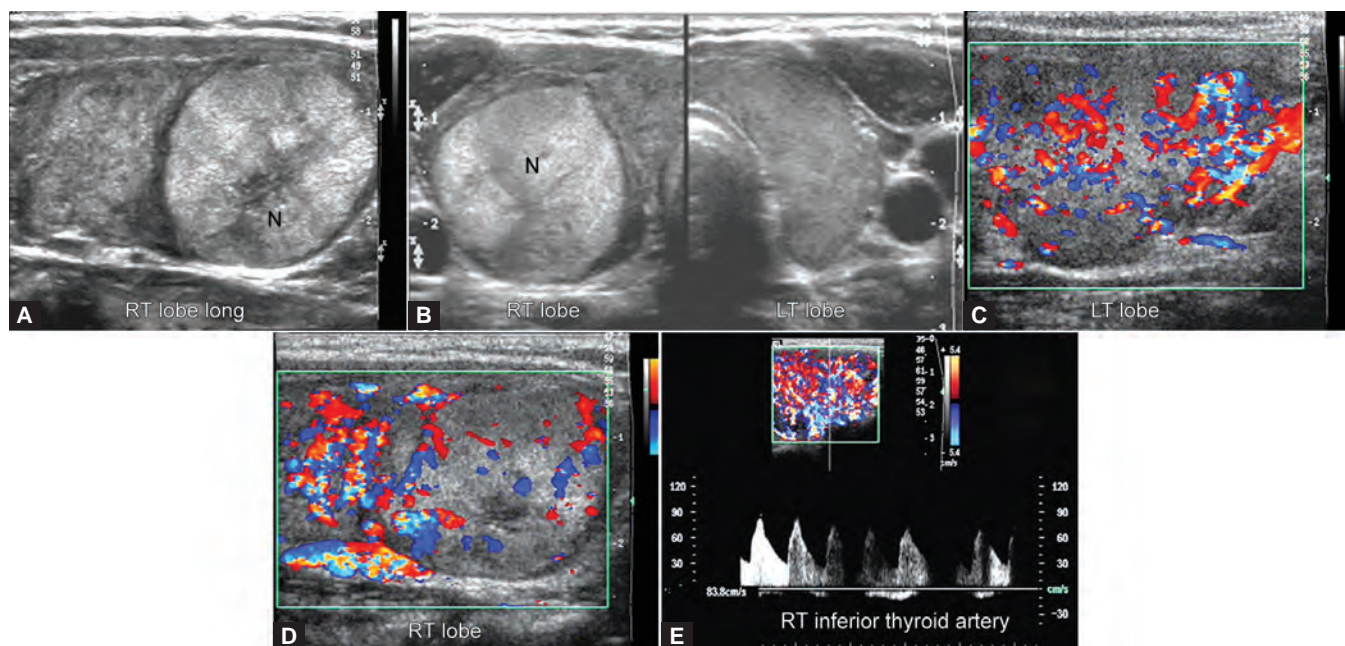


**Figs 17A to D:** A 55-year-old female presented with a large swelling in the neck with breathlessness. Ultrasonography shows (A to C) (enlarged left lobe of thyroid gland with a nodule extending inferiorly below the sternum suggesting possibility of retrosternal extension) and (D) shows a large multinodular goiter

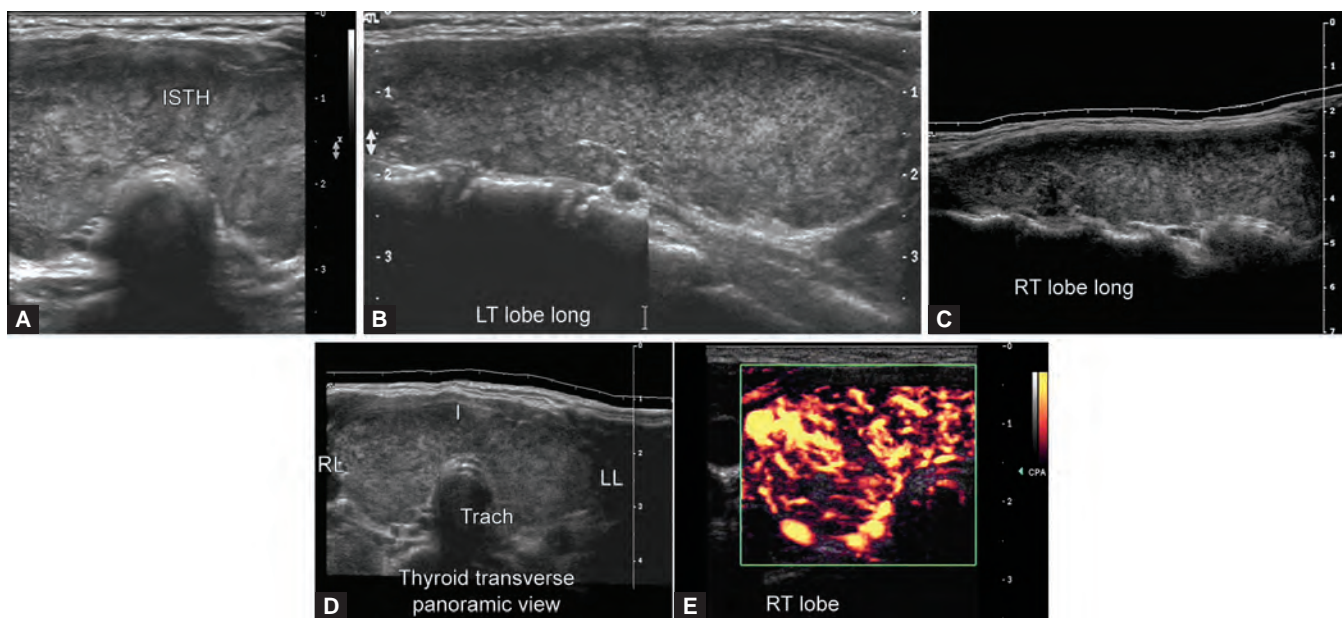
## INFLAMMATORY AND INFECTIVE CONDITIONS INVOLVING THE THYROID GLAND



**Figs 18A to D:** (A and B) there are multiple hypoechoic ill-defined lesions seen involving the right and left lobe of thyroid gland, (C and D) power Doppler images showing increased vascularity within them confirming thyroiditis. She was 35-year-old female with painful swelling in the neck. Biochemistry showed increased levels of T3 and T4

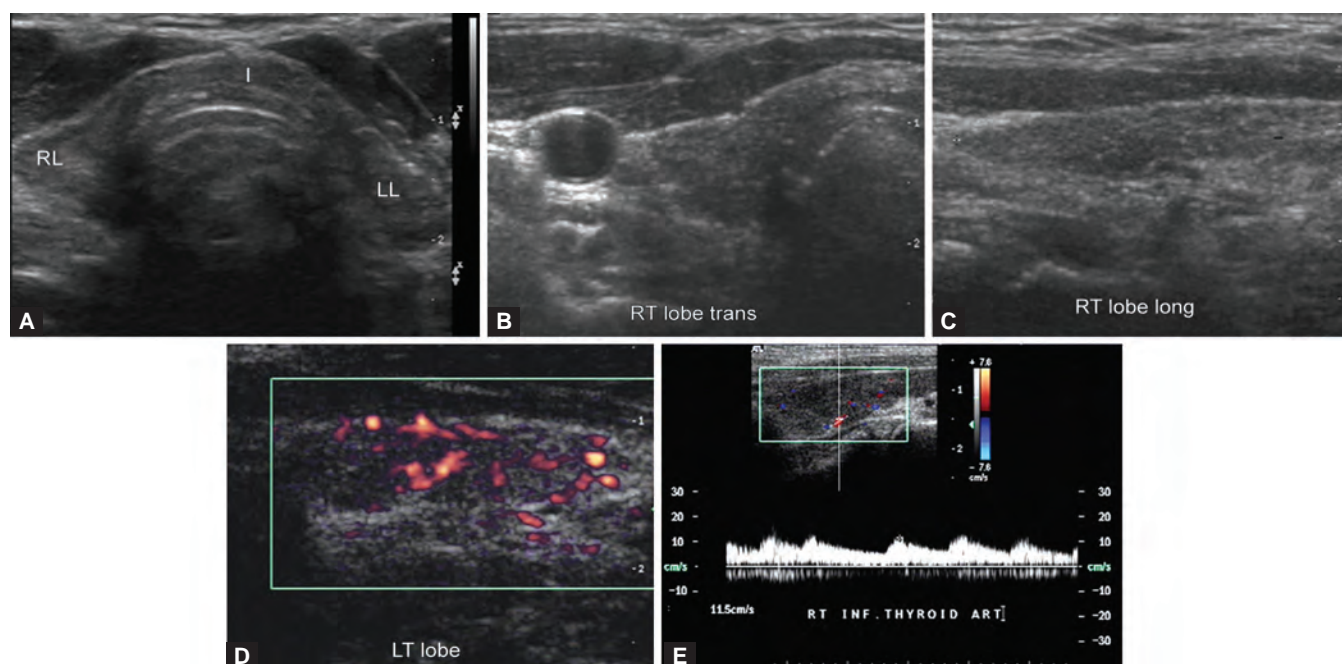


**Figs 19A to E:** A 40-year-old female known case of hyperthyroidism on treatment. Biochemistry showed increased levels of T3 and T4: (A) longitudinal B-mode image of right lobe with an iso-hyper-reflective nodule within the mid—lower pole of right thyroid gland, (B) panoramic image showing multiple nodules within right and left lobe of gland, (C and D) show color Doppler images with diffuse vascularity within the gland and nodules and (E) shows spectral Doppler in the inferior thyroid artery with high PSV of 83.8 cm/sec

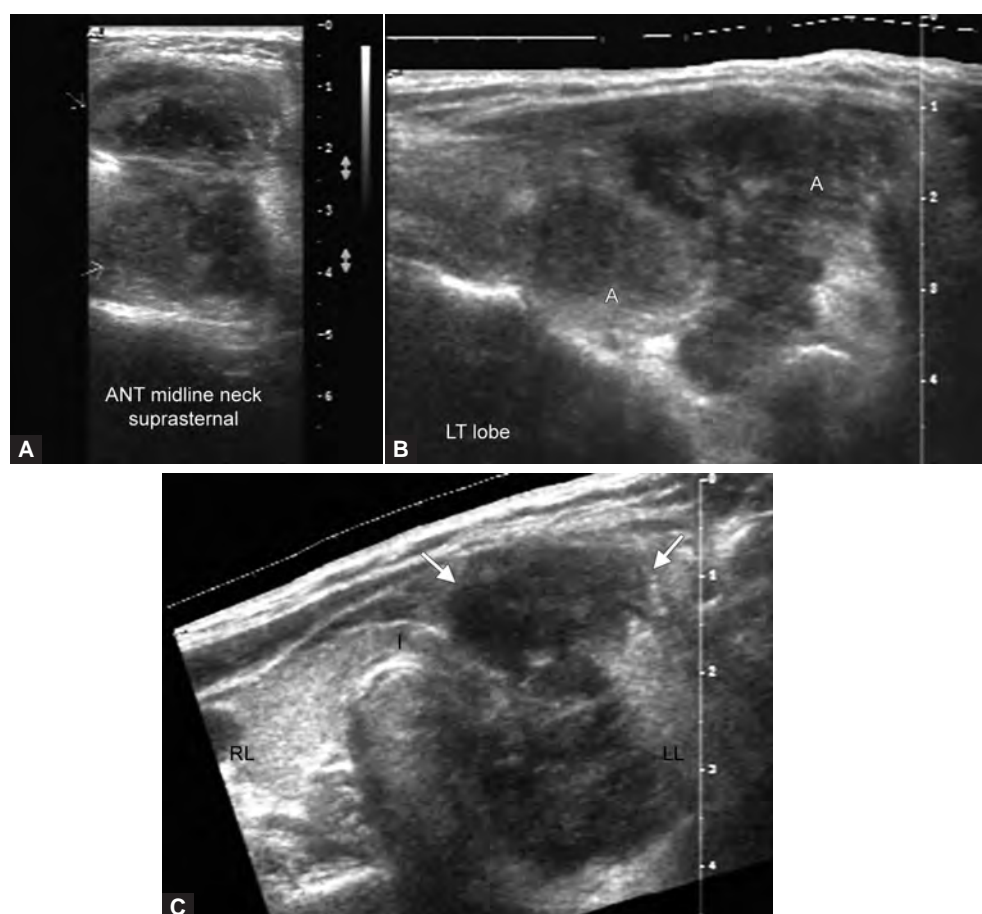


**Figs 20A to E:** A 45-year-old female with painless swelling in the neck. Her biochemistry showed decreased levels of T3 and T4 levels with increased TSH levels diagnostic of hypothyroidism: (A) shows enlarged lobes of thyroid gland with bulky isthmus (B and C) show enlarged right and left lobes with hypoechoic coarse and inhomogeneous gland echotexture. Micronodules seen within the gland, (D) panoramic view of the gland and (E) power Doppler image showing increased vascularity within the right lobe (above imaging features classic for Hashimoto's thyroiditis)

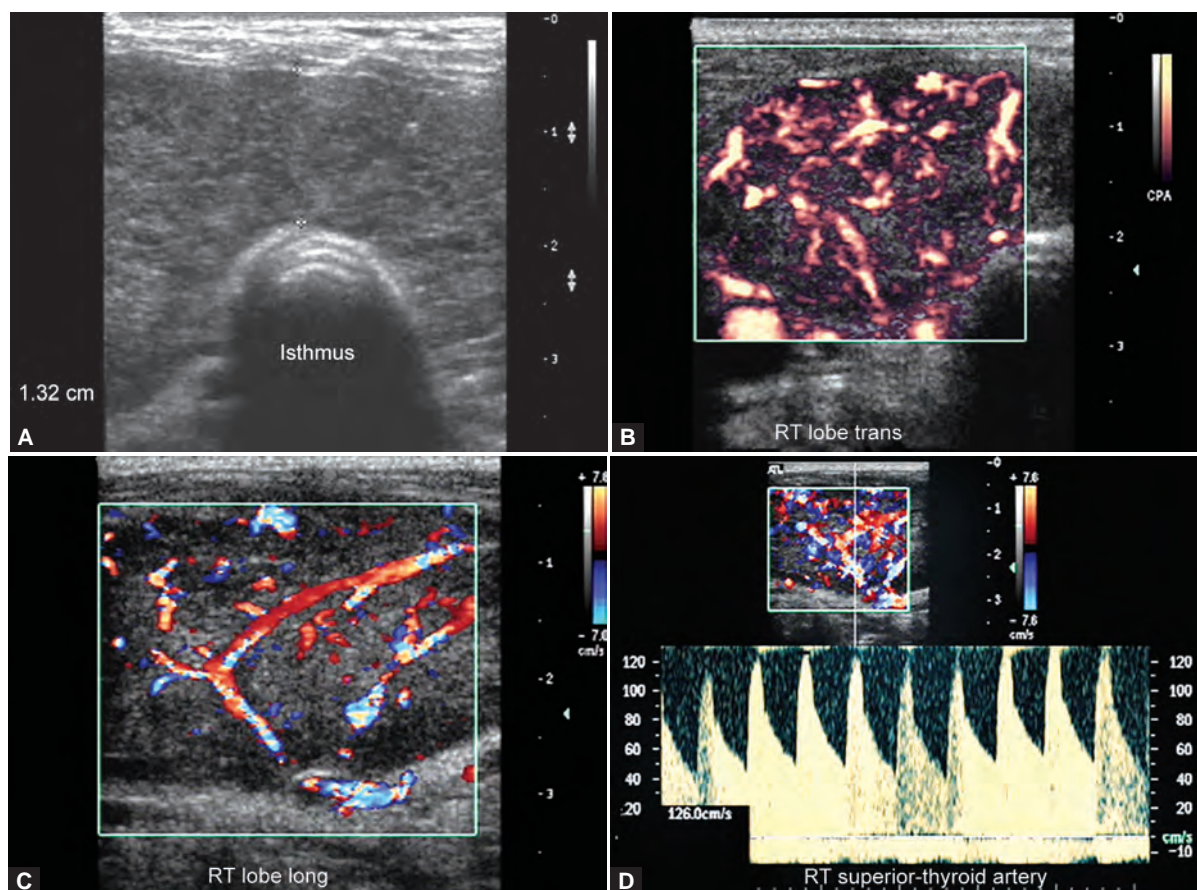




**Figs 21A to E:** A 49-year-old female with past history of thyroiditis came for follow-up scan. Patient is at present hypothyroid: (A) shows small sized coarse bilateral lobes and (B and C) show small sized coarse longitudinal and transverse images of right lobe with the gland appearing inhomogeneous, (D) power Doppler image showing increased vascularity consistent with chronic thyroiditis and (E) shows spectral Doppler in the inferior thyroid artery with low PSV of 11.5 cm/sec



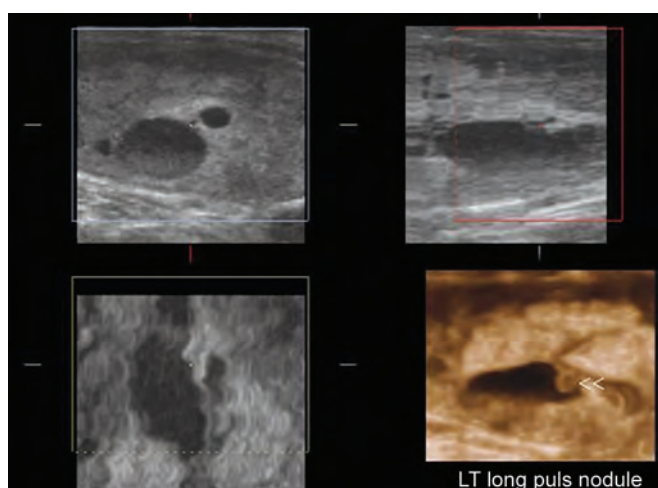
**Figs 22A to C:** A 20-year-old female with history of swelling in the midline aspect of neck in the suprasternal region: (A) shows ultrasonography image in the midline neck in the suprasternal region a hypoechoic cystic lesion with internal echoes consistent with a cold abscess (proven with diagnostic aspiration), (B) shows all illdefined hypoechoic lesion seen in the left lobe of thyroid gland which showed continuity and extension into the midline swelling and (C) shows extrathyroidal extension of lesion along the anterior triangle and subcutaneous soft tissues. Subsequent FNAC in the left lobe lesion showed caseating granulomas in the smear consistent with tuberculous involvement (thyroid involvement in kochs)



**Figs 23A to D:** A 25-year-old female diagnosed case of grave's disease clinically: (A) shows B-mode USG image showing enlarge hypoechoic coarse and inhomogeneous gland, (B and C) show power and color Doppler images showing increased vascularity, (D) shows spectral Doppler in the superior thyroid artery with high PSV of 126 cm/sec. Follow-up scan postmedical treatment showed decrease in the vascularity of the gland

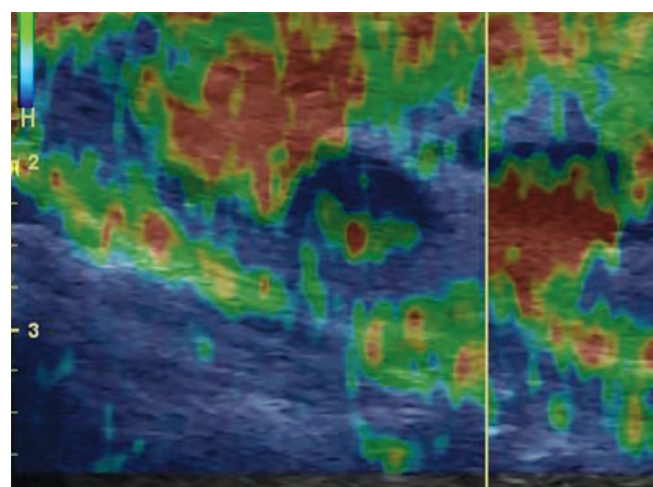
## FUTURE PROMISES IN THYROID USG IMAGING

### 3D Imaging of Thyroid Gland



**Fig. 24:** Benign thyroid nodule—colloid nodule on 3D imaging

## THYROID ELASTOGRAPHY



**Fig. 25:** The red and green areas suggest soft tissue in the nodule which occupies the entire left lobe. The blue regions in the mass suggest potential malignant changes due to brittle or hard tissue