

Extramedullary Plasmacytoma of Head and Neck Region: Report of Six Cases with Different Localizations

Kerem Öztürk, Mustafa Şahin, Raşit Midilli, Gülce Gürsan, Nazan Özsan, Recep Savaş

ABSTRACT

Extramedullary plasmacytoma (EMP) is a rarely seen neoplasm of plasma cells which may be locally destructive by involving submucosal soft tissues of upper respiratory tract but without systemic dissemination. It comprises less than 1% of head and neck malignities. Clinical presentation depends on tumor's effect and its involvement site. Diagnosis is made with histopathologic examination of tissue biopsy. Responses to its treatment with local radiotherapy and surgery are similar. In this article; it is intended to update our knowledge regarding EMP and remind this rarely encountered disease by presenting various cases detected in nasopharynx, tonsil, buccal mucosa, larynx, mastoid cavity and sphenoid sinus, with literature line.

Keywords: Extramedullary plasmacytoma, Head and neck.

How to cite this article: Öztürk K, Şahin M, Midilli R, Gürsan G, Özsan N, Savaş R. Extramedullary Plasmacytoma of Head and Neck Region: Report of Six Cases with Different Localizations. *Int J Otorhinolaryngol Clin* 2013;5(3):157-163.

Source of support: Nil

Conflict of interest: None declared

INTRODUCTION

As a disease of unknown etiology, EMP is the neoplasm of plasma cells which may be locally destructive by involving 80% of submucosal soft tissues of upper respiratory tract but without systemic dissemination, it is generally seen in males in their 6th to 7th decades and detected in head and neck region.^{1,2} In 90% of all cases, it is localized in head and neck region.³ On the other hand, it is a rare disease which comprises less than 1% of all malignities in this region.⁴ Its diagnosis is made with histopathologic examination and while its treatment depends on the localization and dissemination of disease, solitary lesions are generally treated with radiotherapy (RT) and surgery is considered for local control purposes in diagnostic biopsy and recurrent cases.^{5,6} 5-year survival rate is between 50 and 82% if solitary lesion is present. In this article; solitary EMP cases, which are rarely seen among plasma cell dyscrasias and detected in different localizations, was presented in consideration of literature information and it was intended to keep it in mind for differential diagnosis.

CASE REPORTS

Case 1 (Tonsil Involvement)

In examination of 75 years old male patient, who applied with dysphagia and dysphasia complaints lasting for

7 months, asymmetric hypertrophy and surface disorders at right tonsil, which can be more apparently seen than the other tonsil, were detected (Fig. 1).

Magnetic resonance imaging (MRI) examination after administration of intravenous contrast agent which was isointense relative to adjacent muscle plans at T1A sequence and hyperintense at T2A sequence in left tonsil lodge, revealed apparently contrast enhanced soft tissue mass for which no filtration to the surrounding tissue was observed (Fig. 2).

In whole-body computed tomography (CT) which was performed after it was reported that incisional biopsy, which was removed under anesthesia, is associated with extraosseous plasmacytoma, it was detected that no involvement occurred except tonsil. Given that no other involvement was found in peripheral smear, protein electrophoresis and bone marrow biopsy, this case was evaluated as limited extramucosal plasmacytoma. Tonsillectomy and mass excision were applied to patient for therapeutic purposes.

In pathological examination of mass, submucosal diffuse filtration formed by neoplastic cells with plasmoblastic morphology was detected; in immunohistochemical examination, neoplastic plasma cells, kappa light chain and IgG were found to be positive while Lambda IgD, IgM, IgA, CD3, CD30, CD56 were found to be negative; amyloid was not seen with congo red and latent EBV was not found to be positive (Figs 3A to E). No recurrence was detected in 1 year follow-up of the case.

Case 2 (Buccal Mucosa Involvement)

During examination of a 78 years old male patient who applied to our clinic with swelling and pain complaints at his left cheek, 4 × 3 cm sized massive lesion covered by smooth mucosa was detected in subcutaneous left buccal area. In Ultrasonography (USG) examination, 41×23 mm sized, macrolobule bordered heterogenous hypoechoic solid mass lesion in parotis gland mandibular ramus and masseter muscle adjacencies and partial destruction of bone structure in lesion adjacency were detected. In MRI examination, 35 × 25 mm sized malign mass lesion, which destructs mandibular bone at left retromolar trigon, invades through adjacent masseter muscle and is isohypointense at T1 and T2A images and has marked contrast enhancement in post-contrast images, was detected (Fig. 4).

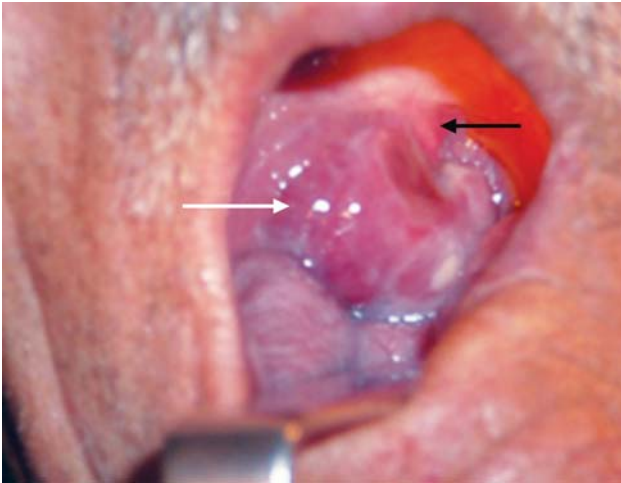


Fig. 1: Asymmetric hypertrophy at right tonsil (white arrow: mass in the right tonsillar fossa, black arrow: uvula)

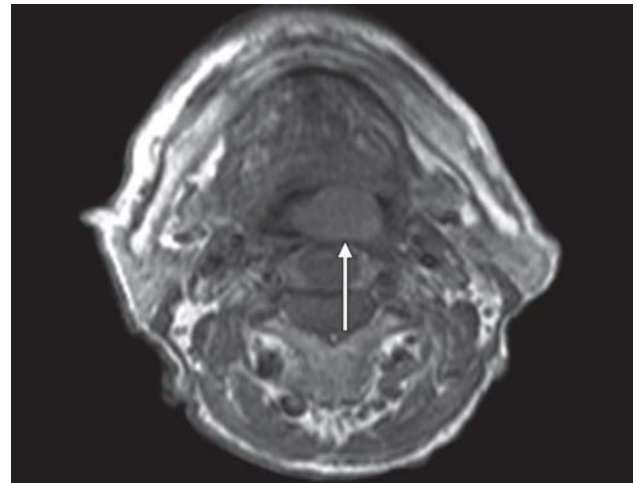


Fig. 2: Isointense mass relative to adjacent muscle planes at T1A sequence (white arrow: mass in the right tonsillar fossa)

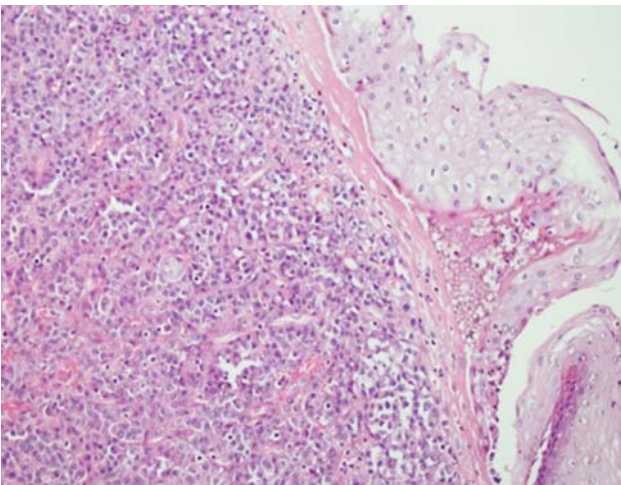


Fig. 3A: Diffuse infiltration formed by plasma cells under epithelium

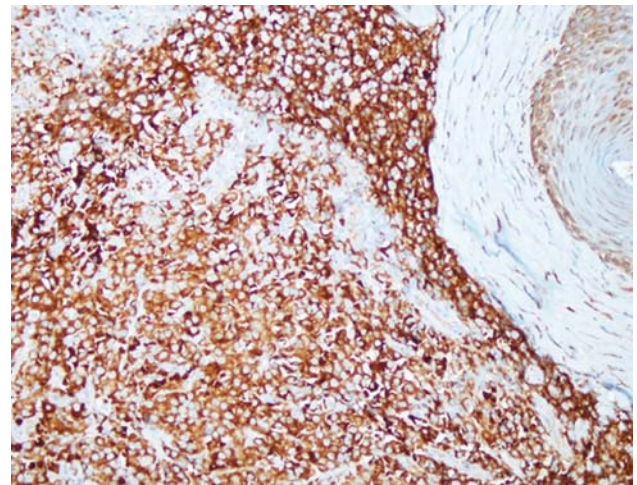


Fig. 3B: Positive with plasma cell marker VS38c (x20)

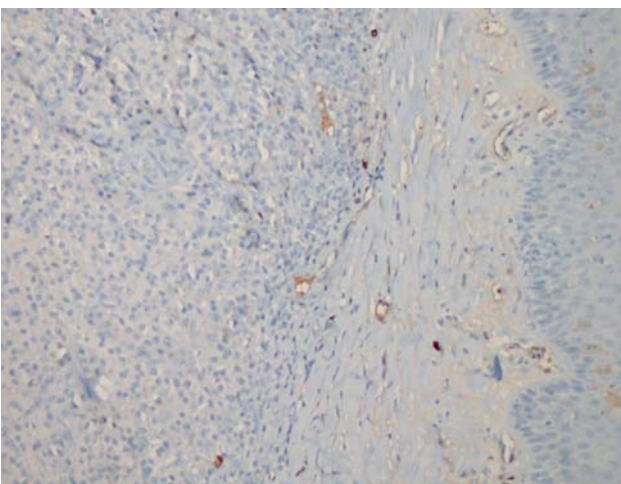


Fig. 3C: Lambda light chain negative (x20)

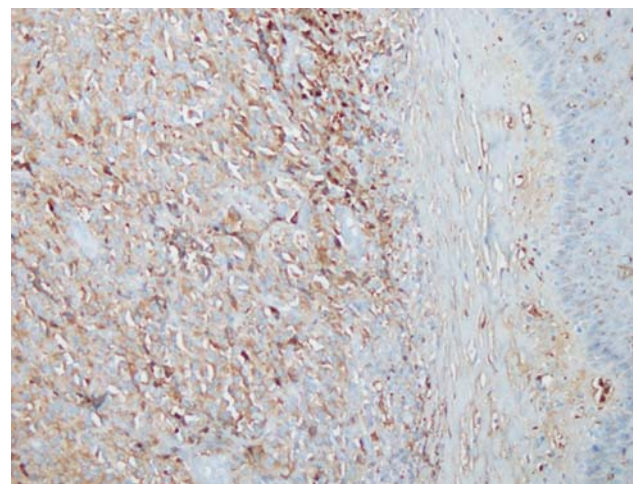


Fig. 3D: Kappa light chain positive (x20)

In CT examination, although 41 × 22 mm sized mass, which expanded bone in the left mandibular ramus causing cortical destruction, was expansile and destructive, it was observed that it did not cause marked invasion to

surrounding soft tissue planes. Since no diagnostic finding was found during deep biopsy examination, which was removed from buccal mucosa by incision, mass biopsy under general anesthesia was reperformed for diagnostic purpose

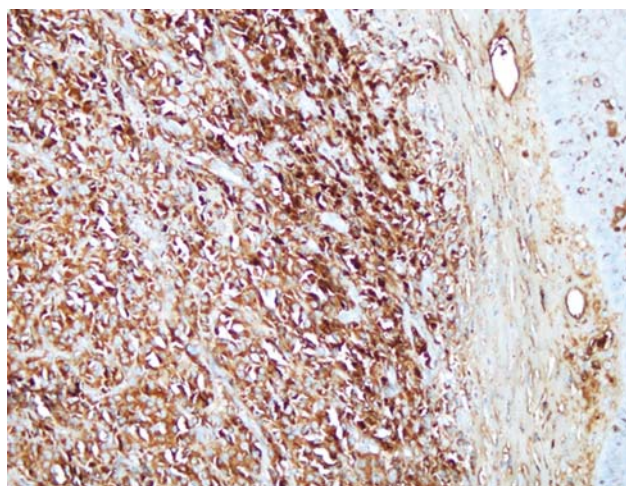


Fig. 3E: IgG heavy chain positive (x20); IgA, IgM, IgD negative

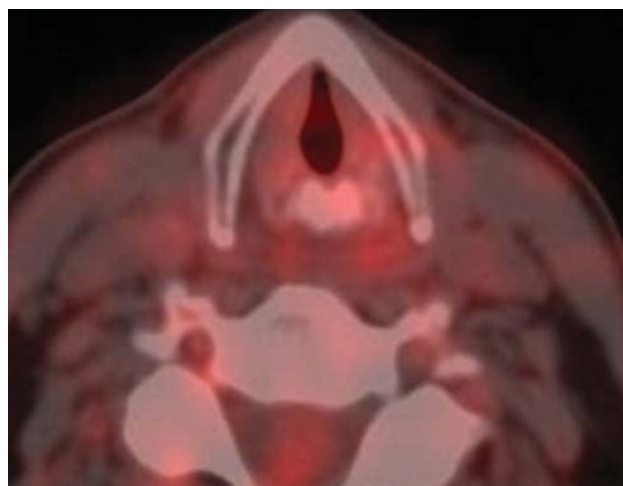


Fig. 6: Regression in post-treatment lesion is shown

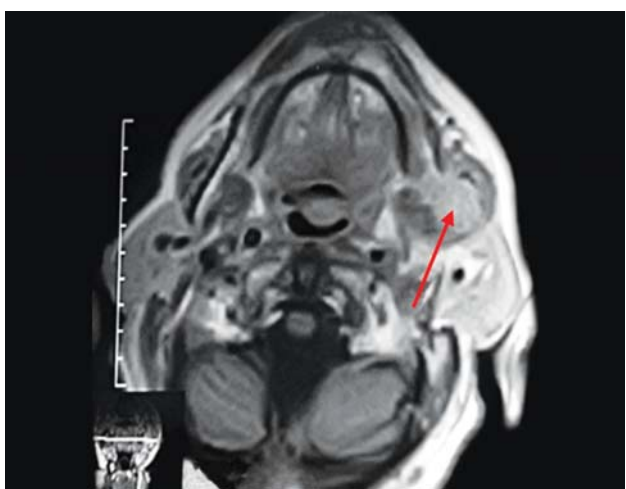


Fig. 4: Mass lesion (shown by red arrow) which expands left mandibular bone, invades through adjacent masseter muscle and has post-contrast enhancement

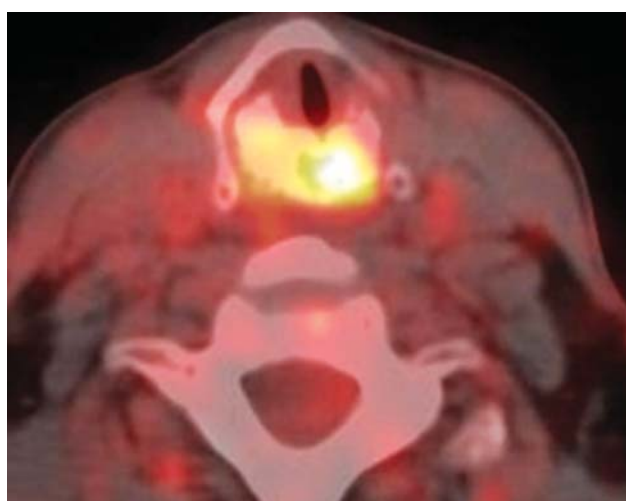


Fig. 5: Pretreatment image of patient with larynx plasmacytoma

by incision starting from submandibular area. In histopathologic examination, diffuse plasma cell infiltration was detected and it was assessed as malign plasmacytoma. Since

no other involvement was detected in peripheral smear, protein electrophoresis and bone marrow biopsy, the case was evaluated as limited EMP at buccal area; 4000 cGray was given to complete the treatment and no recurrence and no other involvement was detected during 1-year follow-up of the patient.

Case 3 (Larynx Involvement)

A 67 years old male patient, who was receiving radiotherapy treatment for plasmacytoma detected in lumbar region 4 years ago, applied with hoarseness and dysphagia complaints lasting for 4 months. In endoscopic larynx examination, movement restriction at right vocal cord and salivary accumulation at right pyriform sinus were detected. In whole-body Positron Emission Tomography-CT (PET-CT) examination, it was found that cricoid cartilage lost its normal morphology, expanded with lytic and sclerotic heterogenous areas and pathologic signal increase occurred in these hypodense and hyperdense areas (Fig. 5) and incisional biopsy was reported as plasmacytoma. The case was evaluated for multiple myeloma, no monoclonal gammopathy was detected in serum and urine. Plasma immunoglobulins IgG, IgA, IgM and beta-2-microglobulin levels were found to be normal and in complete blood count; calcium, creatinin and uric acid levels were found to be normal. Combined radiochemotherapy treatment was applied to the patient who was evaluated as recurrent EMP at different localization. Chemotherapy and 5000 cGy radiotherapy treatment were given to the patient.

Lesion regression was detected at PET-CT examination of patient 6th months after treatment, although no recurrence/progression was detected during his post-treatment follow-up (Fig. 6).

The case did not attend his control visits after 16 months follow-up.

Case 4 (Sphenoid Sinus Involvement)

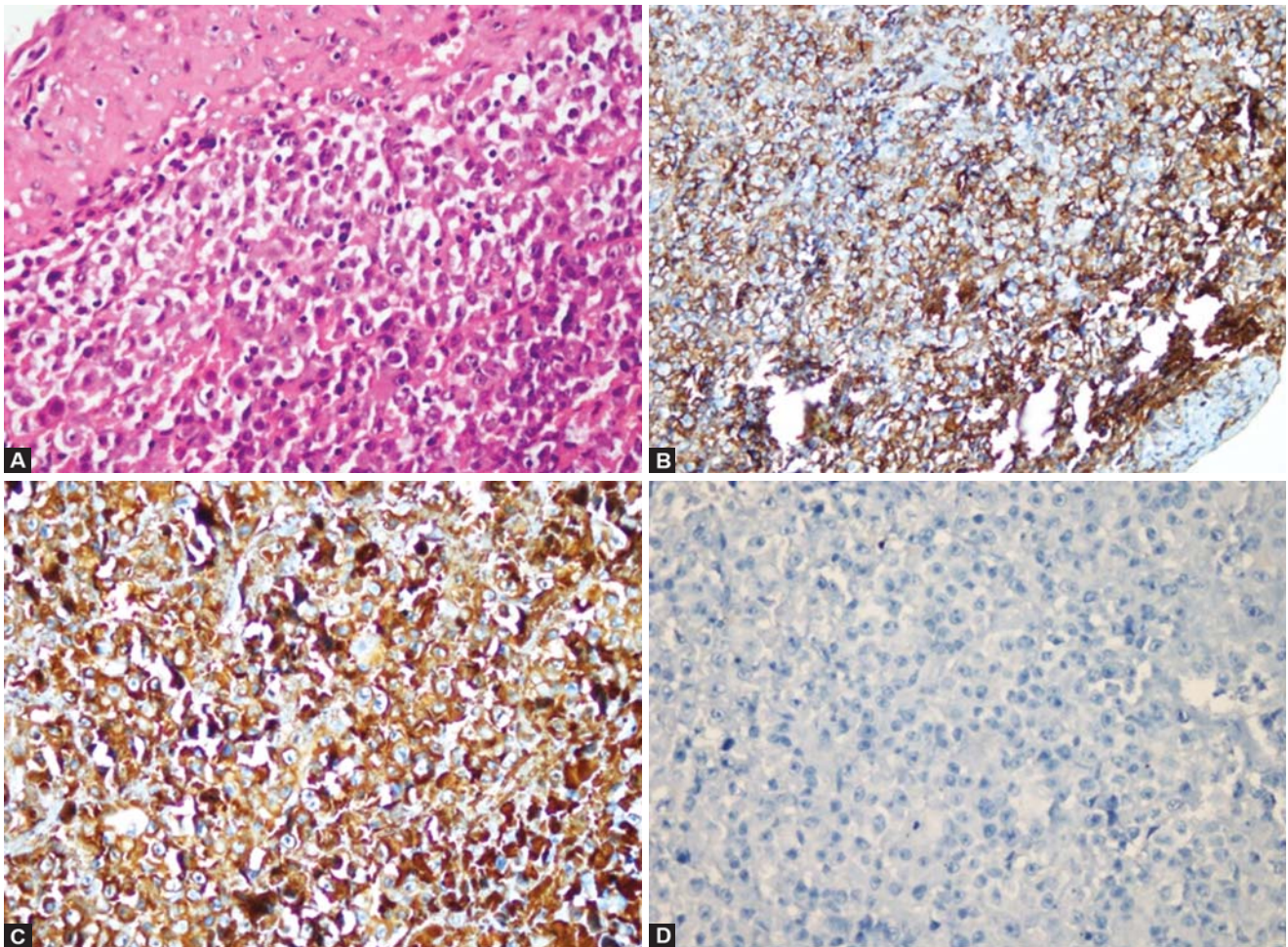
A 73 years old male patient, who was operated due to prostatic carcinoma 3 years ago, applied with headache complaints lasting for 2 months. ENT examination of patient was found to be normal. After the observation of the lesion which causes expansion in clivus, extends to sphenoid sinus at anterior and its margins cannot be discriminated from sphenoid sinus in cranial CT examination of patient; observation of a destructive lesion, which may be associated with Paget disease during early destructive phase, in sphenoid sinus corpus and sphenoid sinus in cranial MRI examination, the patient was consulted. On the other hand during the evaluation of bone structures, moderate signal enhancement was observed on T2A segmental images while these areas were observed at low signal on T1A images.

Following dilatation of sinus ostia by endoscopic sinus surgery, mass in sinus was dissected from surrounding tissues and its histopathologic evaluation was found to be relevant to plasmacytoma. Diffuse neoplastic infiltration formed by atypical plasma cells was observed in this evaluation and almost all of these cells consisted of plasma

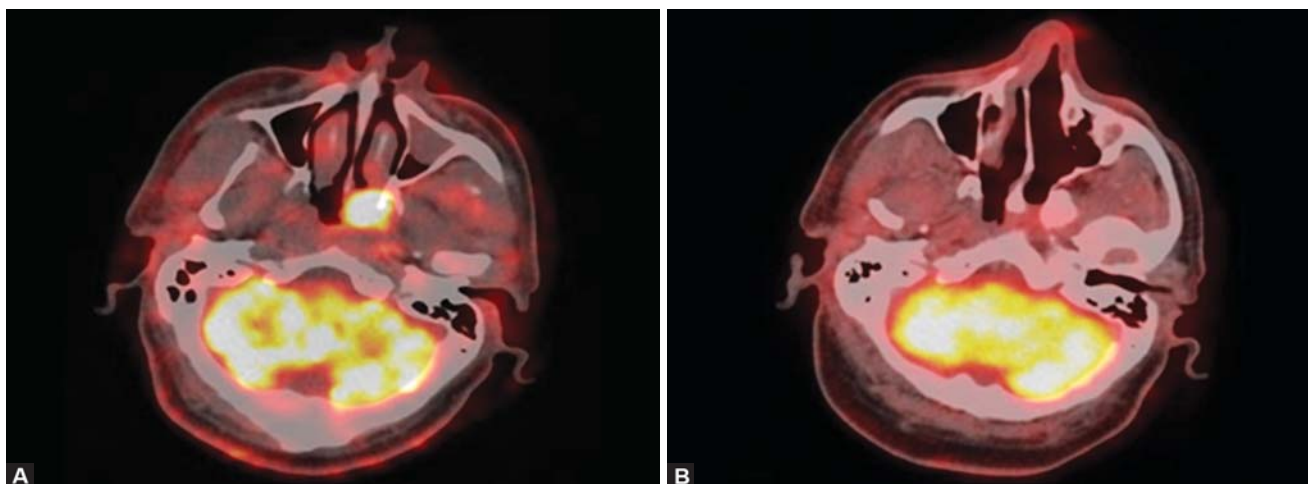
cells with atypical morphology. In immunohistochemical examination, neoplastic plasma cells CD138, lambda and IgG were found to be positive; kappa, IgA, IgD, IgM, CD20, CD3, CD30, cytokeratine, S-100 and PLAP were found to be negative (Figs 7A to D). The case received postoperative 4000 cGray radiotherapy and it was observed that plasmacytoma at sphenoid sinus was regressed. However, the patient was dead due to prostat carcinoma during treatment for its distant metastasis.

Case 5 (Nasopharynx Involvement)

A 55 years old male patient, who applied to an external center with nasal congestion complaints lasting for 1 year, was diagnosed with plasmacytoma and received 3000 cGray radiotherapy, was forwarded to our clinic due to recurrence developed during his follow-up. In his ENT examination, soft tissue lesion, presumably originating from nasopharynx, extending through posterior left nasal cavity was observed. Biopsy was reassessed as plasmacytoma. After no pathology relevant to multiple myeloma was detected in hemogram, peripheral smear and bone marrow biopsy, endoscopic



Figs 7A to D: (A) Infiltration caused by plasma cells under epithelium ($\times 40$) hematoxylin and eosine (H&E), (B) positive with plasma cell marker CD138 ($\times 20$), (C) lambda light chain positive ($\times 40$), (D) kappa light chain negative ($\times 40$)



Figs 8A and B: It was observed in PET/CT examination 6 months following the end of treatment that lesion at posterolateral wall of nasopharynx was regressed: (A) pretreatment, (B) post-treatment

surgery excision was applied. During surgery, it was found that mass eroded sphenoid sinus base but did not invade into it. In histopathologic examination, plasma cell infiltration with atypical morphology which formed submucosal mass relevant to plasmacytoma; in immunohistochemical examination, neoplastic plasma cells kappa light chain and IgA were found to be positive while lambda, IgD, IgG, IgM and CD56 were found to be negative. No amyloid accumulation was detected by histochemical examination with congo red. No pathologic signal increase was detected at tumor localization in post-treatment PET-CT examination of patient (Figs 8A and B). No recurrence finding was obtained during 2 years period from the end of treatment up to present.

Case 6 (Temporal Bone Involvement)

In ENT (ear, nose, throat) examination of 52 years old male patient who applied with tinnitus and pain complaints of left ear lasting for 7 months, edematous and hyperemic area was observed at posterior external auditory canal. In CT examination, approximately $6 \times 4 \times 3$ sized solid tumoral massive lesion, which has presumably malign nature, was observed. It was found that his lesion caused erosive destructive changes on temporal bone adjacent to right half of posterior fossa, formed destruction on bone structures at right half of skull base extending through right middle ear and external auditory canal and also caused thickening of right half of occipital bone (Fig. 9).

In cranial and neck MRI examination, an invasive tumoral mass lesion, which is hyperintense at T2 sequences, forms destruction in right temporal bone clivus and basioccipital. After mastoidectomy, which was performed for diagnostic purposes and histopathologic examination of biopsy removed from mass, was evaluated as plasmacytoma,

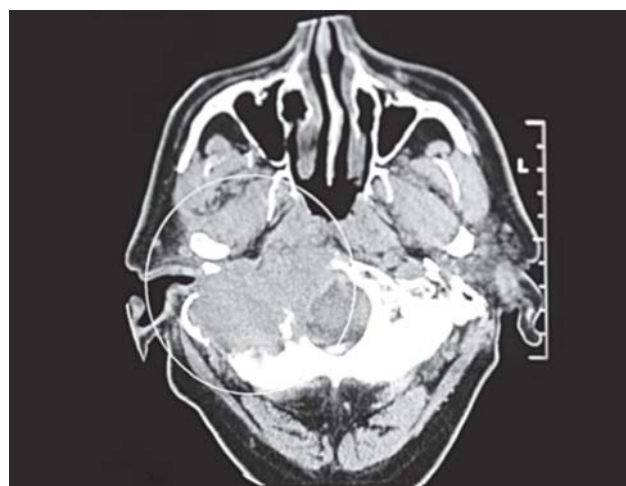


Fig. 9: $6 \times 4 \times 3$ cm sized malign mass, extending through middle ear and external auditory canal, caused erosive destructive changes on temporal bone adjacent to right half of posterior fossa (shown in the white circle)

4500 cGray radiotherapy treatment was given to the patient. It was found during follow-up that the patient, whose treatment completed 18 months ago, responded to treatment and the lesion regressed.

DISCUSSION

EMP, originating from B lymphocytes, is a rarely seen neoplasm of plasma cells which may be locally destructive by metastating through 80% submucosal soft tissues of upper respiratory tract but without systemic dissemination.^{1,2} It comprises less than 1% of head and neck malignities and its annual incidence is three per 100,000.²⁻⁶ Incidence is three times more in males and seen more in age group of 40 to 70.³ All of our cases include aged male patients, which is consistent with literature. EMP is a slowly growing tumor and thus diagnosis is often made during late-stage. Clinical

presentation depends on tumor's effect and its involvement site.⁷ In most of our case reports, complaints were localized in involved area and symptom durations ranged from 1.5 months to 1 year. Diagnosis of most cases was delayed since researches in different external centers gave no results. It often involves nasal or nasopharyngeal areas (75%), larynx (18%) and oropharynx (12%). Rare tongue, tonsils, small salivary glands, posterior pharyngeal wall, thyroid, parathyroid, middle ear, colon and liver involvements were reported in literature.^{4,8-15} Localizations of our case reports are tonsil, buccal region, larynx, sphenoid sinus, nasopharynx and mastoid. Only diagnosis method to detect tumor is biopsy showing plasma cell infiltration.¹⁶ However, submucosal dissemination is typical for EMP in upper respiratory tract.¹⁷ Thus deep biopsy should be necessarily taken. In histological appearance of lesion, it consists of monomorphic layer of plasma cells placed in capillary stroma without inflammatory cells and cells at different maturations with eccentric nucleus chromatin.¹⁷ During histopathological examination of biopsies from lesions of our cases, we observed plasma cell infiltration which forms submucosal mass and has atypical morphology; in immunohistochemical examination, we detected positive neoplastic plasma cells, kappa light chain and IgA. Since EMP findings are available at peripheral blood, biochemical examinations are generally normal.⁷ Our cases were also studied for multiple myeloma, no monoclonal gammopathy was detected in serum and urine. Plasma immunoglobulins IgG, IgA, IgM, ve beta-2-microglobulin levels were found to be normal and calcium, creatinine and uric acid levels were observed as normal in complete blood count. There is no CT and MR findings of solitary plasmacytomas. Imaging findings depend on area of the lesion. Lesions adjacent to bone progress with bone destruction while lesions adjacent to soft tissue progress submucosally. On MR imaging as a common characteristic for various masses, it was observed hyperintense appearance at T2 sequences and hypointense appearance at T1 sequences. The treatment of EMPs is radiotherapy or conservative surgery followed by radiotherapy.^{6,8} Nofsinger et al suggested that radiotherapy should be the primary option while surgery should be preferred for the cases which cannot be treated by radiotherapy. On the other hand, Sisson and Goldstein suggested that local excision should be performed if possible and radiotherapy should be preferred for recurrent cases.¹⁸ We obtained successful results with surgery for our patients—except one who had larynx and mastoid involvement disseminating through skull base on whom we applied basically radiotherapy, since surgical excision and surgical resection cannot be performed as first-line treatment

for our cases with tonsil, sphenoid sinus and nasopharynx involvement given that RT has an alternative option, does not have long term complications and places in excisable localizations. In literature, recommended dose for radiotherapy is 4000 to 5000 cGY in conventional fractions and around 77 to 90% local control can be provided at this dose level.^{8,19} 4000, 4500 and 5000 cGY RT were applied to our cases. Post-treatment 10-year survival is 70% for EMPS.¹⁹ Only one of our cases receiving treatment was dead due to prostate cancer for which he was being followed, one of them is lost to follow-up and follow-ups of other cases still continue. The most important factor determining prognosis is not local recurrence, but multiple myeloma development.²⁰ Although it was reported in literature that multiple myeloma was developed by 10 to 40% during follow-up of patients with EMP, multiple myeloma has not yet seen among our patients.¹⁹ However, multiple myeloma case, which occurred 28 years after treatment of solitary lesions, was reported.¹⁷ Thus, long-term follow-up of patients is required.

CONCLUSION

Even though solitary EMP is a rarely seen situation among plasma cell dyscrasias and its diagnosis is quite difficult, it should be kept in mind for differential diagnosis, should be confirmed by biopsy when required and an appropriate treatment should be assigned.

REFERENCES

1. Galiani P, et al. Clinical outcome of extramedullary plasmacytoma. *Haematologica* 2000;85:47-51.
2. Meis JM, Butler JJ, Osborne BM, Ordonez NG. Solitary plasmacytomas of bone and extramedullary plasmacytomas. A clinicopathologic and immunohistochemical study. *Cancer* 1987;59:1475-1485.
3. Helmus C. Extramedullary plasmacytoma of the head and neck. *Laryngoscope* 1964;74:553-559.
4. Susnerwala S, et al. Extramedullary plasmacytoma of the head and neck region: Clinicopathological correlation in 25 cases. *Br J Cancer* 1997;75: 921-927.
5. Rodriguez A, Montgomery W, Weber AL. Extramedullary laryngeal plasmacytoma. *Ann Otol Rhinol Laryngol* 1996;105: 483-486.
6. Kapadia SB, Desai U, Cheng VS. Extramedullary plasmacytoma of the head and neck: a clinicopathologic study of 20 cases. *Medicine* 1982;61:317-329.
7. Attanasio G, Viccaro M, Barbora M, Deseta E, Filippo R. Extramedullary plasmacytoma of paranasal sinuses. A combined therapeutic strategy. *Acta Otorhinolaryngol Ital* 2006;26: 118-120.
8. Michalaki VJ, Hall J, Henk JM, Nutting CM, Harrington KJ. Definitive radiotherapy for extramedullary plasmacytomas of the head and neck. *Br J Radiol* 2003;76:738-741.

9. Wax MK, Yun KJ, Omar RA. Extramedullary plasmacytomas of the head and neck. *Otolaryngol Head Neck Surg* 1993; 109:877-885.
10. Hidaka H, Ikeda K, Oshima T, Ohtani H, Suzuki H, Takasaka T. A case of extramedullary plasmacytoma arising from the nasal septum. *J Laryngol Otol* 2000;114:53-55.
11. Bhimani S, Griffin W, Virapongse C, Altmeyer V, Kier EL. CT findings in a nasopharyngeal extramedullary plasmacytoma. *J Comput Assist Tomogr* 1983;7:1081-1083.
12. Jaffe ES, Harris NL, Diebold J, Hermelink HKM. World Health Organization Classification of neoplastic diseases of the hematopoietic and lymphoid tissues: a progress report. *Am J Clin Pathol* 1999;111:8-12.
13. Rothfield RE, Johnson JT, Staurides A. Extramedullary plasmacytoma of the parotid. *Head Neck* 1990;12:352-354.
14. Weichhold W, Labouyrie E, Merlio JP, Masson B, de Mascarel A. Primary extramedullary plasmacytoma of the liver: a case report. *Am J Surg Pathol* 1995;19:1197-1202.
15. Ligato S, El-Naggar A, Cleary KR, Manning J. Extramedullary plasmacytoma mimicking primary colonic carcinoma in a patient with Crohn's disease: case report and literature review. *Arch Pathol Lab Med* 1996;120: 279-282.
16. Rawson AS, Eyler P, Horn RC JR. Plasma cell tumors of the upper respiratory tract. A clinico-pathologic study with emphasis on criteria for histologic diagnosis. *Am J Pathol* 1950;26: 445-461.
17. Wiltshaw E. The natural history of extramedullary plasmacytoma and its relation to solitary myeloma of bone and myelomatosis. *Medicine* 1976;55:217-238
18. Soesan M et al. Extramedullary plasmacytoma: clinical behavior and response to treatment. *Ann Oncol* 1992;3:51-57
19. Wasserman TH. Myeloma and plasmacytomas. In: Perez CA, Brady LW, editors. *Principles and Practice of Radiation Oncology*. 3th ed. Philadelphia Lippincott-Raven Publishers. 1997. p. 2013-2023.
20. Sosna J, Slasky BS, Paltiel O, Pizov G, Libson E. Multiple myeloma involving the thyroid cartilage: case report. *Am J Neuroradiol* 2002;23:316-318.

ABOUT THE AUTHORS

Kerem Öztürk

ENT Specialist, Department of Otolaryngology, Faculty of Medicine Ege University, Bornova, İzmir, Turkey

Mustafa Şahin

ENT Specialist, Department of Otorhinolaryngology, Dişkapi Yıldırım Beyazıt Training and Research Hospital, Ankara, Turkey

Correspondence Address: 684.sokak 12/3 Hilal Mahallesi, Çankaya Ankara, Turkey, Phone: 905336545502, e-mail: iskebaha@gmail.com

Raşit Midilli

Associate Professor, Department of Otolaryngology, Faculty of Medicine, Ege University, Bornova, İzmir, Turkey

Gülce Gürsan

Department of Otolaryngology, Faculty of Medicine, Ege University Bornova, İzmir, Turkey

Nazan Özsan

Specialist, Department of Pathology, Faculty of Medicine, Ege University, Bornova, İzmir, Turkey

Recep Savaş

Professor, Department of Radiology, Faculty of Medicine, Ege University, Bornova, İzmir, Turkey