

Osteochondroma of the Parapharyngeal Space: A Rare Case Report

Ashok Kumar Gupta, Darwin Kaushal, Karan Gupta, Kim Vaiphei

ABSTRACT

Extraskelatal osteochondroma in parapharyngeal space is very rare. It is important to note that such a diagnosis be considered when a discrete, ossified mass is localized in soft tissues, even at atypical sites. Its diagnosis is based on radiological and histopathological examination. We should be clinically aware of this benign entity as no malignant transformation or metastasis has been reported. Excision with adequate cuff of tissue is treatment of choice. We did not encounter any case report of osteochondroma in the parapharyngeal space in literature, with our best possible effort.

Keywords: Parapharyngeal space, Oropharynx, Tumors, Osteochondroma.

How to cite this article: Gupta AK, Kaushal D, Gupta K, Vaiphei K. Osteochondroma of the Parapharyngeal Space: A Rare Case Report. *Int J Otorhinolaryngol Clin* 2013;5(3):142-144.

Source of support: Nil

Conflict of interest: None declared

INTRODUCTION

Parapharyngeal space tumors are not very frequent, accounting for some 0.5% of neoplasms of head and neck. Most of these tumors (70-80%) are benign and 40 to 50% of these originate in the salivary glands.¹ Osteochondroma or osteocartilaginous exostosis is one of the most common benign tumors of long bones. It is rarely found in facial skeleton.² In head and neck region it has been reported in cranial base, posterior surface of maxilla, maxillary sinus and different areas of mandible including condyle, coronoid process, ramus, body and symphysis.³ Osteochondroma arising in the parapharyngeal space is extremely rare which made us to report this case.

CASE REPORT

A 50-year-old male presented with gradually progressive painless swelling of the right upper neck for 1 year and change in the quality of voice of 3 months duration. Patient also complaint of difficulty in swallowing for last 45 days. Neck examination revealed a 15 × 9 firm swelling in the right upper neck. Swelling was nonpulsatile, nonfluctuant, noncompressible (Fig. 1). On intraoral examination tongue was deviated to right. There was a smooth firm bulge of the right lateral pharyngeal wall pushing uvula to opposite side. The swelling was bimanually palpable and ballotable.

Clinical examination did not reveal involvement of any of the cranial nerves except hypoglossal nerve.

With a clinical diagnosis of parapharyngeal space tumor, a computed tomographic (CT) scan was taken which showed homogenously enhancing tumor measuring 15 × 9 cm in the right parapharyngeal space, extending from skull base to the thyroid cartilage. Tumor was bulging in oropharynx and hypopharynx with cortical destruction of hyoid bone (Fig. 2).

Fine needle aspiration cytology was consistent with pleomorphic adenoma. Transcervical approach was used to gain access to the right parapharyngeal space; the tumor was completely excised. On gross examination, the lesion was 15 × 7 cm with a whitish, lobulated and glistening surface (Fig. 3).

Histopathological examination showed two well-defined firm lobulated irregular masses, larger one measured 10 × 7 × 6 cm. Cut sections of the mass showed variegated areas, which were predominantly solid with cystic and hemorrhagic areas. Solid component showed myxoid areas. The smaller piece measured 5 × 4 × 3 cm. Cut sections of which revealed large areas of myxoid component and hemorrhages. Microscopic examination revealed a well encapsulated lobulated mass adherent at one focus to a large sized vein encircled by fibrofatty tissue. The tumor was dominantly composed of islands of benign chondroid cells with abundant amount of myxoid stroma along with large areas of endochondral ossification and hyalinization (Figs 4A and B). No atypia or any epithelial component was identified. Postoperative period was uneventful.

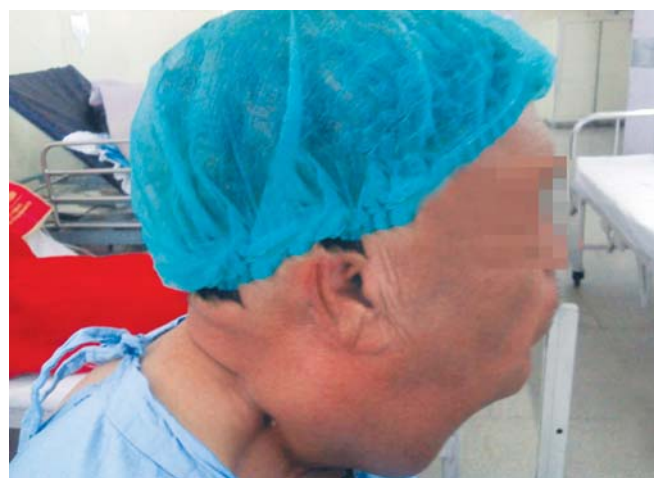

Fig. 1: Lateral view of the patient with a firm, nonpulsatile, nonfluctuant, noncompressible swelling on the right side of neck

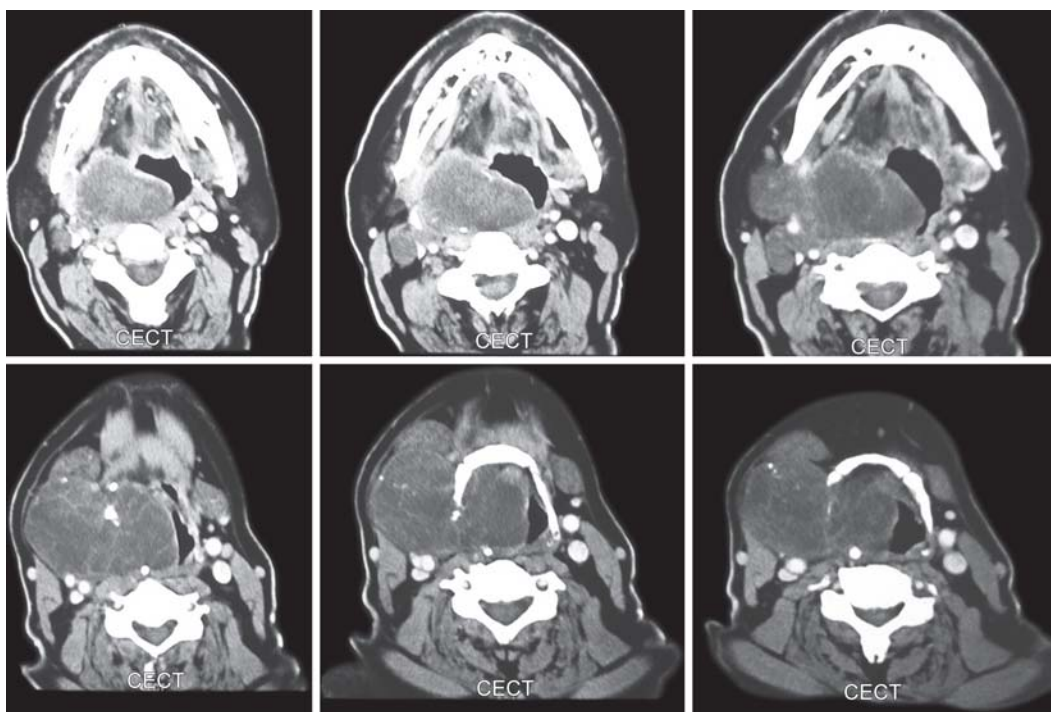


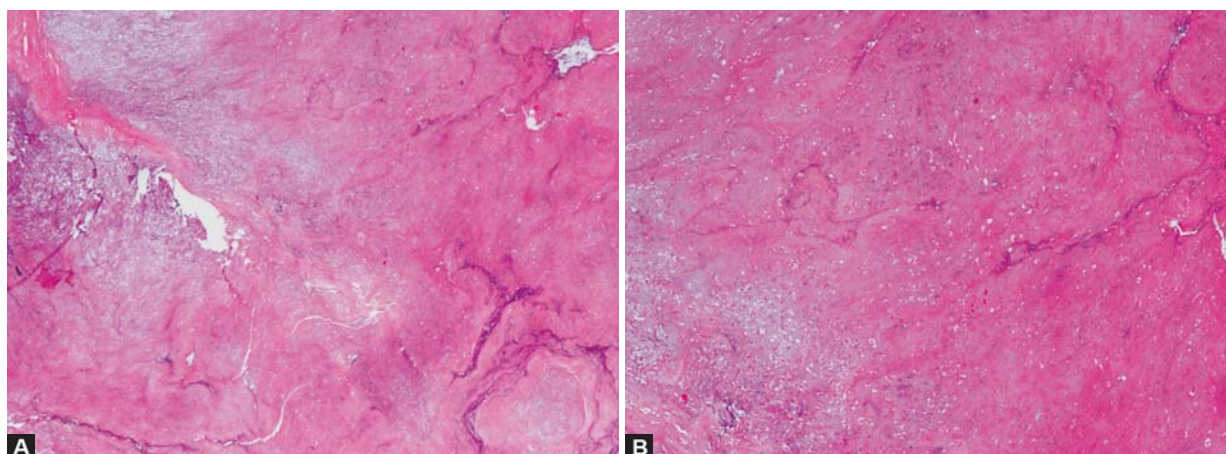
Fig. 2: Contrast-enhanced computed tomography (CECT) BOS to T4 (axial cut) showing homogeneously enhancing mass involving the parapharyngeal space with bulge in the oropharynx and hypopharynx with cortical destruction of hyoid bone

DISCUSSION

Osteochondroma which is a common tumor of axial skeleton is rare to see in maxillofacial region. It can occur at base of the skull, maxillary sinus, zygomatic arch and mandible.⁴ In the review of literature, we did not encounter any case report of parapharyngeal osteochondroma. The parapharyngeal space is however, a complex anatomic region located between the mandibular ramus and lateral pharynx and extending as an inverted pyramid from the skull base superiorly to hyoid bone inferiorly. Within this potential space are cranial nerves IX, X, XI and XII, the sympathetic chain, carotid artery, the jugular vein and lymph nodes. Due to the PPS's anatomic complexity, location and

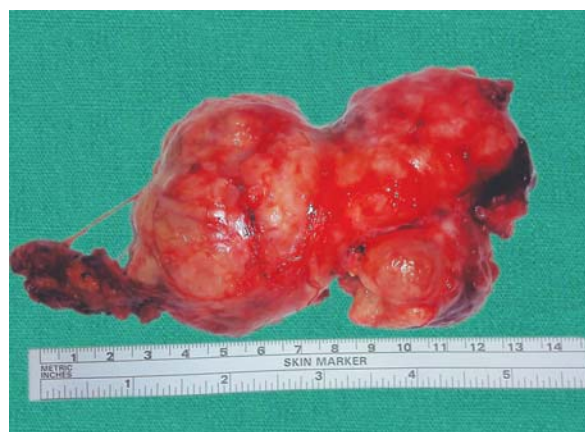

Fig. 3: A 15 x 7 cm whitish, lobulated, glistening mass present on gross examination



Figs 4A and B: (A) Low power photomicrograph of the mass showing lobulated tumor comprising of cartilage seen as blue colored tissue and osteoid seen as pinkish color closely intermixed together (H&E, x150), (B) Higher power photomicrograph of the mass where the cartilaginous and osteoid components better with fine line of calcification are seen as darker blue color (H&E, x450)

surrounding vital structures, resection of tumors from this space can prove challenging to the head and neck surgeon. The approach of choice to the parapharyngeal space to allow adequate removal of the tumor should meet two criteria: wide intraoperative visibility for safe radical dissection and minimal functional and or cosmetic after effects.

Osteochondroma is more commonly seen in males, usually less than 40 years of age.³ Though most of the benign tumors of the minor salivary gland in the oral cavity present as a painless submucosal swelling,⁵ those from the parapharyngeal space may show. Classical features of benign parapharyngeal swelling are submucosal swelling in the lateral pharyngeal wall. Additional symptoms can be change in voice, otalgia, neuralgia, palsies of 9th, 10th or 11th cranial nerves or trismus.

CT scan and magnetic resonance imaging (MRI) are important diagnostic tools in tumors of parapharyngeal space. MRI has been shown to be superior to CT in the investigation of parapharyngeal space tumors.⁶ These modalities help in determining the extent of disease, local spread and also help to some extent in determining the type of tumor. Presence of intact fat plane helps in distinguishing benign tumors from malignant ones.

Fine needle aspiration cytology is the modality of choice for diagnosis.⁷ Incision biopsy is never advocated for salivary gland tumor due to danger of seeding of tumor and later on recurrence.

Various surgical approaches are being used for its resection. PPS tumors can be excised using transcervical, transparotid and transoral approaches. Malone et al and Hamza et al^{8,9} described the resection of PPS tumors using the transcervical approach alone in 90 to 100% cases as in our case. The transoral approach described by Ehrlich¹⁰ in 1950 is indicated for small, nonvascular tumors, as it offers poor exposition and does not give adequate control in the event of hemorrhage. The several kinds of mandibular osteotomies have been described to give excellent exposure. We prefer to use standard transcervical approach for large benign PPS tumors.

Histopathological assessment of osteochondroma shows presence of chondrocytes of cartilaginous cap arranged in clusters parallel to lacunars spaces similar to that of normal epiphyseal cartilage; regular bony trabeculae produced by endochondral ossification are seen. Exostosis is covered by periosteum that is continuous with that of adjacent bone.⁴

It has very slow and benign course, although histopathological examination showing reactive changes can be confused with sarcomatous transformation.³ Osteochondroma can be sessile or pedunculated. Pedunculated variety is more likely to be malignant and the chances are more if cartilaginous cap exceeds length from more than 2 cm.¹¹ It has not been concluded whether

osteochondroma is a neoplasia or an osseous repair.³ The malignant potential and risk of recurrence are rare.⁴

CONCLUSION

Osteochondroma arising in the parapharyngeal space is of very rare occurrence. High index of suspicion and an adequate clearance of the tumor with a cuff of surrounding dispensable normal tissues is the key to successful treatment of such tumors.

REFERENCES

1. Khafif A, Segev Y, Kaplan DM, Gil Z, Fliss DM. Surgical management of parapharyngeal space tumors: a 10-year review. *Otolaryngol Head Neck Surg* 2005;132:401-406.
2. Kerscher A, Piette E, Tideman H, Wu PC. Osteochondroma of the coronoid process of the mandible. *Oral Surg Oral Med Oral Pathol* 1993;75:559-564.
3. Tanaka E, Lida S, Tsuji H, Kogo M, Morita M. Solitary osteochondroma of the mandibular symphysis. *Int J Oral Maxillofac Surg* 2004;33:625-626.
4. Ortakoglu K, Akcam T, Sencimen M, Karakoc O, Ozyigit HA, Bengi O. Osteochondroma of the mandible causing severe facial asymmetry: a case report. *Oral Surg Oral Med Oral Pathol* 2007;103:21-28.
5. Stanley RE. Parapharyngeal space tumors. *Ann Acad Med Singapore* 1991;20:589-596.
6. Som PM, Sacher M, Stollman AL, Biller HF, Lawson W. Common tumors of the parapharyngeal space: refined imaging diagnosis. *Radiology* 1988;169:81-85.
7. Rodriguez-Giurana J, Rodado C, Saez M, Bassas C. Giant parotid pleomorphic adenoma involving the parapharyngeal space: report of a case. *J Oral Maxillofac Surg* 2000;58:1184-1187.
8. Malone JP, Agarwal A, Schuller DE. Safety and efficacy of transcervical resection of parapharyngeal space neoplasms. *Ann Otol Rhinol Laryngol* 2001;110:1093-1098.
9. Hamza A, Fagan JJ, Weissman JL, Myers EN. Neurilemmomas of then parapharyngeal space. *Arch Otolaryngol Head Neck Surg* 1997;123:622-626.
10. Tsushima Y, Matsumoto M, Endo K. Parotid and parapharyngeal tumors; tissue characterization with dynamic magnetic resonance imaging. *Br J Radiol* 1994;67:342-345.
11. Batsakis JG, Sneige N. Pathology consultation; parapharyngeal and retropharyngeal diseases. *Ann Otol Rhinol laryngol* 1989;98:320-324.

ABOUT THE AUTHORS

Ashok Kumar Gupta (Corresponding Author)

Professor, Department of ENT, Postgraduate Institute of Medical Education and Research, Chandigarh, India, e-mail: akg@hotmail.com

Darwin Kaushal

Senior Resident, Department of ENT, Postgraduate Institute of Medical Education and Research, Chandigarh, India

Karan Gupta

Senior Resident, Department of ENT, Postgraduate Institute of Medical Education and Research, Chandigarh, India

Kim Vaiphei

Professor, Department of Pathology, Postgraduate Institute of Medical Education and Research, Chandigarh, India