

The Surgical Landmark for Facial Foramen

Jumroon Tungkeeratchai, Thongchai Bhongmakapat, Porncharn Saitongdee, Pisamai Orathai

ABSTRACT

Objective: To study the localization and relative of the supratrochlear, supraorbital, infraorbital and mental foramen in Thai cadavers to external landmarks for helps the surgeon to easily and practically identify these foramen.

Materials and methods: The localization of the supratrochlear, supraorbital, infraorbital and mental foramen in adult Thai cadavers were studied in 110 cadavers (220 sides) from 2008 until 2012. The analyses were also performed to compare differences between sexes and sides.

Results: Mean length of supraorbital foramen from nasal midline on the right side was 2.76 cm, left side 2.75 cm, above supraorbital rim right side 0.23 cm, left side 0.23 cm. Mean length of supratrochlear foramen from nasal midline on the right side was 1.77 cm, left side 1.76 cm. Mean length of infraorbital foramen from maxillary midline on the right side was 3.06 cm, left side 3.07 cm, from infraorbital rim on the right side was 0.94 cm, left side 0.92 cm. Mean length of mental foramen measurement straight to symphysis menti on the right side was 3.19 cm, left side 3.18 cm. Measurement along curvature of the mandible on the right side was 3.49 cm, left side 3.49 cm.

Conclusion: The knowledge gained from this study is quite important, since it helps the surgeon to easily and practically identify supraorbital notch/foramen, supratrochlear foramen, infraorbital foramen and mental foramen. This will help avoid injury of the neurovascular bundles passing through these sets of foramen.

Keywords: Supraorbital foramen, Supratrochlear foramen, Infraorbital foramen, Mental foramen.

How to cite this article: Tungkeeratchai J, Bhongmakapat T, Saitongdee P, Orathai P. The Surgical Landmark for Facial Foramen. *Int J Otorhinolaryngol Clin* 2013;5(3):121-124.

Source of support: Nil

Conflict of interest: None declared

INTRODUCTION

The supraorbital notch/foramen, supratrochlear foramen, infraorbital foramen and mental foramen are important anatomical landmarks to facilitate surgery of several diseases including trauma, tumor, inflammation, infection and esthetic procedure. For many surgeons including facial plastic, general plastic, oculoplastic, maxillofacial and neurosurgeon, it is essential to avoid injury of the neurovascular bundles passing through these kinds of foramen.

Agthong¹ studied and reported on the anatomical variations of the important apertures in the orbit. The present results suggest that race, side and gender should be of concern during the orbital surgery.

Tulika Gupta² reported that supraorbital, infraorbital and mental foramen most often lies on a vertical line with second premolar in 80% of skulls. Computer tomographic (CT) scan offers a more accurate detection of the mental foramen than conventional radiographs.

Taiseer Al-Khateeb³ found that the position of mental foramen on panoramic radiographs in Jordanians is most commonly located between the mandibular premolar tooth, and this result was similar to previous findings in caucasian population.

MATERIALS AND METHODS

The subjects for this research consisted of 110 Thai cadavers: 61 male and 49 female adults at the Department of Anatomy, Faculty of Science, Mahidol University, Bangkok, Thailand. The anatomical structures of facial foraminae were studied on 220 sides of 110 cadavers during 2008 to 2011. Measurements were made at the center of supraorbital notch/foramen from nasal midline and above orbital rim, supratrochlear foramen from nasal midline, infraorbital foramen from the maxillary midline and below infraorbital rim. The distance between mental foramen to

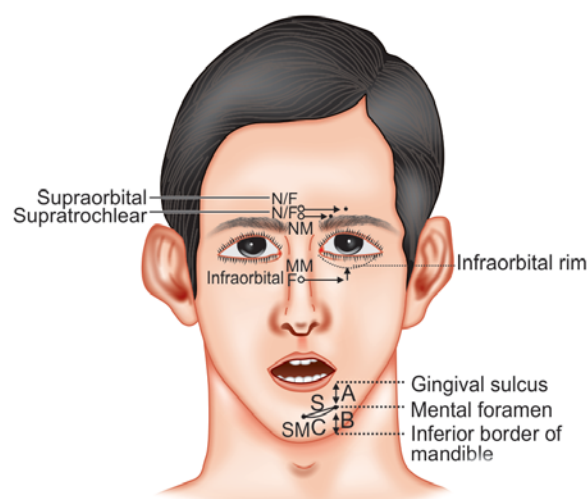


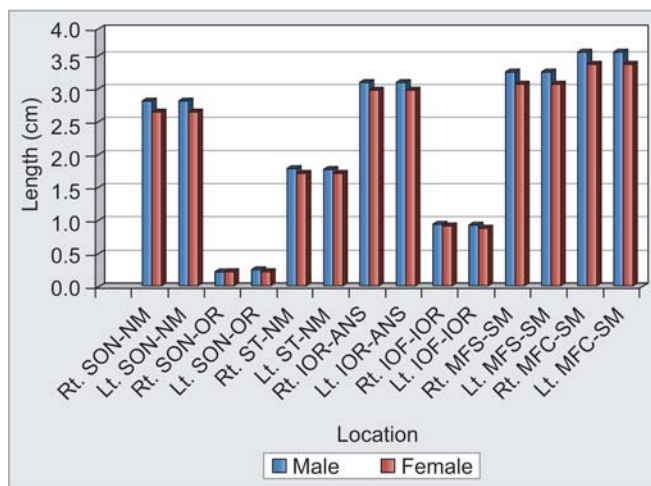
Fig. 1: Measurements were made—SON-NM: Supraorbital notch or foramen to nasal midline; SON-OR: Supraorbital notch or foramen to orbital rim; ST-NM: Supratrochlear foramen to nasal midline; IOR-MM: Infraorbital rim to maxillary midline; IOF-IOF: Infraorbital foramen to infraorbital rim; A: From gingival sulcus to mental foramen; B: From mental foramen to inferior border of mandible; C: From symphysis menti to the mental foramen (in curved line related to mandibular curvature as measured with a flexible ruler); D: The ratio of A/A+B; S: Straight measurements from symphysis menti to the mental foramen (in straight line and not related to mandibular curvature as measured with a sliding caliper)

symphysis menti was measured straight and along the curvature of mandibular bone. Measurements in vertical plane were also made: (i) from gingival sulcus to mental foramen = A, (ii) from mental foramen to inferior border of mandible = B, and (iii) the ratio of A/A+B = D (Fig. 1).

The position of the mental foramen was recorded with the long axis of a tooth. Complete data of measurements were separated into gender and sides. The statistical package for social science (version 11) was used for the analyses. The mean, standard deviation, minimum and maximum for each of the measurements were assessed as well as comparison between genders and sides using the paired and unpaired t-test.

RESULTS

The results of 61 male and 49 female cadavers were revealed (Graph 1). The most common of supraorbital had two branches. Right supraorbital had two branches 52.73% and had three branches 44.55%. Left supraorbital had two branches 54.55% and three branches 40.91%. The most common of supratrochlear had two branches, right supratrochlear had two branches 81.82% and left supratrochlear had two branches 80.00% (Table 1).



Graph 1: Differences of mean length in each location between male and female

Table 2 shows the mean length of supraorbital foramen from nasal midline on the right side 2.76 cm and left side 2.75 cm, and there is a significant difference between gender, above from supraorbital rim right side 0.23 cm and left side 0.23 cm.

The mean length of supratrochlear foramen from nasal midline right side was 1.77 cm and left side 1.76 cm; the distance between supraorbital foramen and supratrochlear

Table 1: Number of nerve branches: supratrochlear and supraorbital

Number of branches	Supratrochlear				Supraorbital			
	Right		Left		Right		Left	
	n	%	n	%	n	%	n	%
One branch	10	9.09	10	9.09	3	2.73	5	4.55
Two branches	90	81.82	88	80.00	58	52.73	60	54.55
Three branches	10	9.09	12	10.91	49	44.55	45	40.91
Total	110	100.00	110	100.00	110	100.00	110	100.00

Table 2: Anthropometric measurements related to the supraorbital notch/foramen, supratrochlear foramen, infraorbital foramen and mental foramen

Locations (cm)	Total (n = 110)				Males (n = 61)				Females (n = 49)				t-test p-value
	Mean	SD	Min	Max	Mean	SD	Min	Max	Mean	SD	Min	Max	
Rt. SON-NM	2.76	0.31	2.05	3.88	2.83	0.33	2.05	3.75	2.67	0.28	2.22	3.88	0.010**
Lt. SON-NM	2.75	0.27	2.22	3.75	2.83	0.29	2.25	3.75	2.65	0.20	2.22	3.05	0.000***
Rt. SON-OR	0.24	0.07	0.10	0.42	0.24	0.08	0.1	0.42	0.24	0.05	0.15	0.33	0.623
Lt. SON-OR	0.27	0.06	0.15	0.52	0.27	0.06	0.15	0.42	0.26	0.06	0.15	0.52	0.597
Rt. ST-NM	1.77	0.23	1.35	2.51	1.80	0.24	1.51	2.51	1.73	0.21	1.35	2.15	0.094
Lt. ST-NM	1.76	0.22	1.35	2.51	1.79	0.22	1.51	2.51	1.72	0.20	1.35	2.25	0.096
Rt. IOR-ANS	3.06	0.24	2.25	3.62	3.11	0.22	2.66	3.62	3.00	0.25	2.25	3.5	0.011*
Lt. IOR-ANS	3.07	0.25	2.2	3.8	3.13	0.24	2.65	3.8	3.00	0.25	2.2	3.5	0.006**
Rt. IOF-IOF	0.94	0.17	0.28	1.55	0.95	0.17	0.45	1.25	0.93	0.18	0.28	1.55	0.534
Lt. IOF-IOF	0.92	0.21	0	1.55	0.94	0.22	0	1.55	0.90	0.21	0	1.55	0.334
Rt. MFS-SM	3.19	0.30	2.4	3.85	3.27	0.29	2.52	3.85	3.09	0.28	2.4	3.52	0.001**
Lt. MFS-SM	3.18	0.29	2.45	3.8	3.26	0.27	2.5	3.8	3.09	0.28	2.45	3.5	0.002**
Rt. MFC-SM	3.49	0.31	2.73	4.4	3.57	0.29	2.84	4.4	3.39	0.30	2.73	3.84	0.002**
Lt. MFC-SM	3.49	0.30	2.75	4.4	3.57	0.28	2.82	4.4	3.40	0.30	2.75	3.85	0.003**

SON/F: Supraorbital notch or foramen; NM: Nasal midline; ST: Supratrochlear foramen; NM: Nasal midline; IOF: Infraorbital foramen; MM: Maxillary midline; IOR: Infraorbital rim; MFS: Mental foramen measurement straight; MFC: Mental foramen measurement along curvature of the mandible; SM: Symphysis menti; *: Significant difference between genders at p < 0.05; **: p < 0.01; ***: p < 0.001



Table 3: Mean and standard deviation of A, B and D of male and female cadavers on the right side and left side

Position	Gender	n	Mean (cm)	SD	K-S test	p-value
Right A	Male	61	1.33	0.32	1.299	>0.05
	Female	49	1.19	0.37	1.483*	<0.05
Left A	Male	61	1.33	0.32	1.299	>0.05
	Female	49	1.19	0.37	1.483*	<0.05
Right B	Male	61	1.33	0.24	1.145	>0.05
	Female	49	1.37	0.34	1.588*	<0.05
Left B	Male	61	1.33	0.24	1.145	>0.05
	Female	49	1.37	0.34	1.588*	<0.05
Right D	Male	61	0.50	0.07	2.427*	<0.05
	Female	49	0.46	0.09	1.712*	<0.05
Left D	Male	61	0.50	0.07	2.427*	<0.05
	Female	49	0.46	0.09	1.712*	<0.05

Note: *: Non-normality; A: Length from gingival sulcus to mental foramen; B: Length from mental foramen to inferior border of mandible; D: A/A+B; K-S test: Kolmogorov-Smirnov test

Table 4: Location of teeth and mental foramen

Gender	Right location of tooth				Left location of tooth			
	In the line with the first premolar	Between the first and second premolar	In the line with the second premolar	Total	In the line with the first premolar	Between the first and second premolar	In the line with the second premolar	Total
Males n (%)	12 (19.67)	24 (39.34)	25 (40.98)	61 (55.45)	11 (18.03)	24 (39.34)	26 (42.62)	61 (55.45)
Females n (%)	9 (18.37)	17 (34.69)	23 (46.94)	49 (44.55)	9 (18.37)	17 (34.69)	23 (46.94)	49 (44.55)
Total n (%)	21 (19.09)	41 (37.27)	48 (43.64)	110 (100.00)	20 (18.18)	41 (37.27)	49 (44.55)	110 (100.00)

foramen was on average on the right side 1 cm and left side 1 cm.

The mean length of infraorbital foramen from maxillary midline on the right side was 3.06 cm and left side 3.07 cm. There is a significant difference between gender. The mean length of infraorbital foramen from infraorbital rim on the right side was 0.94 cm and left side 0.92 cm.

The mean length of mental foramen measurement straight to symphysis menti on the right side was 3.19 cm and left side 3.18 cm, while measurement along curvature of the mandible on the right side was 3.49 cm and left side 3.49 cm.

On the right side, the average length from gingival sulcus to mental foramen (A) of male and female was 1.33 and 1.19 cm (SD = 0.32 and 0.37), the average length from mental foramen to inferior border of mandible (B) of male and female was 1.33 cm and 1.37 cm (SD = 0.24 and 0.34), and the proportion of A/A+B (D) of male and female was 0.50 and 0.46 (SD = 0.07 and 0.09). On the left side, the average length from gingival sulcus to mental foramen (A) of male and female was 1.33 cm and 1.19 cm (SD = 0.32 and 0.37), the average length from mental foramen to inferior border of mandible (B) of male and female was 1.33 cm and 1.37 cm (SD = 0.24 and 0.34), and the proportion of A/A+B (D) of male and female was 0.50 and 0.46 (SD = 0.07 and 0.09) (Table 3).

Mental foramen was on the same vertical plane as in the line of second premolar 43.64% on the right side, 44.55% on the left side and between the first and second premolar 37.27% on the right side and 37.27% on the left side (Table 4).

DISCUSSION

The supraorbital notch/foramen, supratrochlear foramen, infraorbital foramen and mental foramen are very important anatomical landmarks for the surgeon before surgery. In this study cadavers have the same skin subcutaneous and periosteum as alive people. There was no shrink effect from formalin, because some cadavers are fresh cadavers. Distance of supraorbital N/F, supratrochlear foramen from midline did not show any difference from previous studies in Thai⁴ but was different from those studied in white, black and Hispanic subjects.⁵ Distance between supraorbital notch/foramen and supratrochlear foramen was 1 cm. Before surgery the surgeon can palpate notch/foramen and measurement from midline and mark 1.7 cm to supratrochlear foramen and 2.7 cm to supraorbital notch/foramen and supraorbital foramen above orbital rim .23 cm. Distance from infraorbital foramen to maxillary midline mean was 3 cm, below infraorbital rim 0.9 cm.

Mental foramen is very important because when measurement straight from symphysis menti to mental

foramen it was shorter than measurement along curvature of mandibular bone and longer than when compared with prior study that measurement was made from skull, because the skull does not have subcutaneous skin and periostium.

The mean distance from the mental foramen to the symphysis menti in this study was different from that in previous studies in Thai,⁶ Chinese⁷ and British.⁸

The position of the mental foramen related to the tooth ia variable among races,^{2,9,10} but the most common position of mental foramen in this studies (44.55%) was in line with the long axis of the second lower premolar, which was in agreement with previous studies in Thais, Asians and Westerners.^{4,11-14}

CONCLUSION

The knowledge gained from this study is quite important, since it helps the surgeon to easily identify supraorbital N/F 2.7 cm from midline and 0.23 above supraorbital rim, supratrochlear foramen 1.7 cm from midline, infraorbital foramen from maxillary midline 3.06 cm, and there is a significant difference between sexes and gender. The mean of length of infraorbital foramen from infraorbital rim on the right side was 0.94 cm and left side 0.92 cm. The mean length of mental foramen measurement straight to symphysis menti on the right side was 3.19 cm and left side 3.18 cm; measurement along curvature of the mandible on the right side was 3.49 cm and left side 3.49 cm. This was half way between gingival sulcus and inferior border of mandible in vertical plane and closely related with the second premolar.

ACKNOWLEDGMENTS

The authors wish to thank Dr Worranan Prasantikom and Professor Amnuay Thithapangha, Faculty of Medicine, Ramathibodi Hospital, Mahidol University, for help with the analysis and advice during the preparation of this manuscript.

REFERENCES

1. Agthong S, Huanmanop T, Chentanez V. Anatomical variations of the supraorbital, infraorbital, and mental foramina related to gender and side. *J Oral Maxillofac Surg* 2009;63(6):800-804.
2. Gupta T. Localization of important facial foramina encountered in maxillofacial surgery. *Clinical Anatomy* 2008;21(7):633-640.
3. Al-Khateeb T, Al-Hadi Hamasha A, Ababneh KT. Position of the mental foramen in a Northern regional Jordanian population. *Surgical and Radiologic Anatomy* 2007;29(3):231-237.

4. Apinhasmit W, Chompoopong S, Methathrathip D, et al. Supraorbital notchs/foramen, infraorbital foramen and mental foramen in thais: anthropometric measurements and surgical relevance. *J Med Assoc Thai* 2006;89(5):675-678.
5. Aziz SR, Marchena JM, Puran A. Anatomic characteristics of the infraorbital foramen: a cadaver study. *J Oral Maxillofac Surg* 2000;58:992-996.
6. Boonpiruk N. Location of mental foramen in Thai skulls. *J Dent Assoc Thai* 1975;25:295-302.
7. Santini A, Land M. A comparison of the position of the mental foramen in Chinese and British mandibles. *Acta Anat (Basel)* 1990;137:208-212.
8. Cutright B, Quillopa N, Schubert W. An anthropometric analysis of the key foramina for maxillofacial surgery. *J Oral Maxillofac Surg* 2003;61:354-357.
9. Wang TM, Shih C, Liu JC, Kuo KJ. A clinical and anatomical study of the location of the mental foramen in adult Chinese mandibles. *Acta Anat (Basel)* 1986;126:29-33.
10. Kim IS, Kim SG, Kim YK, et al. Position of the mental foramen in a Korean population: A clinical and radiographic study. *Implant Dent* 2006;15:404-411.
11. Green RM. The position of the mental foramen: a comparison between the Southern (Hong Kong) Chinese and other ethnic and racial groups. *Oral Surg Oral Med Oral Pathol* 1987;63:287-290.
12. Montagu MF. The direction and position of the mental foramen in the great apes and man. *Am Phys Anthropol* 1954;12:503-518.
13. Piyawinijwong S, Rojananin J, Pornkuntham U, Pilakasiri K. The mental foramen in Thais. *R Thai Air Force Med Gaz* 1985;31:141-146.
14. Ngeow WC, Yuzawati Y. The location of the mental foramen in a selected Malay population. *J Oral Sci* 2003;45:171-175.

ABOUT THE AUTHORS

Jumroon Tungkeeratichai (Corresponding Author)

Assistant Professor, Department of Otolaryngology, Faculty of Medicine Ramathibodi Hospital, Mahidol University, Bangkok 10400, Thailand
Phone: 022011515, Fax: 023547293, e-mail: jumroont@yahoo.com

Thongchai Bhongmakapat

Assistant Professor, Department of Otolaryngology, Faculty of Medicine, Ramathibodi Hospital, Mahidol University, Bangkok Thailand

Porncharn Saitongdee

Associate Professor, Department of Anatomy, Faculty of Science Ramathibodi Hospital, Mahidol University, Bangkok, Thailand

Pisamai Orathai

Assistant Professor, Department of Nursing, Faculty of Medicine Ramathibodi Hospital, Mahidol University, Bangkok, Thailand