

Benign Paroxysmal Positional Vertigo and Positional Vertigo Variants

Giacinto Asprella Libonati

ABSTRACT

This article reviews the causes of positional vertigo and positional nystagmus of peripheral origin. Benign paroxysmal positional vertigo is described in all its variants, its diagnosis and therapy are highlighted. In addition, nonparoxysmal positional vertigo and nystagmus due to light/heavy cupula of lateral and posterior semicircular canal is focused on. The differential diagnosis between positional vertigo due to otolithic and nonotolithic causes is discussed.

Keywords: Benign paroxysmal positional vertigo, Light/heavy cupula, Liberatory manoeuver, Semicircular canal, Canalolithiasis, Cupulolithiasis.

How to cite this article: Asprella Libonati G. Benign Paroxysmal Positional Vertigo and Positional Vertigo Variants. *Int J Otorhinolaryngol Clin* 2012;4(1):25-40.

Source of support: Nil

Conflict of interest: None declared

INTRODUCTION

Benign paroxysmal positional vertigo (BPPV) is the most common cause of peripheral vertigo and is due to a mechanical labyrinthine disorder.

It is characterized by brief and violent crises of spinning sensation with brisk onset and rapid decrease—paroxysmal vertigo. Each crisis usually lasts from 15 to 60 seconds and is related to head position changes with respect to gravity—positional vertigo. It usually has a favorable course and therefore is defined as ‘Benign’, however, there are very disabling variants of BPPV because of their high recurrence rate and their low response to physical therapy, such that some authors prefer to omit the term benign.

BPPV can occur at any age, even in infants, but its peak of incidence occurs between 50 and 60 years of age. BPPV is uncommon in children and in our experience only 1% of BPPV seen in 1 year concerns the pediatric age group, i.e. patients aged 3 to 14 years.¹ BPPV usually occurs spontaneously, but can be associated with triggering events causing otoconial detachment. Such a causal relationship can be hypothesized with high probability in case of minor head trauma occurring within the last 24 to 72 hours (domestic injuries, sports injuries, school injuries, dental care), while only a possible or probable relationship can be assumed with viral or vascular illness.¹

BPPV pathophysiology is due to a mechanical labyrinthine disorder caused by the presence of free floating

otoconial debris inside the semicircular canals—canalolithiasis, or attached to the ampullary cupula—cupulolithiasis. Both of the previous conditions transform the ampullary cupula of the involved canal from a detector of angular accelerations into a detector of linear accelerations, thus becoming gravity sensitive.

According to the canalolithiasis theory the otoconial conglomerate gravitates inside the canal because of head movements and in so doing pushes the endolymphatic column. In this way, the otoconial bolus, acting as a piston, provokes a hydrodynamic drag on the endolymph, which deflects the ampullary cupula, thus generating an excitatory or an inhibitory stimulus which causes the paroxysmal vertigo.²

According to the cupulolithiasis theory the otoliths are attached to the cupula which becomes heavier than the surrounding endolymph and gravity sensitive (heavy cupula). In our experience, cupulolithiasis is rare compared to canalolithiasis.

BPPV Classification

The most useful BPPV classification for clinical practice is based on the involved canal.

- Posterior semicircular canal (PSC)
- Lateral semicircular canal (LSC)
- Anterior semicircular canal (ASC)
- Multicanalar BPPV
 - Simultaneous involvement: Posttraumatic BPPV
 - No simultaneous involvement: Canalar conversion

How to Diagnose BPPV?

The BPPV diagnosis should be related to the evoked nystagmus and not to the maneuver which elicits it. In fact, both excitatory and inhibitory stimuli of each semicircular canal are linked to a typical nystagmus, as every vestibular stimulus triggered by each ampullary cupula deflection provokes the contraction of a couple of extrinsic ocular muscles, thus generating typical eye movement responses of a characteristic nystagmus. Therefore, there are maneuvers suggested to diagnose every single type of BPPV, but the pathognomonic nystagmus for a subtype of BPPV is sometimes evoked performing the maneuver recommended to diagnose a different BPPV subtype. So it is the evoked nystagmus and not the kind of the performed maneuver, that allows us to diagnose the involved semicircular canal.¹

PSC BPPV

PSC BPPV is the most common form of BPPV, accounting for 75 to 80% of all BPPV cases.

The patient usually experiences his/her first PSC BPPV attack getting up in the morning. Vertigo is generally brief and violent and is associated with more or less intense neurovegetative symptoms. Each attack lasts from 15 to 30 seconds, but the patient reports longer discomfort due to nausea and vomiting. Vertigo recurs moving the head in the PSC plane and then the patient suffers a new attack every time he flexes or extends the head while upright, he lies down on the bed or even by turning toward the affected ear while supine.

Pathophysiology

Canalolithiasis: Free floating debris inside the PSC modify the cupula's sensitivity to accelerations. PSC cupula becomes sensitive to linear accelerations, i.e. gravity and to accelerations provoked by brisk head movements on the same plane of the involved PSC (inertial accelerations).

PSC BPPV Diagnosis

The diagnosis is performed by identifying the PSC BPPV canalolithiasis nystagmus. It is evoked by an ampullofugal, thus excitatory flow of the debris caused by positioning tests. Its typical features are shown in the Table 1.

We must pay attention to the eyes' position in the orbit: If the patient looks toward the affected ear, the PSC BPPV nystagmus torsional component is more evident; if the

patient looks toward the unaffected ear, the PSC BPPV nystagmus vertical component is more evident.

It is easier to perform the correct diagnosis examining the patient in the active period, after a short time from the positional vertigo onset, when the typical BPPV nystagmus is more easily and clearly evoked by the diagnostic maneuvers.

Diagnostic Maneuvers for PSC BPPV

Specific movements were found to more efficiently elicit the PSC BPPV nystagmus and they were defined as diagnostic maneuvers or diagnostic tests. The most popular diagnostic maneuvers are:

- The Dix-Hallpike maneuver (Fig. 1)
- The Semont maneuver (first step, Figs 2A and B).

PSC BPPV Therapy

Epley's Maneuver or Canalith-Repositioning-Procedure (CRP)³⁻⁷

The Epley's maneuver or canalith-repositioning-procedure (CRP) is the most used technique for PSC BPPV therapy (Fig. 3).

We find it more natural to directly continue with the CRP when a positive diagnostic Dix-Hallpike maneuver has been observed, with no turning back to the sitting position. In so doing, we evoke less vertigo episodes with less neurovegetative symptoms and better treatment tolerance according to 'the strategy of the minimum stimulus'.¹⁻⁷

Table 1: PSC BPPV canalolithiasis nystagmus features

Nystagmus' quick phase	<ul style="list-style-type: none"> • Torsional component: Geotropic <ul style="list-style-type: none"> – Counterclockwise for right PSC – Clockwise for left PSC • Vertical component: Up beating
Nystagmus is dissociated	<ul style="list-style-type: none"> • Torsional component <ul style="list-style-type: none"> – More evident in the ipsilateral eye • Vertical component <ul style="list-style-type: none"> – More evident in the contralateral eye
Nystagmus is paroxysmal	<ul style="list-style-type: none"> • Rapid increase to a plateau and a more gradual decrease • Short duration: 15/60 seconds.
Nystagmus latency	<ul style="list-style-type: none"> • 3-15 seconds period of latency after the evocative maneuver and prior to the onset of nystagmus
Nystagmus fatigue	<ul style="list-style-type: none"> • The repetition of the positioning test reduces nystagmus intensity
Nystagmus direction	<ul style="list-style-type: none"> • Nystagmus reverses its direction when the patient sits-up after being in the head-hanging position. <ul style="list-style-type: none"> – Usually this nystagmus has a lower intensity than the nystagmus evoked by Dix-Hallpike maneuver, because it is caused by an inhibitory stimulus, which evokes a response smaller than the one consequent to an excitatory stimulus, according to Ewald's second law. • Sometimes its direction spontaneously reverses while staying in the head-hanging position <ul style="list-style-type: none"> – This last condition is more frequent, if the nystagmus intensity is very strong

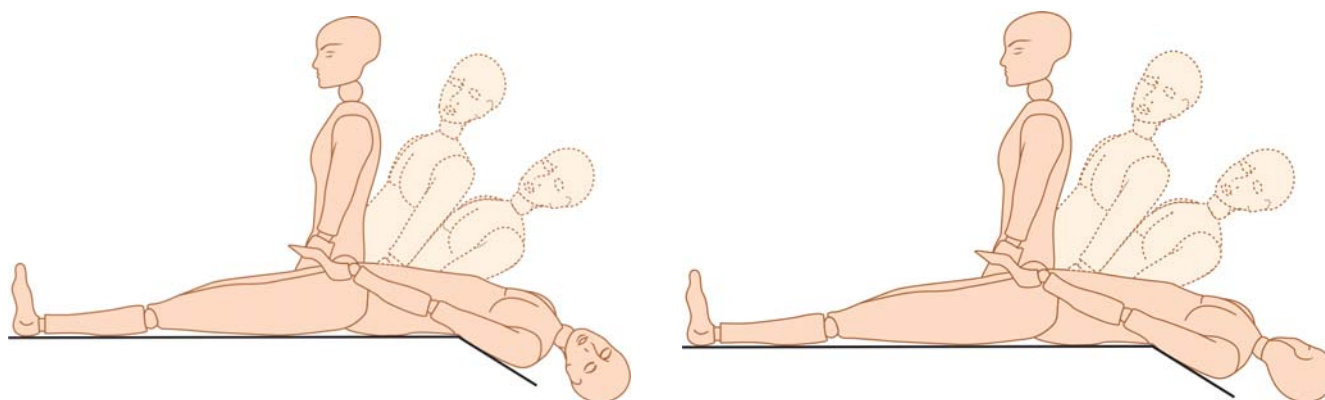
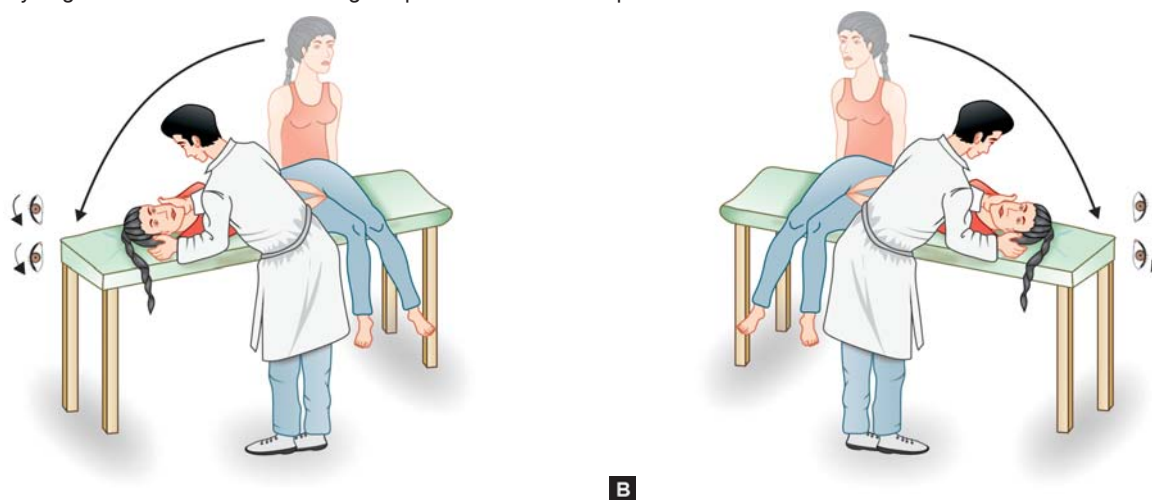


Fig. 1: The Dix-Hallpike maneuver for left side (left) and right side (right). Technique: The patient sits on the examination bed, then the examiner keeping the patient's head between his/her hands, rotates it 45° toward the examined ear. The patient is then rapidly and gently brought down to the head hanging position, getting supine with the head still rotated 45° toward the tested ear and hyperextended approximately 20° off of the head-rest. After a variable delay, between 3 to 15 seconds, due to nystagmus latency, the typical paroxysmal PSC BPPV nystagmus appears, caused by otoconial debris floating away from the ampulla. The consequential ampullofugal deflection of the ampulla generates an excitatory discharge of the ipsilateral posterior vestibular nerve and the resulting paroxysmal nystagmus. A reversal nystagmus is observed returning the patient to the seated position



Figs 2A and B: The diagnostic Semont maneuver: (A) right side, (B) left side. Technique: The patient sits on the edge of the examination bed with his/her legs dangling, the examiner is in front of the patient and quickly brings him/her down onto the checked ear, keeping his/her head rotated 45° toward the opposite side

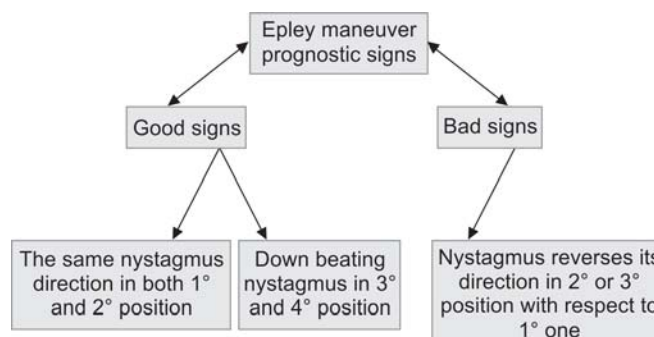
A nystagmus-based approach was suggested in monitoring whether or not ampullofugal progression of the debris in the canal occurs by observing the nystagmus evoked during each step of the liberatory technique.¹⁻⁷

The reversal of the nystagmus direction observed when the 2° or the 3° position is reached, is a sign that the debris are coming back along the canal (Flow Chart 1).

The down beating nystagmus observed while the patient lies face-down 135° and after he comes back upright, is a good prognostic sign, as it proves the maneuver is effective in freeing the canal from particles: Liberatory nystagmus (see Flow Chart 1).

The liberatory nystagmus can be explained with an endolymph flow from the ASC to the PSC that is due to the otoconial debris which overcome the point of convergence in the common crus of the two vertical canals.^{1,8}

The endolymph flowing from the ASC to the PSC would compensate the depression between the cupula of the PSC



Flow Chart 1: Nystagmus-based strategy performing the Epley maneuver

and the otoconial debris which are now moving through the common crus toward the utricle. All this would cause an ampullofugal endolymphatic excitatory flow in the ASC and an ampullopetal inhibitory one in the PSC, with a nystagmus whose rotatory components having opposite direction, canceling each other out, whereas its vertical

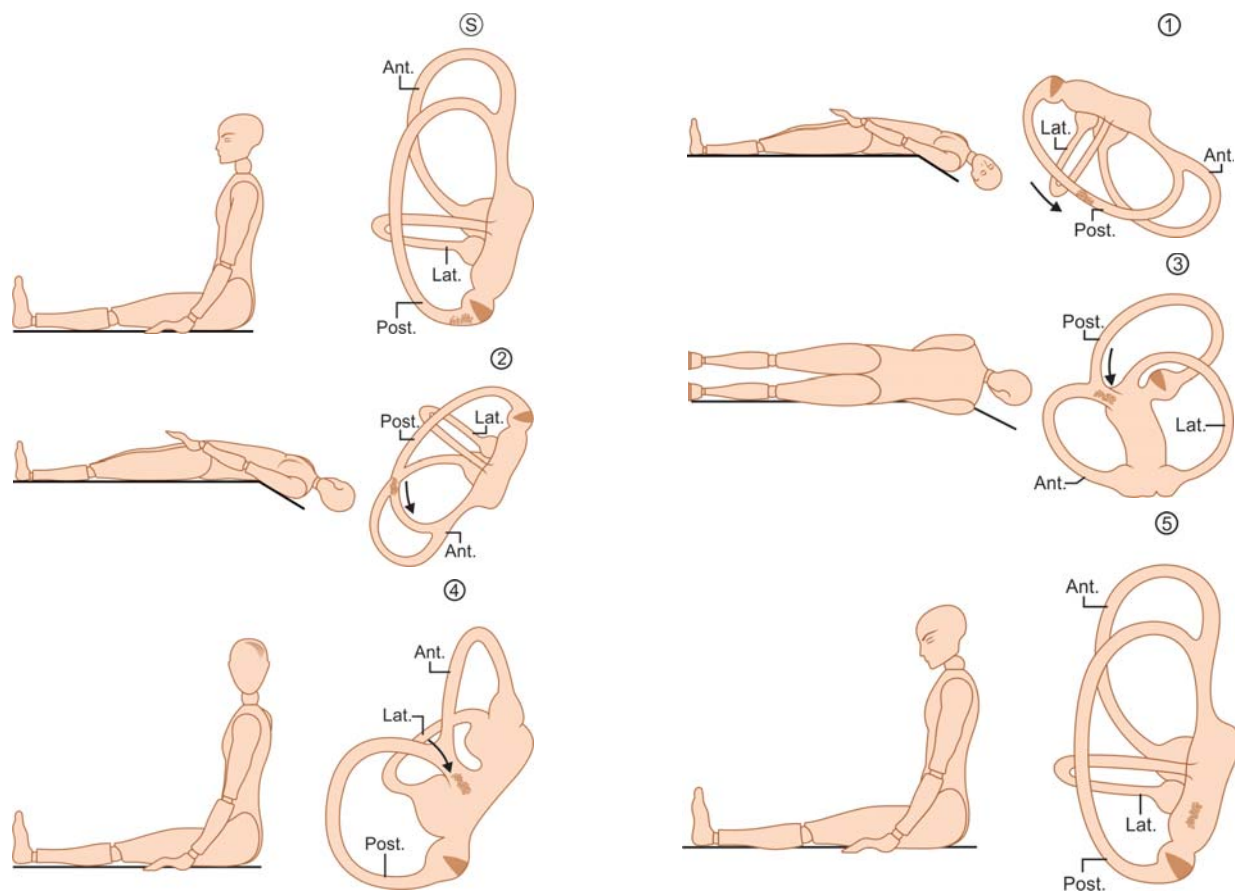


Fig. 3: The Epley's maneuver (CRP) for left PSC BPPV. Technique: The patient initially sits in the middle of the examination bed (S). Then the patient is brought back keeping his/her head turned 45° toward the target ear and finally lies down with the head extended 20° below the table, reaching the first position. Particles gravitate in the ampullofugal direction, thus generating an excitatory discharge of the ampullary nerve and the typical PSC BPPV nystagmus (1). Then, still keeping the head extended 20°, it is turned 45° to the contralateral side: second position, so that particles approach the apex and an excitatory nystagmus like the previous one appears once again (2). On the contrary, if the nystagmus reverses its beating direction, this is a sign that the debris are coming back along the canal (see Flow Chart 1). After that, the patient rolls on to his/her shoulder getting face-down 135°: third position. Particles now enter the common crus and a purely vertical down beating nystagmus is usually observed (3). The patient finally comes back upright, head still turned: fourth position. Particles gravitate through the common crus now and the down beating nystagmus is still beating (4). Finally, the head is straightened and tilted forward 20°: fifth position (5). Particles drop into the utricle. Now, we are ready to start another cycle, if necessary

components add up to each other since, they have the same down-beating direction.⁸

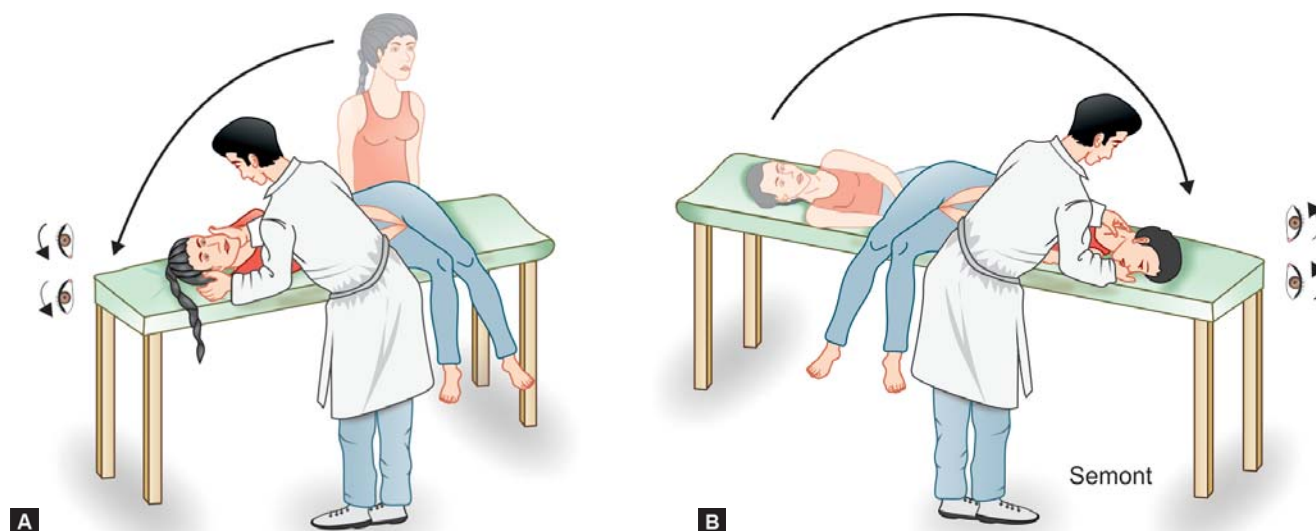
Semont Maneuver

The Semont maneuver (Figs 4A and B) needs a faster movement compared with the CRP, therefore it requires greater patient agility and cooperation. It is more frequently used in Europe. We reserve it to treat unresponsive cases still unsuccessfully treated by CRP. A mastoid vibrator is used to treat cases still unsuccessfully cured several times with both techniques.

The 1st step: The patient sits on the edge of the examination bed with his/her legs dangling, while the examiner is in front of the patient and quickly brings him/her down onto the affected ear keeping his/her head rotated 45° toward the opposite side. If the nystagmus appears (it should be torsional/up beating with the fast-phase beating toward the

down ear), keep the patient there until the nystagmus disappears.

The 2nd step: Now the patient is quickly brought to the opposite side holding his/her head and neck with both hands. In so doing, the patient reaches a face-down position on the opposite side. A torsional/up beating nystagmus will appear with the fast-phase still beating toward the affected ear (the uppermost one). If the nystagmus beats toward the down ear this could suggest the otoliths are moving back toward the PSC ampulla (Flow Chart 2). If no nystagmus appears after the patient is tilted to the opposite ear, it could be useful to slowly turn the head 90° facing up and then turn it again 135° toward the opposite direction so that it comes back 45° facing down. The nystagmus should then occur. Hold the patient in the nystagmus-inducing position for a few minutes and then slowly bring the patient back to a sitting position. We usually observe a pure down beating nonparoxysmal nystagmus after the patient comes back

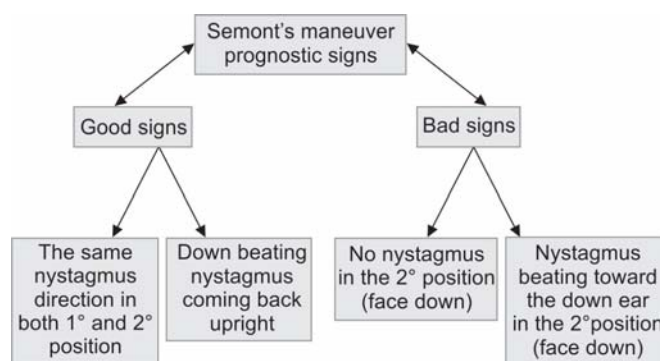


Figs 4A and B: The Semont maneuver for right PSC BPPV. 1st step (1): The patient sits on the edge of the examination bed with his/her legs dangling, while the examiner is in front of the patient and quickly brings him/her down onto the affected ear keeping his/her head rotated 45° toward the opposite side. If the nystagmus appears (it should be torsional/up beating with the fast-phase beating toward the down ear), keep the patient there until the nystagmus disappears. The 2nd step (2): now, the patient is quickly brought to the opposite side holding his/her head and neck with both hands. In so doing, the patient reaches a face-down position on the opposite side

upright, which means the particles are moving out the PSC gravitating through the common crus (Figs 4A and B; Flow Chart 2).

PSC Heavy Cupula

This condition can be caused either by otoliths attached to the cupula, cupulolithiasis or by a transitory modified density ratio between the cupula and the surrounding endolymph (Asprella's case report personal communication Modena-Italy 2010). The Dix-Hallpike test evokes a nystagmus with the same canalolithiasis features concerning the quick phase direction and characteristic pattern of dissociated eye movements, but the PSC heavy cupula nystagmus is stationary and persistent with short or no latency and is less fatigable. The persistent nystagmus evoked by Dix-Hallpike stops and reverses with the head rotated from 45 to 55° toward the opposite side keeping the head extended 20° over the bed: Neutral position (Fig. 5). If the patient is observed a few hours after the symptoms onset, a persistent nystagmus with the same morphological features, but less intense, is evoked by changing the head bending angle while sitting: A torsional upbeating nystagmus with head extended, which reverses its beating direction when the head is flexed (Fig. 6).⁹ The heavy cupula mechanism can be caused either by otoliths attached to the cupula, cupulolithiasis or by a transitory modified density ratio between the cupula and the surrounding endolymph.⁹ The differential diagnosis between them should be based,



Flow Chart 2: Nystagmus-based strategy performing the Semont maneuver

first of all, on the effectiveness of the liberatory maneuvers in solving the vertigo and the positional nystagmus. In addition, a history with BPPV recurrence and the time elapsed from symptom onset until otoneurological examination, which is usually longer when an otolithic mechanism is supposed, ranging generally from 2 to 6 weeks in our experience, may contribute to the cupulolithiasis diagnosis. Positional nystagmus has been reported in previous case series of patients with vestibular migraine (VM).¹⁰ The authors reported attacks of positional vertigo mimicking BPPV, but atypical for a real BPPV because of the persistent characteristics of both positional vertigo and nystagmus. The VM pathophysiology has been associated with central vestibular disorders related to functional interactions between the vestibular system and mechanisms involved in migraine, but this is still a matter of speculation.

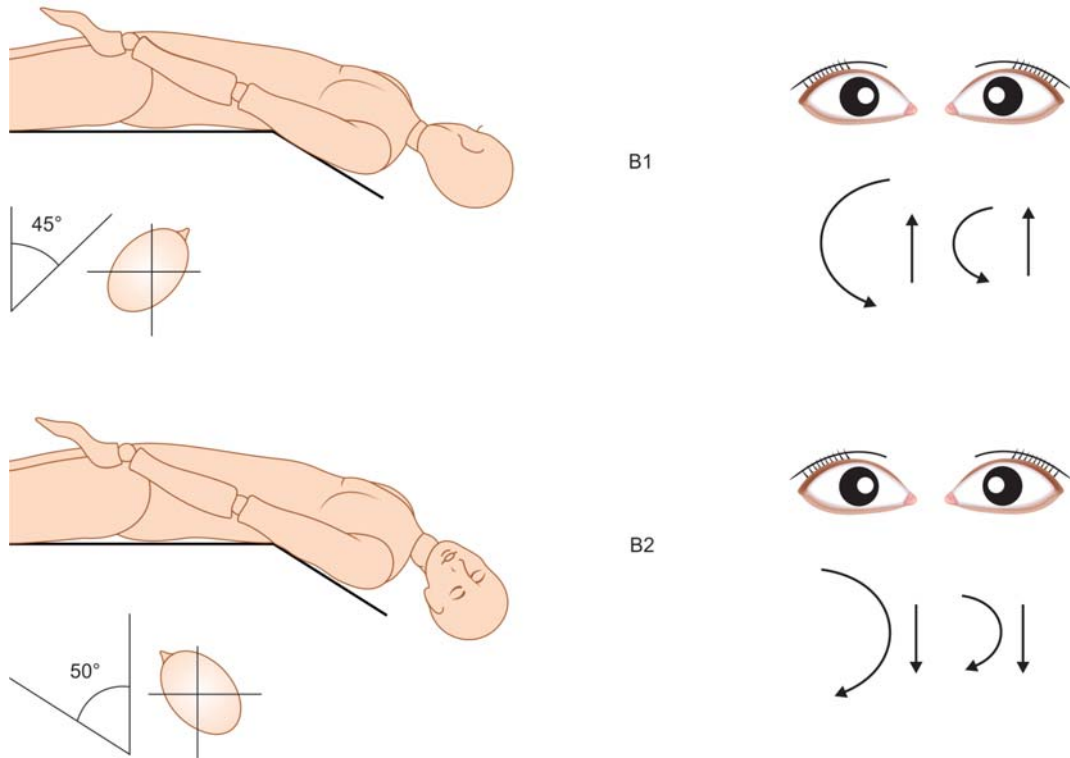


Fig. 5: Right PSC heavy cupula. Right Dix-Hallpike: Up beating and counterclockwise nystagmus (B1), which stops with the head rotated from 45° to 55° toward the left side, keeping the head extended 20° over the bed: Neutral and reversal position. The nystagmus reverses its beating direction due to further left head rotation becoming down beating, clockwise (B2). This latter nystagmus was less intense than the previous counterclockwise one. The nystagmus was always persistent in all the evocative positions and was observed longer than 10 minutes keeping the same characters (stationary nystagmus)

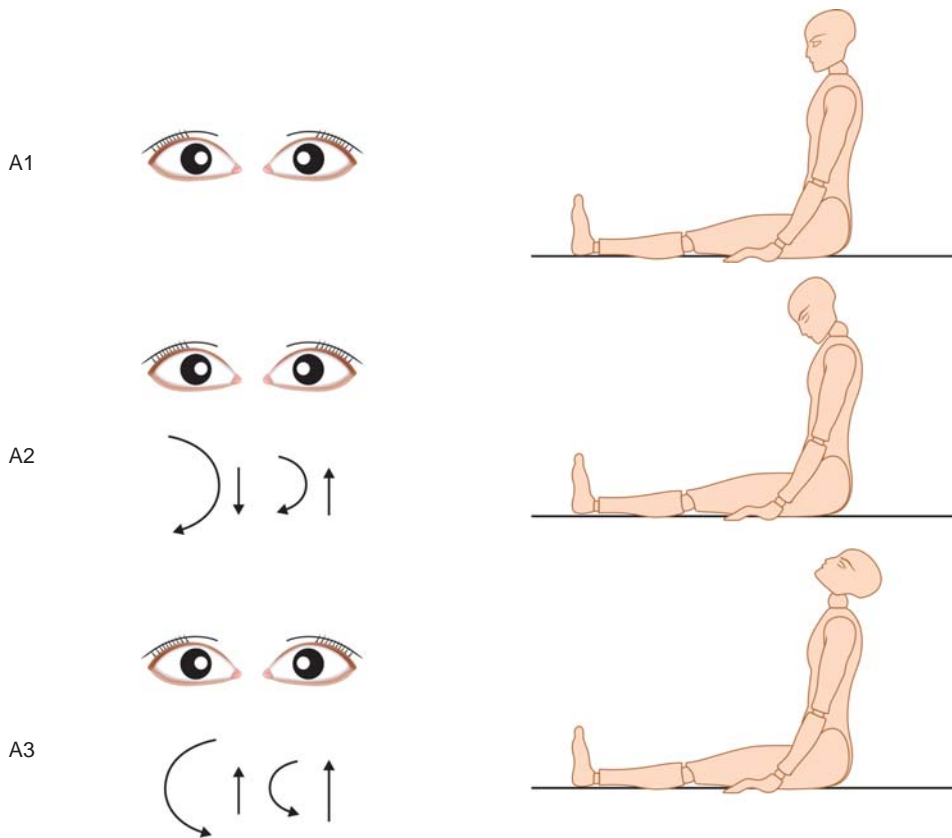


Fig. 6: Right PSC heavy cupula. Upright position: A-1 erect head: No nystagmus; A-2 flexed head: Down beating, clockwise nystagmus; A-3 extended head: Upbeating, counterclockwise nystagmus. The torsional component, either clockwise or counterclockwise, is more evident in the right eye, the vertical one, either upbeating or downbeating, in the left eye

We observed persistent positional nystagmus in the course of acute vertigo in several cases of migrainous patients. The nystagmus features were suggestive of a pathophysiological mechanism more often related to gravity sensitive cupula of the lateral semicircular canal, either with a light cupula showing a geotropic nystagmus or with a heavy cupula with an apogeotropic nystagmus. Nevertheless, we reported about a series of migrainous patients suffering from acute attacks of vertigo with persistent positional nystagmus referable to a gravity sensitive cupula of the posterior semicircular canal.⁹

We hypothesized that the mechanisms involved in migraine, e.g. a localized fluid diffusion from the labyrinth microcirculation due to migraine, could be held responsible for an acute perturbation in the labyrinthine function, which could generate a cupula dynamics disorder either in the LSC or in PSC.

The nystagmus features with their temporal and morphological characteristics allow us to presume a peripheral origin of these disorders, and to diagnose the involved cupula either as lighter or heavier. An acute perturbation of the labyrinthine function due to VM should be considered in the differential diagnosis of acute vertigo, taking into account an acute peripheral disorder related to a heavy/light cupula mechanism.

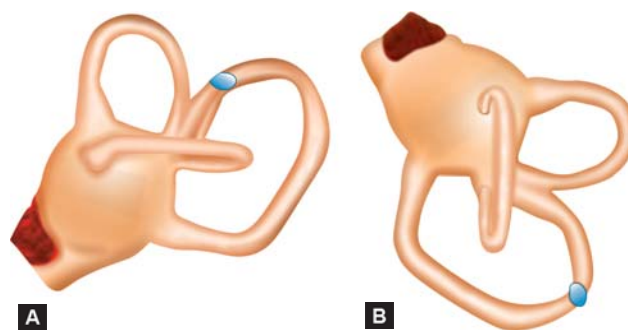
The positional features of the evoked nystagmus are essential to make a correct diagnosis and realize which cupula is involved in each patient.

It is possible to differentiate the otolithic-caused heavy cupula from the nonotolithic one. In fact, the liberatory maneuvers can detach the otoconia from the cupula much more if their mechanical effect is enhanced by using a mastoid vibrator. However, the liberatory maneuvers are always ineffective when heavy cupula is due to a non-otolithic cause.⁹

Apogeotropic Variant of PSC BPPV

Vannucchi and colleagues reported patients showing a nystagmus typically suggestive of an ASC BPPV in 2009.¹¹ After the liberatory maneuver for ASC BPPV was performed, a typical nystagmus of contralateral PSC BPPV appeared. Thus, the authors supposed that a canalolithiasis of PSC caused by otoconial debris, free floating along the non-ampullary PSC arm close to the common crus, can mimic the contralateral ASC BPPV.

In fact, the debris inside the PSC close to the common crus, gravitate toward the PSC ampullary arm because of the Dix-Hallpike maneuver, thus generating an ampullopetal endolymphatic current and the consequential cupular deflection toward the utricle (Figs 7A and B). The resulting



Figs 7A and B: Apogeotropic variant of PSC BPPV, the debris inside the right PSC close to the common crus, gravitate toward the PSC ampullary arm (modified from Vannucchi et al with the author permission)

nystagmus has the same features as the one generated by excitatory stimulation of the contralateral ASC.

A positional downbeating nystagmus evoked by the Dix-Hallpike maneuver, with poor or no torsional components and without clinical evidence of CNS dysfunction is generally ascribed to an ASC BPPV, but such a nystagmus observed in patients with a history suggesting BPPV may be the sign of a PSC VPPB variant, caused by an otoconial mass originally located close to the common crus.

PSC BPPV and Lindsay-Hemenway Syndrome

PSC BPPV may be the delayed result of acute labyrinthine damage which caused a crisis of severe vertigo that gradually resolved itself within a few weeks. PSC BPPV sometimes follows an acute episode of vertigo within a variable, usually short delay, this sequence of symptoms is named 'Lindsay-Hemenway syndrome'.¹² It is usually described as a delayed effect of the anterior vestibular artery ischemia which causes a selective labyrinthine damage localized in the ASC, LSC and in the utricular macula. Such partial vestibular damage is ascribed likewise to a neuritis of the superior vestibular nerve. It is sometimes possible to detect the simultaneous occurrence of PSC BPPV and acute vertigo due to sudden vestibular damage.¹ This association of concurrent symptoms is usually missed, because the influence of the positioning tests, such as Dix-Hallpike, is not routinely tested in patients suffering from acute vertigo with spontaneous nystagmus or at least it is not examined at the right moment. If this were regularly done, the typical PSC BPPV nystagmus would be found as a possible concurrence with the spontaneous horizontal nystagmus due to acute unilateral vestibular loss.

LSC BPPV

The second most common type of BPPV is LSC BPPV, accounting for 15 to 25% of all BPPV cases.¹³⁻¹⁵

The patient usually experiences his/her first LSC BPPV attack turning sideways while sleeping. The violent vertigo abruptly wakes the patient up and is generally associated with very intense neurovegetative symptoms. Each attack lasts from 30 to 60 seconds, sometimes longer. Vertigo recurs moving the head in the LSC plane. It is more intense when the head is rotated from side to side while supine, but the patient can suffer from mid vertigo every time the otoliths inside the affected lateral canal begin to gravitate because of head movements, e.g. by rotating the head to the upright position, by lying straight down or on one side. Crisis associated neurovegetative symptoms and dizziness while walking are usually more intense in the course of LSC BPPV, rather than in PSC BPPV.

Pathophysiology

Canalolithiasis: Free floating debris inside the lateral semicircular canal modify the cupula's sensitivity to accelerations. Therefore, the LSC cupula becomes sensitive to linear accelerations, i.e. gravity and accelerations provoked by brisk head movements on the same plane of the involved LSC. Two LSC canalolithiasis variants are known:^{14,15}

1. Geotropic LSC BPPV, about 75% of all LSC BPPV and is due to debris floating along the LSC nonampullary arm, which is the posterior one.
 2. Apogeotropic LSC BPPV, about 25% of all LSC BPPV and is due to debris floating close to the LSC ampulla.
- *Pathophysiology of the geotropic variant*: Shortly after rotating the patient's head to the impaired side while supine, the otoliths gravitate toward the ampulla along the LCS posterior arm, generating an ampullopetal excitatory endolymphatic current, and a geotropic nystagmus beating to the impaired ear. When the patient's head is turned to the healthy side, the otoliths float along the LSC posterior arm toward its utricular orifice, generating an ampullofugal inhibitory endolymphatic current. As a result, the nystagmus will be geotropic once again and therefore beat to the healthy side (Fig. 8).
 - *Pathophysiology of the apogeotropic variant*: When the patient lies on the impaired side the debris in the ampullary segment of the LSC will move away from the cupula, resulting in an inhibitory ampullofugal endolymphatic current, causing apogeotropic paroxysmal positional nystagmus to beat to the healthy ear.¹⁶ When the head is turned to the opposite side, the otoliths will drop toward the ampulla with an excitatory discharge and an apogeotropic paroxysmal positional nystagmus beating to the affected side will be observed (Fig. 9).

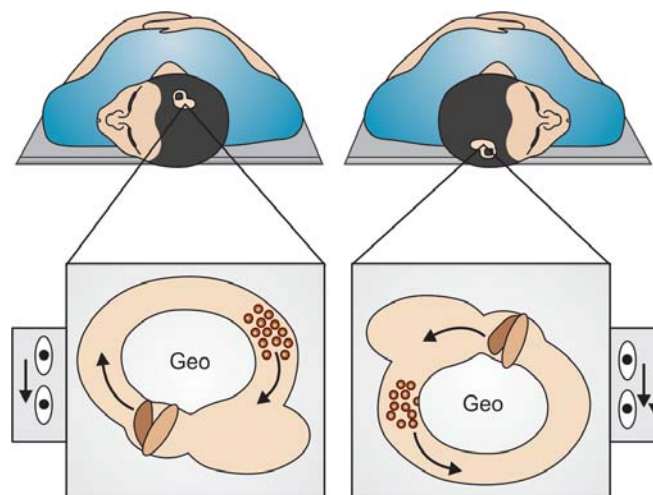


Fig. 8: Geotropic LSC BPPV pathophysiology, right side

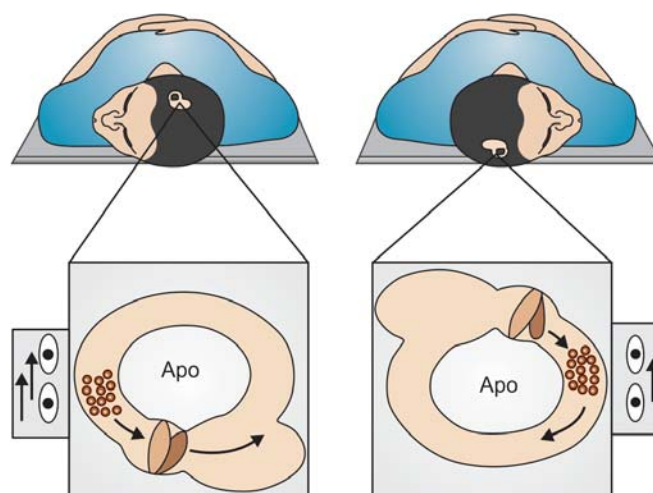


Fig. 9: Apogeotropic LSC BPPV pathophysiology, right side

LSC BPPV Diagnosis

The diagnosis is performed identifying the LSC BPPV canalolithiasis nystagmus whose typical features are reported in the Table 2.

The typical paroxysmal nystagmus is sometimes evoked only after repeating the diagnostic LSC BPPV maneuver again and again. This could happen in patients with a delayed diagnosis, because the otoliths are initially spread inside the LSC. In fact, the movement of otoliths is effective in deflecting the cupula only if they are conglomerated, thus acting like a piston. The repeated head rotations move debris by gathering them due to the forces of superficial adhesion.¹

Diagnostic Tests

The diagnostic maneuver for LSC BPPV is the 'supine head roll test' or 'McClure-Pagnini test'. This is performed by turning the head 180° to either side while supine. Since, it

Table 2: LSC BPPV canalolithiasis nystagmus features

Nystagmus quick phase	<ul style="list-style-type: none"> It is a direction changing, bidirectional, bipositional purely horizontal nystagmus <ul style="list-style-type: none"> Geotropic variant: Nystagmus beats toward the ground Apogeotropic variant: Nystagmus beats away from the ground
Nystagmus is paroxysmal	<ul style="list-style-type: none"> It very rapidly increases, reaches a so-called plateau and then slowly decreases It has a longer duration than the PSC BPPV one: 30/60 seconds, sometimes longer
Nystagmus latency	<ul style="list-style-type: none"> Its latency is shorter than the PSC BPPV one: 2/3 seconds, sometimes no latency
Nystagmus fatigue	<ul style="list-style-type: none"> Repetition of the positioning test induces less nystagmus fatigue than the PSC BPPV one. Actually, it is often impossible to proceed with retesting to determine how much the nystagmus is really fatigable because of violent associated neurovegetative symptoms
Nystagmus direction	<ul style="list-style-type: none"> Sometimes its direction spontaneously reverses while keeping the head in the evocative position <ul style="list-style-type: none"> This last condition is more frequent, if the nystagmus intensity is very strong It occurs more frequently turning the patient on the affected ear in the geotropic variant It is sometimes observed turning the patient on the unaffected ear in the apogeotropic variant

is performed on the yaw plane, it is more correct to call it the head yaw test (HYT) while supine.¹

LSC BPPV: The Affected Side Diagnosis

As therapeutic maneuvers should be performed toward the healthy side, diagnosing the affected side is critical for successful treatment.

The first described clinical sign in order to identify the impaired side in LSC BPPV, is the intensity of the nystagmus evoked by performing HYT while supine: Head yaw nystagmus.

The head yaw nystagmus beats with more intensity toward the impaired ear, according to Ewald's second law, which postulates that the response to an excitatory stimulus

is always more intense than the one following an inhibitory stimulus (Fig. 10), so that:

- In the geotropic variant the affected side is the one on which the nystagmus is more intense in HYT.
- In the apogeotropic variant the affected side is the one on which the nystagmus is less intense in HYT.

New clinical signs to diagnose the LSC BPPV affected side have been described in the last few years. All of them show nonparoxysmal long lasting nystagmuses, which generally are of low intensity (Table 3).

- A nystagmus evoked by bringing the patient down from a sitting position, was first described in 2005.¹⁷ This is evoked by the seated supine positioning test (SSPT). When the patient lies supine, having the head flexed 30°, the LSC is on a vertical plane; therefore, due to

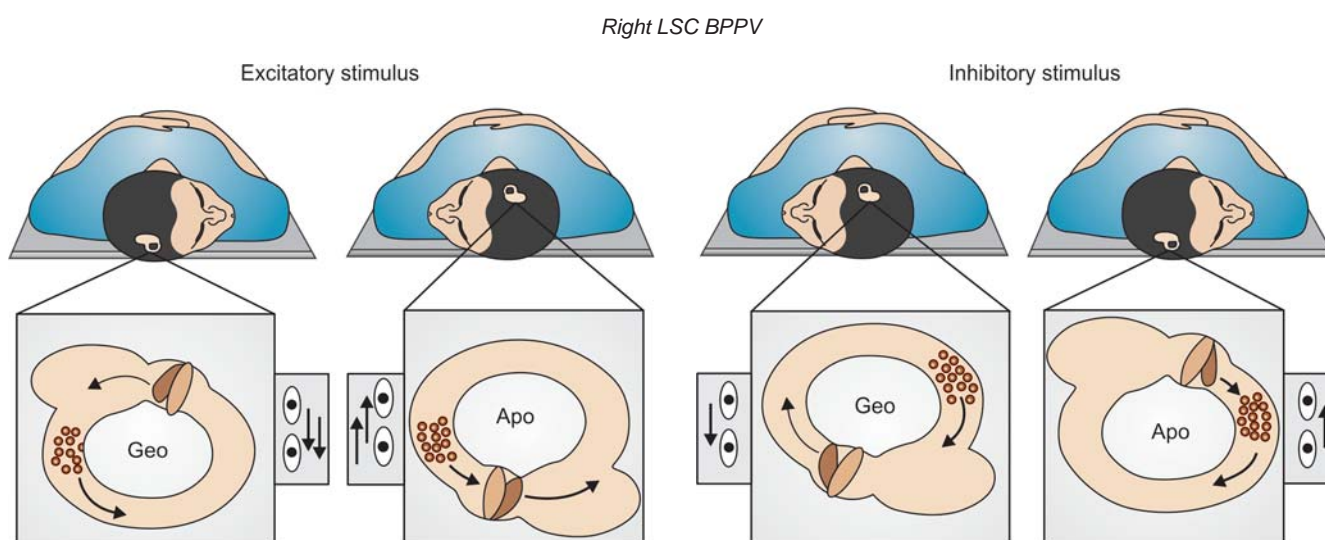


Fig. 10: HYT for LSC BPPV. The nystagmus evoked toward the impaired ear (right side in this figure) beats with more intensity since it is provoked by an excitatory stimulus

Table 3: LSC BPPV: Rules to diagnose the affected side

- The direction of the more intense nystagmus in the HYT while supine is toward the affected ear
- The direction of both the pseudospontaneous nystagmus and the seated supine positioning nystagmus is toward the unaffected ear in the geotropic LSC BPPV
- The direction of both the pseudospontaneous nystagmus and the seated supine positioning nystagmus is toward the affected ear in the apogeotropic LSC BPPV

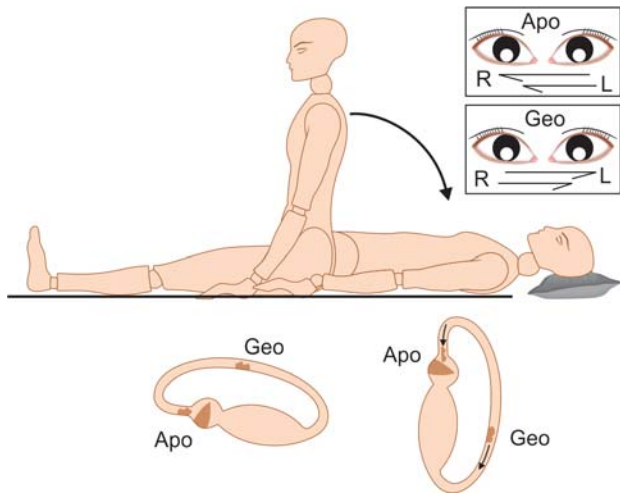
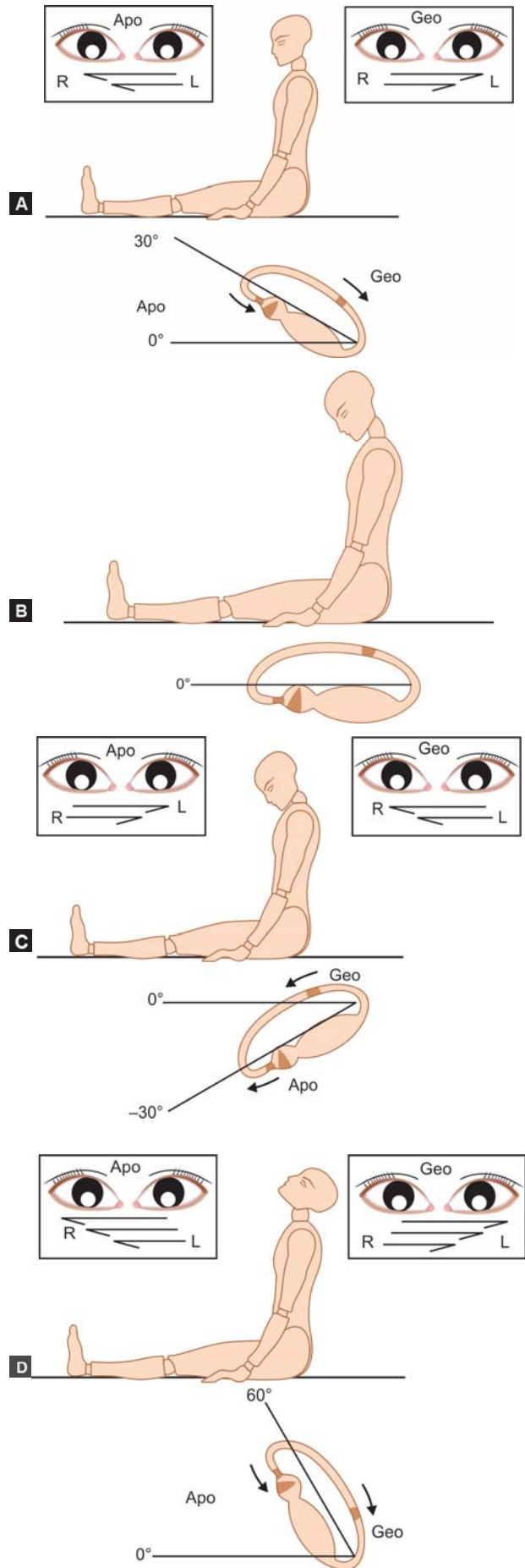


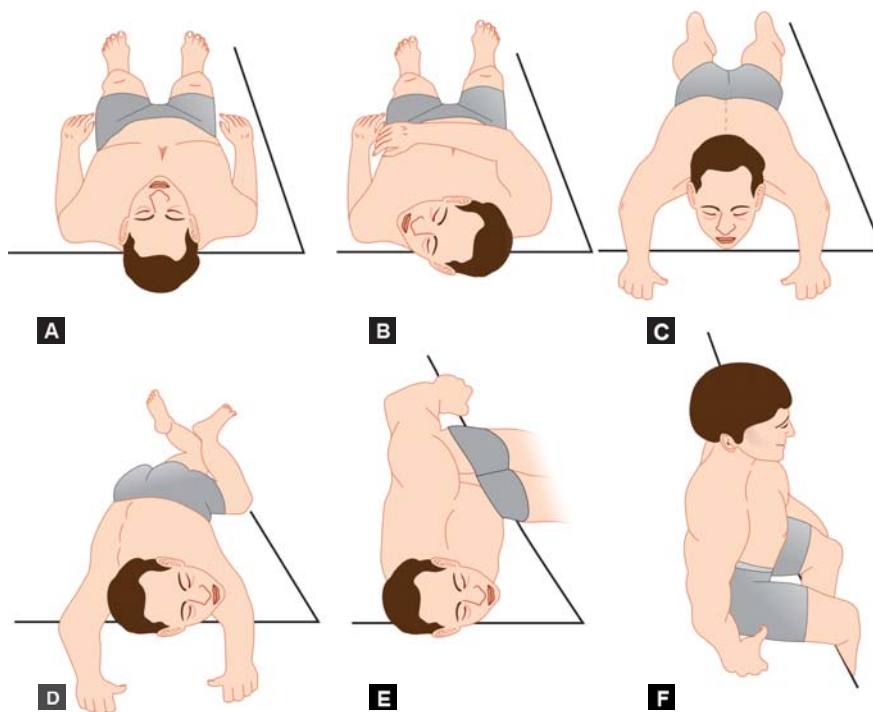
Fig. 11: LSC BPPV seated supine positioning nystagmus right side

gravity, the otoliths are pushed downward: When they are in the posterior arm, geotropic variant, they float away from the ampulla. When they are near the cupula, apogeotropic variant, they float toward the ampulla. Therefore, the SSPT evokes a nystagmus beating toward the healthy side in the geotropic variant and toward the affected side in the apogeotropic variant: Seated supine positioning nystagmus (SSPN; Fig. 11, Table 3).

- A nystagmus observed in an upright position has been described in patients suffering from LSC BPPV.^{18,19} It could be mistaken for a ‘spontaneous’ nystagmus, but it is a direction changing nystagmus because it is strongly modulated by head position, therefore it has been most properly defined as a ‘pseudospontaneous nystagmus’—PSN.²⁰⁻²² It beats toward the healthy side in geotropic LSC BPPV and toward the affected side in apogeotropic LSC BPPV. It increases if the head is bent 30° backward, disappearing when the head is bent 30° forward (neutral position), and reverses direction if the head is additionally inclined forward to 60° (Figs 12A to D, Table 3).²² It is sometimes useful to slowly rotate the patient’s head horizontally. In fact, such a maneuver evokes the PSN when it is not yet evident while the head is erect.
- A single theory was postulated to explain both the pseudospontaneous nystagmus observed in the upright position, with its modifications induced by slow flexing and extending the head (head pitch test), and the nystagmus induced by the seated supine positioning test.²¹⁻²³ Both should be considered as the biological response to a single physical phenomena: The otoliths gravitate along the inclined plane of the lateral semicircular canal. The only variable is the gravity vector size which is active in displacing the otoliths along the



Figs 12A to D: LSC BPPV pseudospontaneous nystagmus, right side



Figs 13A to F: Barbecue rotation technique according to Lempert for right LSC BPPV. Head is rotated 90° three times toward the healthy side, thus applying an overall 270° rotation

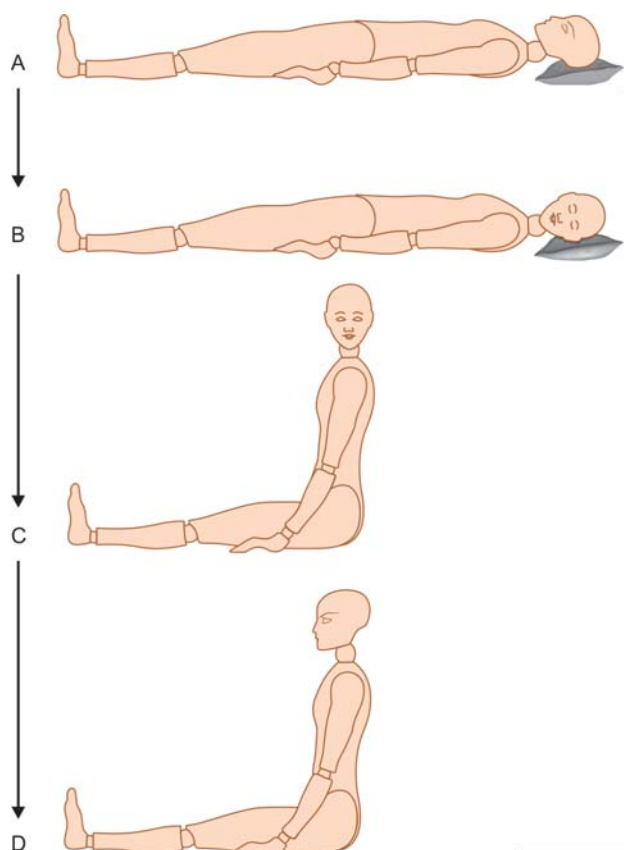
LSC. Thus, the acceleration due to gravity on the debris varies from zero (neutral point) when the LSC is orthogonal to the gravity axis (head flexed 30° forward in upright position), to the maximum when the LSC is parallel to the gravity vector (supine position, with the head straight and bent about 30° forward).²³

LSC BPPV Therapy

More therapeutic techniques have been proposed for LSC BPPV, all of them aim to achieve the ampullofugal endocanal progression of the otoconial debris either by (Table 4):

- Angular accelerations (barbecue rotation techniques)
- Gravitational sedimentation (Vannucchi forced prolonged position FPP)
- Linear accelerations (Gufoni liberatory maneuvers).

The barbecue rotation techniques work by negative inertia. They are done performing abrupt rotations of the patient’s head in steps of 90° toward the healthy side while



Figs 14A to D: Vannucchi-Asprella maneuver for right LSC BPPV supine, thus moving the debris in the direction opposite to the head rotation. According to Lempert, the head is rotated three times toward the healthy side, thus applying an overall 270° rotation (Figs 13A to F).²⁴

Table 4: LSC BPPV liberatory techniques

Angular acceleration Negative inertia	<ul style="list-style-type: none"> • Barbecue rotation <ul style="list-style-type: none"> – Lempert (270°) – Baloh (360°) – Vannucchi-Asprella (450° or more)
Linear acceleration Positive inertia	<ul style="list-style-type: none"> • Gufoni maneuver
Gravitational sedimentation	<ul style="list-style-type: none"> • Forced prolonged position (Vannucchi)

The Vannucchi-Asprella maneuver (Figs 14A to D): It is a variant of the barbecue maneuvers.²⁵ It can at once solve both geotropic and apogeotropic forms, as well as sometimes turning apogeotropic into geotropic forms. In addition, it is easier to perform than any other barbecue maneuver. In fact, it avoids movements from supine to prone and vice versa. As in the typical barbecue maneuver, the patient's head is quickly rotated 90° toward the healthy side, while supine, then keeping the head turned in this way, he/she sits-up and slowly brings the head back in line with the body. This sequence of movements is repeated five times or more, as long as it does not provoke nystagmus or vertigo. It is important to perform the maneuver under VNS monitoring in order to check, if the nystagmus is still beating toward the healthy side immediately after each step. Such a nystagmus denotes that the otolithic mass is moving toward the utricle. A nystagmus beating toward the affected ear means the debris are floating toward the ampulla so, the maneuver is being ineffective. The absence of nystagmus finally suggests that the canal has been rid of debris.^{21,26,27}

Vannucchi forced prolonged position (FPP): In the geotropic LSC BPPV, the patient is instructed to lie overnight, approximately 12 hours, on the healthy side, one or more times. In this position the affected ear is the uppermost, with debris in the downward-facing nonampullary arm (Fig. 15). Due to gravity, the debris gradually moves into the utricle. FPP can be used in the apogeotropic form, but the patient must lie on the affected side; in this way the debris moves from the anterior to the posterior side of the canal, changing from apogeotropic to geotropic form. The patient must then lie on the healthy side to become symptom-free.

Gufoni's maneuver: It works by positive inertia. The maneuver consists of the following steps: (1) The patient

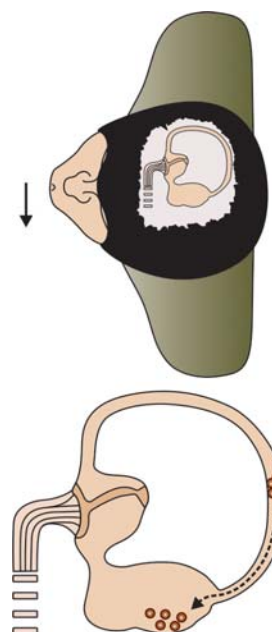


Fig. 15: Vannucchi FPP for right geotropic LSC BPPV (modified from Vannucchi et al with the author permission)

sits on the edge of the bed; (2) the patient suddenly lies down on one side which is the healthy one for geotropic LSC BPPV and the affected one in the apogeotropic form. (3) the head is rotated 45° downward and so kept for 2 to 3 minutes. In this position the outlet of the canal, in the geotropic form and the ampulla, in the apogeotropic one, are vertically oriented favoring the debris to gravitate down; (4) the patient finally returns to the sitting position (Fig. 16).

The transformation of the nystagmus from apogeotropic into geotropic is usually observed during the course of canalolithiasis therapy. A geotropic nystagmus can transform into an apogeotropic one, if the maneuver is performed toward the affected ear by mistake. Both these conversions are explained by the migration of the otoconial mass from the

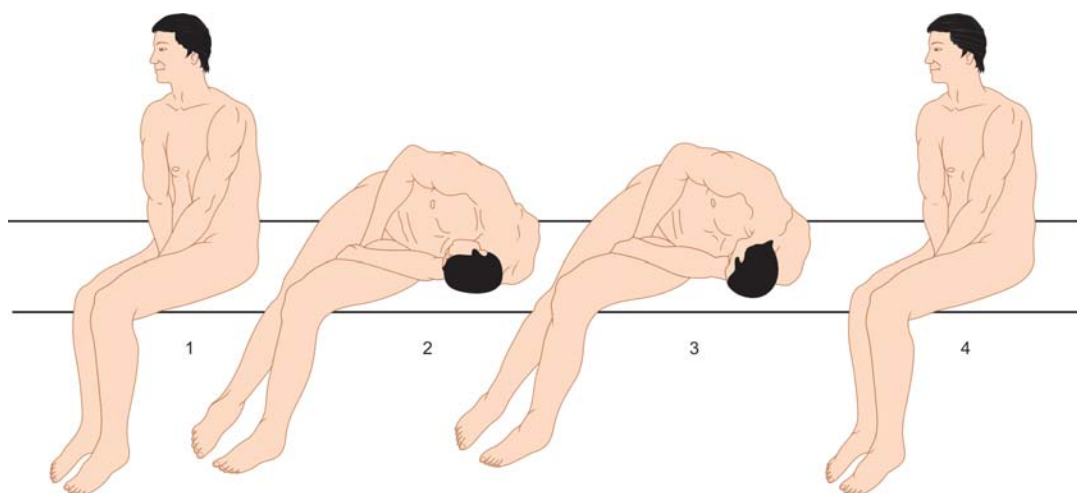


Fig. 16: Gufoni's maneuver for right geotropic LSC BPPV

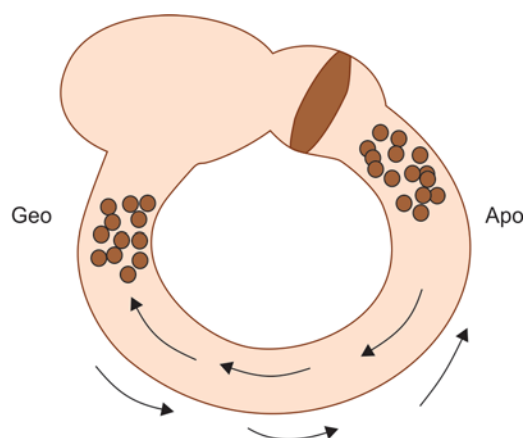


Fig. 17: Debris move from the right LSC posterior arm to the anterior one so, transforming a geotropic LSC BPPV into an apogeotropic one and vice versa

anterior LSC arm into the posterior one and in the opposite direction respectively (Fig. 17).

LSC Light/Heavy Cupula

Acute vertigo is sometimes associated with a steady intensity and persistent direction changing positional nystagmus (PDCPN) beating on the horizontal plane, which is observed either rotating the patient's head from side to side in the yaw plane while supine,²⁸ or changing its bending angle in the pitch plane in the upright position.²⁹⁻³¹ It has been suggested that this phenomenon could be caused by a modified density ratio between the LSC cupula and the surrounding endolymph.³² It was hypothesized that the cupula is lighter than the endolymph (light cupula) in patients showing a geotropic PDCPN, and the cupula is heavier (heavy cupula) when an apogeotropic nystagmus is evoked.

The LSC becomes gravity sensitive because of the difference of specific gravity with the surrounding endolymph, thus generating a direction changing nystagmus showing the following characteristics: Gradual in onset and persistent when the position is held, it is not fatigable and it does not show latency. In the upright position: The nystagmus disappears bending the head about 30° forward—neutral point in pitch plane, the nystagmus reverses its beating direction bending the head 60° forward and it beats again toward the previous direction with the head going back to an erect position, and finally increases by extending the head backward (Head pitch test) (Fig. 18). In the supine position: A persistent direction changing positional nystagmus is evoked on each side, geotropic or apogeotropic respectively. Two neutral points are identified rotating the head in the yaw plane while supine: The first neutral point

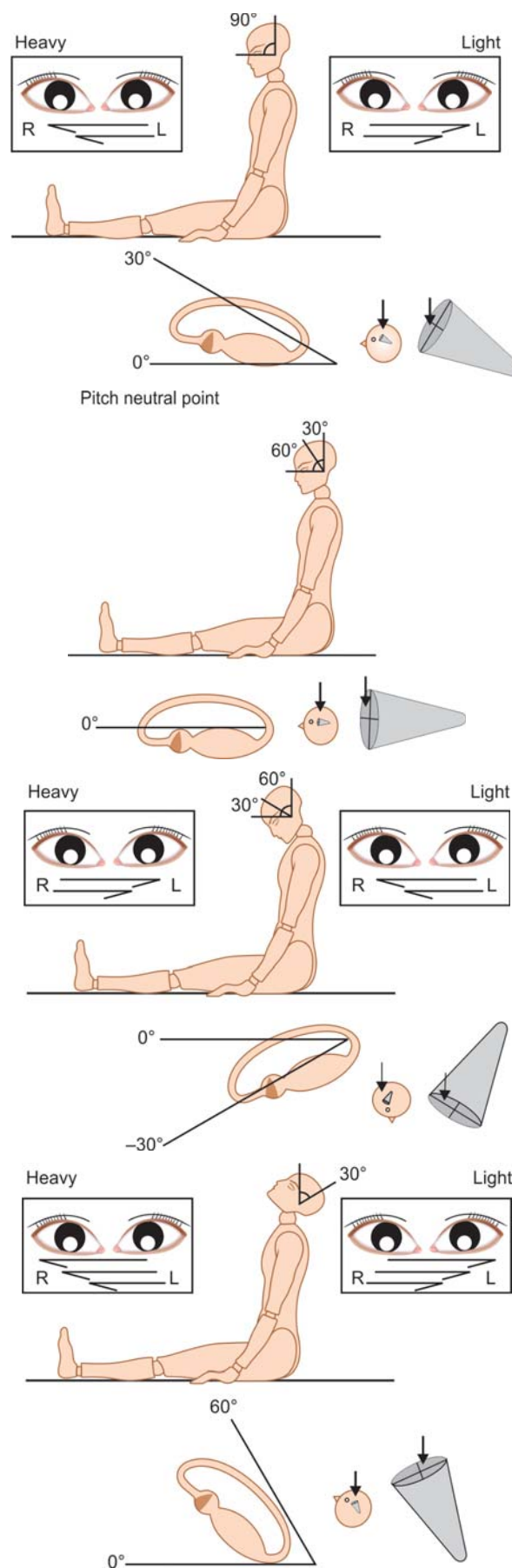


Fig. 18: Gravity sensitive cupula of right LSC: Nystagmus modifications obtained by changing the head bending angle in the pitch plane while sitting

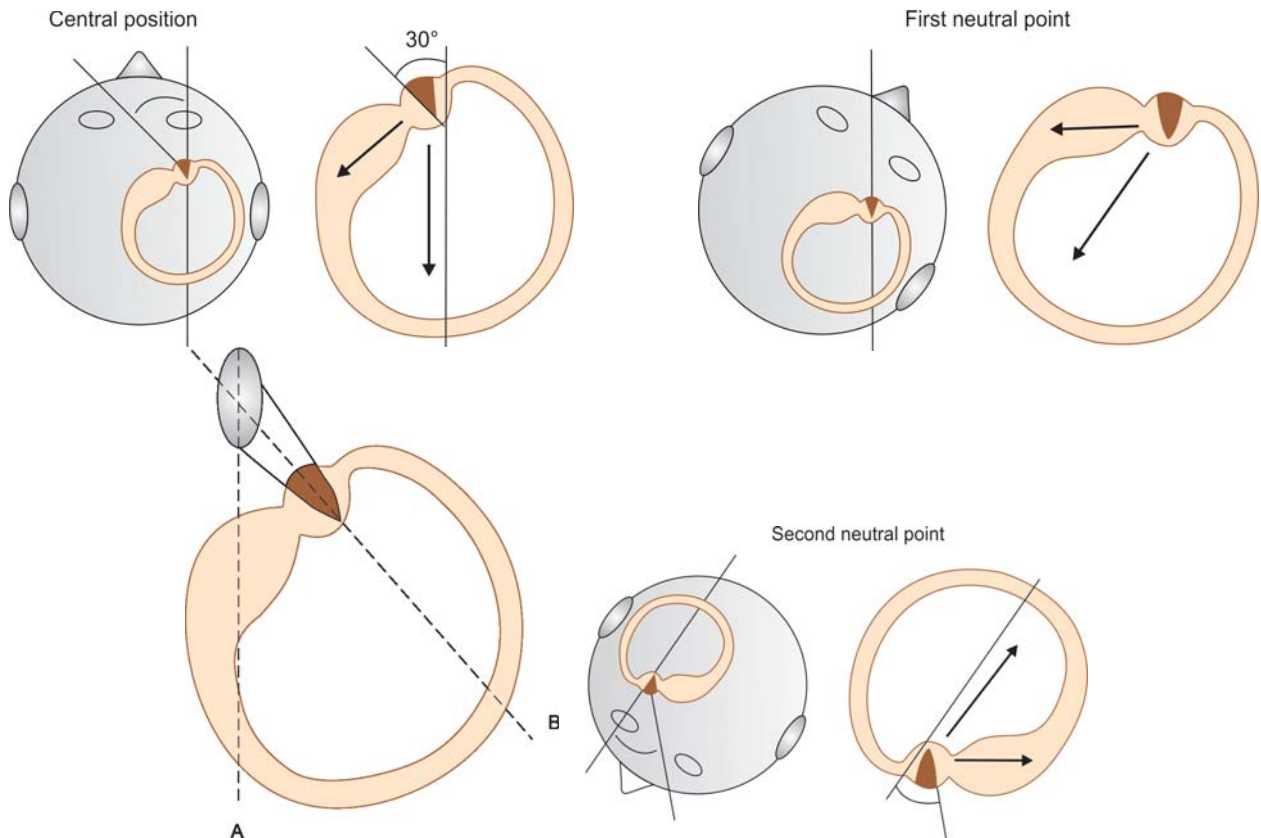


Fig. 19: Gravity sensitive cupula of right LSC: Nystagmus modifications obtained by changing the head bending angle in the yaw plane while supine. Cupula’s faces are roughly comparable to the plane identified by two straight lines: (A) the longer axis of the cupular basis and (B) the straight line running through the center of the cupular basis and its apex

with the head rotated about 30° toward the affected ear, and the second one in the 180° opposite position. The nystagmus reverses its beating direction once the head is rotated beyond each neutral point in the yaw plane (Fig. 19).³²

LSC heavy cupula can be ascribed to otoliths attached to the cupula, cupulolithiasis,²⁷ or to a transitory modified density ratio between the cupula and the surrounding endolymph.³² This latter condition was frequently observed

Table 5: PDCPN due to modified density ratio of cupula vs endolymph

Case history	Clinical features
<ul style="list-style-type: none"> • Acute onset of symptoms, with intense positional vertigo, which is often associated with severe autonomic symptoms • Patient reports a sudden onset of vertigo often at night, which is intensified by the lateral decubitus position • Migraine appears in patient’s history and/or in his/her family history • Should be excluded: <ul style="list-style-type: none"> – Any other neurological and/or audiological disorders (e.g. Ménière, vestibular neuritis) – Alcohol intake in the previous 10 hours 	<ul style="list-style-type: none"> • Nystagmus is gradual in onset and persistent when the position is held, it is not fatigable in all the positions in which it is evoked and it does not show latency • Horizontal persistent nystagmus observed while sitting with the head erect, reverses its beating direction due to the head pitch test, thus showing that the cupula is gravity sensitive • Nystagmus evoked by seated supine positioning maneuver beats toward the same direction of the one observed while sitting with the head erect • Persistent direction changing positional nystagmus is evoked on each side while supine, geotropic or apogeotropic. Two neutral points are identified rotating the head in the yaw plane while supine: The first neutral point with the head rotated about 30° toward the affected ear and the second one in the 180° opposite position. The nystagmus reverses its beating direction once the head is rotated beyond each neutral point in the yaw plane • The nystagmus evoked by the HYT is usually more intense on one side, beating stronger toward the affected ear • Liberatory maneuvers are always ineffective in modifying the nystagmus

Table 6: Apogeotropic PDCPN clinical features: Cupulolithiasis vs nonotolithic cause

Cupulolithiasis	Nonotolithic
<ul style="list-style-type: none"> The time elapsed from symptom onset until otoneurological examination ranges from 2 to 6 weeks Symptoms are generally fairly well-tolerated, without violent vertigo, but with dizziness while upright HYT is performed inducing poorly or no neurovegetative symptoms Liberatory maneuvers usually resolve nystagmus and symptoms either previously transforming it into a geotropic one or less frequently with no conversion The maneuver's effectiveness is increased by using the mastoid vibrator 	<ul style="list-style-type: none"> Patient's history and/or family history positive for migraine Sudden and abrupt onset of symptoms for which the patient is usually visited after a short delay, less than 12 hours Vertigo is poorly tolerated and usually associated with severe neurovegetative symptoms Liberatory maneuvers are absolutely inefficient in modifying and resolving both the nystagmus and associated vertigo. Osmotic diuretics have been found effective in solving both vertigo and nystagmus after about 1 hour³¹

in patients suffering from migraines whose case history and clinical features are summarized in Tables 5 and 6.^{1,9,32}

ASC BPPV

Although some authors report higher incidence rates, this is the less common form of BPPV, accounting for only 1 to 2% of all BPPV cases in our experience.

The patient usually experiences his/her ASC BPPV attack while moving the head in the sagittal plane. The patient suffers a new attack every time he flexes or extends the head while upright, or even by rotating toward the affected ear while supine. Vertigo is not generally violent and is associated with dizziness when walking.

ASC BPPV is more frequent in posttraumatic BPPV with multiple canal involvement.

Pathophysiology

Canalolithiasis: Free floating debris inside the anterior semicircular canal make its cupula sensitive to linear accelerations, i.e. Gravity and accelerations provoked by brisk head movements on the same plane of the involved ASC.

ASC BPPV Diagnosis

The diagnosis is performed identifying the ASC BPPV canalolithiasis nystagmus. It is evoked by an ampullofugal, thus excitatory flow of the debris caused by positioning tests. ASC BPPV nystagmus shows a quick phase with a geotropic torsional component, which is counterclockwise for right ASC and clockwise for left ASC. The vertical component is always down beating. Actually, often the torsional component is not well evident and ASC nystagmus rarely appears as a real paroxysmal one.

Diagnostic Tests

The diagnostic test for ASC BPPV is the Dix-Hallpike maneuver (D-H). When this maneuver is performed on one side the opposite side ASC is checked, i.e. right D-H checks left ASC, left D-H checks right ASC.

The ASC BPPV diagnosis is sometimes not easy to do, as the ASC involvement of one side can show a nystagmus provoked by a bilateral Dix-Hallpike and by straight head-hanging positioning too.

The differential diagnosis should be made with other canalolithiasis variants and particularly with the PSC BPPV apogeotropic variant.

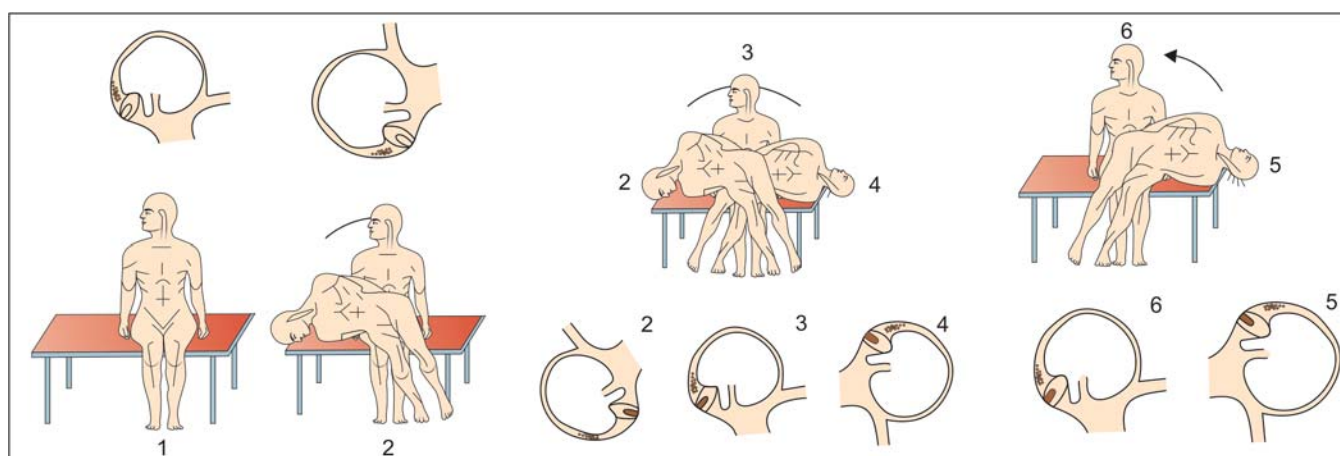


Fig. 20: ASC BPPV Vannucchi maneuver for right ASC BPPV: The patient sits on the examination bed edge with his/her legs dangling, (1) patient's head is rotated 45° toward the affected side, (2) the patient is quickly brought down reaching the bed face-down, (3) thus, reaching the bed face-up by a unique movement, (4) the patient is rapidly tilted to the opposite side, without stopping in the middle 5-6 finally the patient goes back to a seated position

In this regard it is useful to repeat diagnostic tests more times, magnifying the eyes by double cameras VNS, one for each eye. The ASC BPPV diagnosis is confirmed when the positional downbeating nystagmus, with or without a torsional component, completely recovers after therapeutic maneuvers.

ASC BPPV Therapy

We have found two techniques to be equally efficient:

CRP (Epley maneuver) performed from the healthy side toward the involved one.

ASC BPPV Vannucchi maneuver (Fig. 20).³³

REFERENCES

- Carmona S, Asprella-Libonati G. Neuro-Otology. Third edition. Buenos Aires 2011, Akadia (Ed).
- Epley JM. Positional vertigo related to semicircular canalolithiasis. *Otolaryngol Head Neck Surg* 1995;112:154-61.
- Epley JM. New dimensions of benign paroxysmal positional vertigo. *Otolaryngol Head Neck Surg* 1980 Sep-Oct;88(5):599-605.
- Epley JM. The canalith repositioning procedure: For treatment of benign paroxysmal positional vertigo. *Otolaryngol Head Neck Surg* 1992 Sep;107(3):399-404.
- Epley JM. Caveats in particle repositioning for treatment of canalolithiasis (BPPV) *Operative Techniques in Otolaryngology—Head and Neck Surgery*, 1997 June;8(2):68-76.
- Epley JM. Human experience with canalith repositioning maneuvers. *Ann N Y Acad Sci* 2001 Oct;942:179-91.
- Asprella-Libonati G, Epley JM. Management of positional vertigo: A nystagmus-based approach. Abstract Book 25° Barany Society Meeting. Kyoto Japan March 31-April 3 2008;S7-1, p.89.
- Asprella-Libonati G. La Terapia della Labirintolitiiasi: Strategie di intervento individualizzato. In: Atti congressuali Aggiornamenti di Vestibologia - Ed. Grunenthal-Formenti - Fiuggi - 2004.
- Asprella-Libonati G. Gravity sensitive cupula of posterior semicircular canal. In online supplementary information (pp188-199) of the basic and clinical ocular motor and vestibular research: A Tribute to John Leigh, edited by J. Rucker and DS Zee, NYAS, New York, *Ann. NY Acad Sci* 2011 Sept;1233.
- von Brevern M, Radtke A, et al. Migrainous vertigo presenting as episodic positional vertigo. *Neurology* 2004;62:469-72.
- Vannucchi P, Giannoni B, Pecci R. Labirintolitiiasi: la variante apogeotropica della VPP del CSP. Oral communication presented at XXXII National Meeting of Società Italiana di Audiologia e Foniatria. Firenze -Oct. 2009.
- Hemenway WG, Lindsay JR. Postural vertigo due to unilateral sudden partial loss of vestibular function. *Ann Otol Rhinol Laryngol* 1956 Sep;65(3):692-706.
- Cipparrone L, Corridi G, Pagnini P. Cupulolithiasis. In: V Giornata Italiana di Nistagmografia Clinica. Nistagmografia e patologia vestibolare periferica. Milano: CSS Boots-Formenti 1985; 36-53.
- Pagnini P, Nuti D, Vannucchi P. Benign paroxysmal vertigo of the horizontal canal. *ORL J Otorhinolaryngol Relat Spec* 1989;51:161-70.
- Nuti D, Vannucchi P, Pagnini P. Benign paroxysmal positional vertigo of the horizontal canal: A form of canalolithiasis with variable clinical features. *J Vestib Res* 1996;6:173-84.
- Pagnini P, Vannucchi P, Nuti D. Le nystagmus apogéotropes dans la vertige paroxystique positionnel bénin du canal sémicirculaire horizontal: une canalolithiasis. *Revue d'ONO* 1994;31:17-19.
- Nuti D, Vannucchi P, Pagnini P. Lateral canal BPPV: Which is the affected side? *Audiological Medicine* 2005;3:16-20.
- Bisdorff AR, Debatisse D. Localizing signs in positional vertigo due to lateral canal cupulolithiasis. *Neurology* 2001 Sep 25;57(6):1085-88.
- Bisdorff AR, Debatisse D. A new differential diagnosis for spontaneous nystagmus: Lateral canal cupulolithiasis. *Ann N Y Acad Sci* 2002 Apr;956:579-80.
- Asprella-Libonati G, Gagliardi G, Cifarelli D, Larotonda G. Step by Step treatment of lateral semicircular canal canalolithiasis under videonystagmoscopic examination. *Acta Otorhinolaryngol Ital* 2003;23:10-15.
- Asprella-Libonati G. Diagnostic and treatment strategy of the lateral semicircular canal canalolithiasis. *Acta Otorhinolaryngol Ital* 2005;25:277-83.
- Asprella-Libonati G. Pseudo-spontaneous nystagmus: A new clinical sign to diagnose the affected side in lateral semicircular canal benign paroxysmal positional vertigo. *Acta Otorhinolaryngol Ital* 2008;28:73-78.
- Asprella-Libonati G. Lateral semicircular canal benign paroxysmal positional vertigo diagnostic signs. Letter to the Editor. *Acta Otorhinolaryngol Ital* 2010;30:222-24.
- Lempert T, Tiel-Wilck K. A positional maneuver for treatment of horizontal-canal benign positional vertigo. *Laryngoscope* 1996;106:476-78.
- Asprella-Libonati G, Gufoni M. Vertigine parossistica da CSL: manovre di barbecue ed altre varianti. In: Nuti D, Pagnini P, Vicini C (Eds). *Atti della XIX Giornata di Nistagmografia Clinica*. Milano: Formenti 1999;321-36.
- Vannucchi P, Asprella-Libonati G, Gufoni M. The physical treatment of lateral semicircular canal canalolithiasis. *Audiological Medicine* 2005;3:52-56.
- Baloh RW, Yue Q, Jacobson KM, Honrubia V. Persistent direction-changing positional nystagmus: Another variant of benign positional nystagmus? *Neurology* 1995 Jul;45(7):1297-301.
- Hiruma K, Numata T. Positional nystagmus showing neutral points. *ORL J Otorhinolaryngol Relat Spec* 2004;66(1):46-50.
- Bergenius J, Tomanovic T. Persistent geotropic nystagmus: A different kind of cupular pathology and its localizing signs. *Acta Otolaryngol* 2006 Jul;126(7):698-704.
- Hiruma K, Numata T, Mitsuhashi T, Tomemori T, Watanabe R, Okamoto Y. Two types of direction-changing positional nystagmus with neutral points. *Auris Nasus Larynx* 2011 Feb;38(1):46-51.
- Epley MJ, Asprella Libonati G. Endolymphatic density changing positional nystagmus. Abstract Book 25° Barany society Meeting. Kyoto Japan 2008 March 31-April 3;02-6, p. 140.
- Asprella-Libonati G. Gravity sensitive cupula: Light/heavy cupula of lateral semicircular canal (LSC). *J Vest Res* 2010;20:208-09.
- Vannucchi P. Manovra terapeutica per la VPPB del CSA. *Otoneurologia* 2000;June 2003, N.14, 3-7.

ABOUT THE AUTHOR

Giacinto Asprella Libonati

Head of the Unit of Audiology-Vestibology and Phoniarty, Department of Otorhinolaryngology and Head and Neck Surgery, 'Madonna delle Grazie' Hospital, Matera, Italy

Correspondence Address: Recinto VI Lucana, 3,75100 Matera, Italy
e-mail: asprella@alice.it-asprella@tin.it, website: www.otorinomatera.it