

Traumatic Optic Neuropathy

¹Bachi T Hathiram, ²Vicky S Khattar, ³Supriya Rode

¹Professor and Head, Department of ENT and Head and Neck Surgery, TN Medical College and BYL Nair Charitable Hospital
Mumbai, Maharashtra, India

²Assistant Professor, Department of ENT and Head and Neck Surgery, TN Medical College and BYL Nair Charitable Hospital
Mumbai, Maharashtra, India

³Resident, Department of ENT and Head and Neck Surgery, TN Medical College and BYL Nair Charitable Hospital
Mumbai Maharashtra, India

Correspondence: Bachi T Hathiram, Professor and Head, Department of ENT and Head and Neck Surgery, Flat No. 2, Ground Floor, MN Banaji Building, Forjett Street Cross Lane, Mumbai-400036, Maharashtra, India, e-mail: bachi.hathiram@rediffmail.com

ABSTRACT

Introduction: Traumatic optic nerve damage after craniofacial injury was first described by Hippocrates.¹ Although the natural history of traumatic optic neuropathy is unknown, recent studies suggest that high dose steroids and, even surgical decompression of the optic canal or the nerve sheath (in cases of nerve sheath hematoma) may restore vision in selected patients.²⁻⁸ The commonest cause of optic nerve trauma is road-traffic accidents, when the patient has poly-trauma with head injury and the visual loss is noticed only after the general condition of the patient improves. Isolated trauma of the optic nerve is usually associated with blunt skull trauma involving fractures of both skull and optical canal, but may also occur from blunt ocular trauma.⁹ Iatrogenic trauma to the optic nerve is not unknown.

Pathophysiology: The part of the optic nerve most vulnerable to blunt trauma of the head is the intracanalicular segment, which by virtue of its bony course is vulnerable to the fractures and compressive-elastic forces of its surrounding bone, which also being unyielding, allows for no space for inflammatory expansion or hemorrhage.¹⁰ Optic neuropathy following accidental trauma usually results from two distinct mechanisms: A primary injury as a result of a direct contusive force on the optic canal and nerve, which if untreated results in a secondary ischemia with further damage to the nerve.

Investigations: Clinical assessment should include testing of visual acuity, extraocular muscle motility and papillary reactivity, visual field assessment and direct/indirect ophthalmoscopy. Visual evoked potentials (VEPs) to flash stimulation and the electroretinogram (ERG) might be supportive in unresponsive patients in the immediate aftermath of the traumatic event.^{11,12} The role of neuroimaging remains controversial, and practice varies between institutions. Recently, ultrasonography has been advocated to screen and detect abnormalities in optic nerve diameter.

Management: Currently, there is no validated approach to the management of traumatic optic neuropathy. Thus, with numerous conflicting reports on the management of traumatic optic neuropathy, there is little world consensus on the optimal management of this condition. Keeping in mind the above, we have devised a management protocol for the same, simultaneously discussing the role of conservative/medical management as well as the surgical protocols followed by us.

Discussion and conclusion: In summary, optic nerve decompression alone or combined with decompression of the nerve sheath may be indicated in selected patients who fail to respond to high-dose intravenous steroids. The definitive role of surgery in the management of traumatic optic neuropathy remains unclear. There is a need for a large, prospective, randomized controlled trial to assess the different therapeutic approaches in traumatic optic neuropathy, but such a trial may be challenging given the low frequency of the condition and the difficulties inherent in randomizing patients.

Keywords: Traumatic optic neuropathy, Optic nerve decompression, Optic nerve injury, Optic nerve sheath, Endoscopic skull base surgery, Visual loss.

INTRODUCTION

Of the three segments of the optic nerve—extraorbital, canalicular and intracranial—surgical decompression is directed to the canalicular segment, where the nerve passes through a bony canal and is prone to compression. The extraorbital segment of the optic nerve is usually spared from injury due to its laxity and the buffering effect provided by the surrounding fat and extraocular muscles. The intracranial segment is protected by the surrounding brain and bone as well as the fact that shearing forces are usually absorbed by the intracanalicular segment thus not reaching the intracranial segment. Some investigational studies have shown that blows to the malar and frontal areas are transmitted mostly to the optic foramen.² These forces may cause compression, shearing, contusion and stretching

injuries to the optic nerve, even in the absence of a fracture. Furthermore, the sheath of the optic nerve is firmly attached to the optic canal, and the canal itself is a closed bony space, not flexible to any edema or hemorrhage.^{2,3}

Traumatic optic neuropathy can occur following an innocent ipsilateral injury over the superior temporal orbital rim and is characterized by vision loss without external or internal ophthalmic evidences of injury to the eye and its nerve.^{4,7} In many cases, due to the coexistent head injury and its associated comorbidities, the visual status may not be amenable for assessment. In fact, major brain injury occurs in 40 to 72% of patients with traumatic optic neuropathy, the management of which takes precedence.¹⁶ This may often lead to a delay in diagnosis and subsequent timely treatment for a potentially reversible visual loss.

Patients with head injury who are suspected to have a coexistent optic nerve trauma [which may be indicated by contusions around the eye (the characteristic 'raccoon sign') (Fig. 1), an afferent pupillary defect (Fig. 1), with corresponding fundoscopic changes of disk edema and vascular congestion or an actual complaint of loss of vision in one/both eyes] warrant urgent radiological investigations. While a high resolution CT scan of the paranasal sinuses and orbit would reveal any obvious fracture, hem sinus and coexisting trauma, such as fractures of the skull base, it would also serve as a road map for surgery. An MRI would be helpful in delineating the integrity of the optic nerve and also help in ruling out nerve sheath hematomas. Usually, a clinical suspicion coupled with positive radiological findings may provide enough grounds for surgical intervention; nevertheless, there are certain other investigations which may be performed when in doubt.¹⁰

Iatrogenic injury to the optic nerve during endoscopic sinus surgery is not unknown. The intimate relation between the paranasal sinuses and the optic nerve places the nerve at risk of injury during sinus surgery, especially surgery of the ethmoid sinuses, more so during ethmoidal surgery by a less experienced surgeon.

Pathophysiology

The part of the optic nerve most vulnerable to blunt trauma of the head is the intracanalicular segment, which by virtue of its long course within a bony canal, is vulnerable to fractures and compressive-elastic forces of the surrounding bone, which also being unyielding, allows for no space for inflammatory expansion or hemorrhage. Compression may occur either because of a fracture of the bony canal or because of intraneural contusion and hemorrhage, secondary vasospasm and veno-occlusion, edema and necrosis.^{15,16}

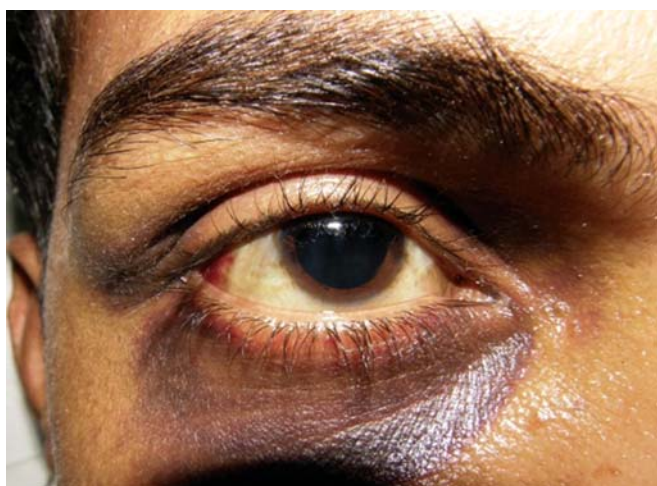

Fig. 1: The posttraumatic periorbital contusion which gives the eye a characteristic 'Raccoon-eye' look. Also, note the relative afferent pupillary defect seen in the affected eye (absence of pupillary constriction in response to light)

These pathophysiological developments cause intraneurals welling leading to a compartmental syndrome within the constricting confines of the bony optic canal, with progressively increasing veno-occlusion, consequent tissue edema and further veno-occlusion. The visual loss caused by veno-occlusion and compression may be initially reversible, but progressive compression may lead to arterial obstruction and irreversible infarction.¹⁷

Iatrogenic injury of the optic nerve may occur due to a variety of factors which include anatomic variations in the course of the nerve, such as the type III/IV optic nerve or a nerve coursing through a dominant sphenoid sinus of the opposite side, dehiscence bony canal, erosion of the bony canal due to some disease process, excessive hemorrhage impeding visibility during surgery, etc. Most of these problems can be averted by a thorough study of the CT scan prior to surgery and, if required, even review of the same during surgery.¹⁰ It would not be out of place to insist on refining surgical skills by cadaveric dissections prior to embarking on ambitious endoscopic surgery. Also, the presence and guidance of an experienced colleague may be sought, when performing especially difficult endoscopic procedures.

Investigations

Most cases of traumatic optic neuropathy occur following road traffic accidents and the patients usually suffer from polytrauma with a poor general condition on admission. If the patient is unconscious, optic nerve injury is usually missed out until the patient regains consciousness and gives a history of loss of vision. Thus, precious time may be lost. The general condition of the patient needs to be stable, if not good to withstand the anesthesia required for endoscopic surgery.

However, in the case of iatrogenic trauma to the optic nerve, direct optic nerve injury should be suspected, if the pupil dilates rapidly during surgery (either from globe ischemia or from damage to pupillomotor nerves) or if, after surgery, there is severe visual loss with a poorly reactive pupil and a relative afferent pupillary defect.²¹

Specific investigations warranted in a case of traumatic optic neuropathy, and their principles and indications are briefly outlined below:

- *Afferent pupillary defect:* An absolute or relative afferent pupillary defect indicates that vision is being compromised. It can be tested by shining a bright focused light for a few seconds on the 'unaffected' eye, with the patient looking at a distance, in a dark room and noting the pupillary response, which is normally characterized by miosis. Following this, the light is shone on the 'affected' eye, and the pupillary response is compared to its 'normal' counterpart. Features sought

after are, a lack of briskness/sluggish miosis as compared to the normal side, a partial or complete absence of miosis. This usually indicates a defect in the afferent pupillary pathway and has been termed as a 'Marcus Gunn' pupil (Fig. 1). It is best interpreted along with fundoscopic and radiologic signs. It may also be elicited subjectively, by asking the patient to compare the difference in the brightness perceived between the unaffected and affected eyes.¹⁰

- **Fundoscopy examination:** Various appearances can manifest in traumatic optic neuropathy namely disk edema, congestion of vessels, disk pallor, etc. but the most common presentation is usually a normal looking disk, especially in the early stages.¹⁰
- **Color vision:** Loss of color vision, namely red color vision, patients with optic neuropathy often have red color desaturation and a positive response would be that the red color looks 'faded', 'pink' or 'washed out'.⁴⁸
- **Visual field defects:** Almost any type of field defect can be seen in cases of traumatic optic neuropathy, but commonly arcuate, central or hemianopic field defects may be seen.⁴⁸
- **Visual evoked potentials (VEPs):** These represent the cortical response to light stimulus and may be useful in cases of patients with delayed optic neuropathies, wherein the decision to intervene may depend upon the VEP response.¹⁰
- Visual evoked potentials (VEPs) to flash stimulation and the electroretinogram (ERG) might be supportive in unresponsive patients in the immediate aftermath of the traumatic event.^{11,12}
- In patients who present late with suspected optic atrophy, 'slit-like' or 'wedge-shaped' defect can be seen in the prepupillary nerve fiber layer which may be seen with either a red-free ophthalmoscope or by optical coherence tomography (OCT). OCT a newer technique that uses low coherence light to penetrate tissue and a camera to analyze the reflected image. It performs circular scans around the optic nerve head to analyze the peripupillary nerve fiber layer and may be used in the follow-up for patients with traumatic optic neuropathy.⁴⁸
- **CT scan:** A high resolution CT scan of the paranasal sinuses and orbit, with windows taken at a distance of 1 mm, besides providing a 'road-map' for surgery as this is of utmost importance in endoscopic surgery (especially helping to detect anatomic variations), also helps to reveal any fractures of the orbital apex and optic canal, with/without impinging fracture fragments. It may also reveal any coexisting injury to the skull base, and other structures in the vicinity of the sphenoid sinuses, which may warrant additional precautions and/or simultaneous surgical interventions, e.g. cerebrospinal

fluid (CSF) leaks. It can also detect any anatomical variations which may impede surgical access to the optic nerve. Usually brain scans should also be done to rule out coexisting brain injury, since the intracanalicular portion of the optic nerve is within the skull base.¹⁰

- **MRI scan:** An MRI is useful to detect optic atrophy, the integrity of the nerve as well as to rule out nerve sheath hematomas.¹⁰
- **Ultrasonography:** The role of neuroimaging remains controversial and practice varies between institutions. While some colleagues request computed tomography (CT) and/or magnetic resonance imaging (MRI) for diagnosis, others limit these to patients with progressive visual deterioration or if therapeutic interventions are being considered. The clinical value of neuroimaging in traumatic optic neuropathy is further debatable since there is no consistent correlation between the finding of an optic canal fracture, the severity of visual loss and the prognosis for visual recovery. Recently, ultrasonography has been advocated to screen and detect abnormalities in optic nerve diameter in patients who have experienced head trauma that could involve the optic nerve,^{18,19} including its use in bedside emergency department conditions.²⁰

DISCUSSION AND MANAGEMENT PROTOCOLS

The natural history of traumatic optic neuropathy is unknown, and even the exact mechanism by which corticosteroids reduce optic nerve injury is unclear.²⁻⁸ The rationale for treatment is as follows: Steroids probably decrease the intraneural or extraneural edema and relieve compression of the nerve fibers.⁵ By reducing vasospasm steroids may also limit contusion necrosis of the nerve. The effect of steroids on the resorption of an optic nerve sheath hematoma is also unclear. Surgical evacuation of nonresorbing nerve sheath hematoma should be considered when initial treatment with steroids fails to improve vision.²²⁻²⁵ Timely surgical optic nerve sheath decompression is initiated in order to avoid irreversible damage to the axons of the optic nerve compressed by the subarachnoid blood within the swollen nerve sheath.

In the case of iatrogenic traumatic neuropathy, it is general consensus that prevention is better than cure. Certain guidelines which should be kept in mind prior to embarking on endoscopic sinus surgery by the young and inexperienced surgeon would include a thorough reading of the CT scan preoperatively. Identification of sphenoidal cells (Onodi), which occur in 8 to 14% of the general population before surgery is critical. Mistaking Onodi cells for the sphenoid sinus can lead to incomplete dissection and place the optic nerve and the orbit at risk. The type of course of

the optic nerves through these Onodi cells is also to be noted, since type III and type IV optic nerves are most prone to inadvertent injury, if not noticed on the CT scan (Figs 2 and 3). Also, both optic nerves running through the walls of a dominant sphenoid sinus should be kept in mind and checked for (Fig. 4). Both the optic nerve and the carotid artery form an indentation in the lateral wall of the sphenoid sinus (Fig. 5). This can be unilateral or bilateral. Five to seven percent of these have dehiscent bone which exposes these two vital structures to the intraoperative injury. Preoperative imaging in the axial plane reveals excellent detail of the sphenoid sinus and its relationship with these two structures, thus avoiding iatrogenic complications. Intravenous anesthesia, relative hypotension and relative bradycardia minimize intraoperative blood loss. Topical decongestants, prothrombotic agents and bipolar cautery should be available.

It is advisable to keep the eyes uncovered during endoscopic surgery so that surgery can be stopped immediately, if there is any indication of orbital swelling, afferent pupillary defect or eyelid bruising. Direct optic nerve injury should be suspected, if the pupil dilates rapidly during surgery (either from globe ischemia or from damage to pupillomotor nerves) or if, after surgery, there is severe visual loss with a poorly reactive pupil and a relative afferent pupillary defect.

Role of Conservative Management

Carta et al (2003)⁴⁹ have identified four negative prognostic factors which may help in determining the eventual visual prognosis in cases of traumatic optic neuropathy following head trauma, which include:

- Presence of blood within the posterior ethmoid cells
- Age over 40 years

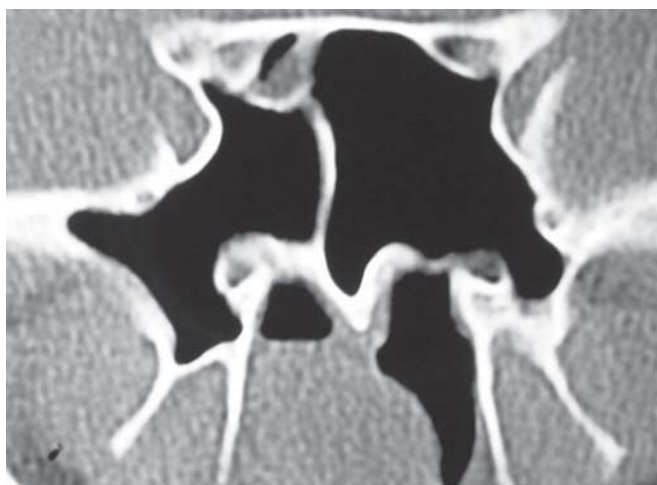


Fig. 2: Coronal CT scan of the paranasal sinuses showing a type III optic nerve running through the Onodi cell

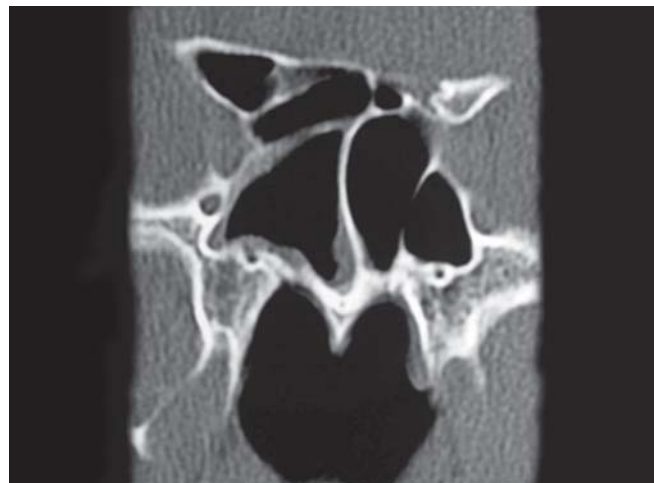

Fig. 3: Coronal CT scan of the paranasal sinuses showing a type IV optic nerve running through the Onodi cell

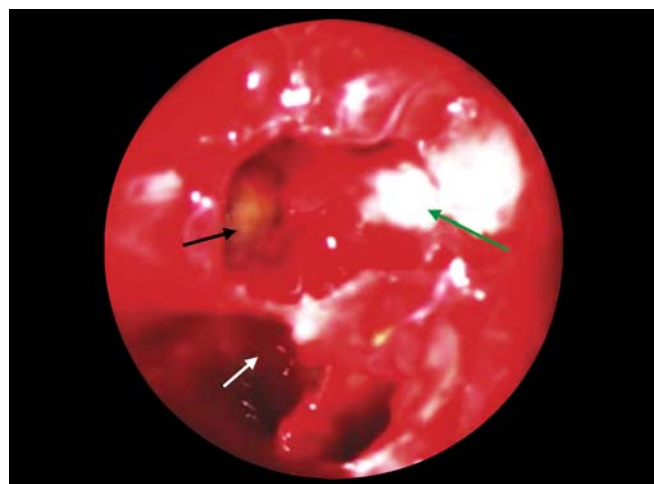


Fig. 4: Intraoperative view of a left optic nerve (green arrow) coursing through a dominant right sphenoid sinus (black arrow). The left sphenoid is denoted by the white arrow

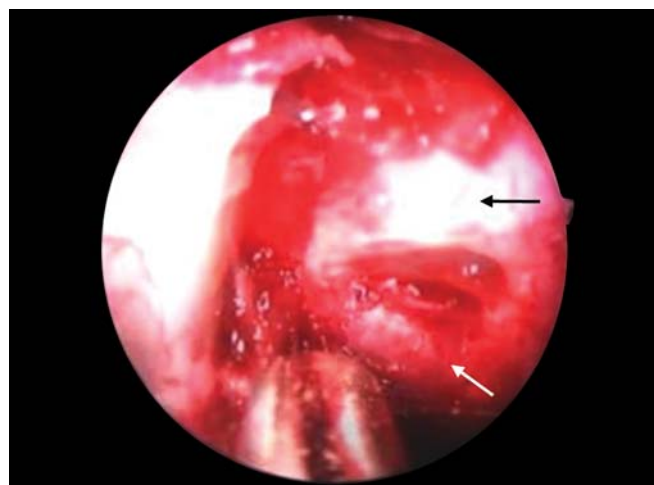


Fig. 5: Intraoperative endoscopic view showing the close proximity of the optic nerve (black arrow) to the carotid artery (white arrow) within the lateral wall of the sphenoid sinus

- Loss of consciousness associated with traumatic optic neuropathy
- Absence of recovery of visual acuity after 48 hours of steroid therapy.

Comparative data from the International Optic Nerve Trauma Study (IONTS) group show that neither corticosteroid therapy nor optic canal decompression are the gold standard for treatment of traumatic optic neuropathy. However, on the other hand, Cook et al (1996)³⁵ in a meta-analysis reported that recovery of vision in patients treated with megadosage steroids or surgical decompression of the optic canal was significantly better than recovery in patients receiving no treatment. The rationale for the use of megadose methyl prednisolone for traumatic optic neuropathy is based on the improvement seen with the same in cases with acute spinal injuries; in fact, similar doses have also been recommended, i.e. a loading dose of 30 mg/kg given intravenously, followed by a maintenance dose of 5.4 mg/kg/hr, with monitoring of visual acuity.³⁵ The timing is crucial for starting this therapy, and there have been numerous reports in literature as regards the importance of initiating the therapy as soon as possible. There have also been reports of megadose steroids causing deleterious effects to the visual outcome, if started after 8 hours of trauma.⁵⁰ However, most centers in the world today have incorporated this therapy as the initial definitive management; the subsequent visual prognosis being the deciding factor for further surgical intervention vs continuation of megadose steroid therapy. The usual cut-off period after the initiation of megadose steroids at which the decision for surgical decompression may be undertaken is 48 hours;⁵² thus failure of improvement or even worsening of the visual status, after initiation of megadose steroid therapy for 48 hours, would warrant surgical optic nerve decompression.¹⁰

There is again no consensus regarding the duration of megadose steroid therapy, but an average minimum of 3 to 5 days is usually warranted, which may be followed up with a lower maintenance dose for 7 to 10 days, with continuous monitoring of blood sugar levels and the cardiac status, besides the usual adjunctive measures, such as calcium supplements, etc.¹⁰

The initiation of steroid therapy would form the initial line of therapy, regardless of the mechanism of traumatic optic neuropathy. This may also buy time for radiological investigations to be undertaken, besides being helpful in reducing the primary and secondary ischemia of the optic nerve due to edema within its bony canal. However, if the radiological investigations suggest an obvious fracture with fragment(s) impinging on the optic nerve, the 48 hours wait-period should be waived, and an immediate surgical optic nerve decompression be performed.

Surgical Management

The definitive role of surgery in the management of traumatic optic neuropathy remains unclear until a protocol is adopted on a multicenter level. Initiation of steroids for 24 to 48 hours affords sufficient time for consultations, radiological studies and conference with the patient and family prior to any surgical intervention.

A review of literature has documented that prognosis following optic nerve decompression may be influenced by patient age,^{31,32} presence or absence of fractures.^{33,35} preoperative vision,^{30,31,33,35} grade of injury³⁵ and delay from injury to surgery.³⁴

Surgical decompression of the optic nerve seeks to relieve the compression on the nerve fibers. Such compression may be either 'external' (e.g. displaced fracture or extraneural hematoma) or 'internal' (e.g. secondary to intraneural edema or hematoma and consequential compartmental syndrome). Internal compression may not be completely relieved by bony decompression alone and would be better relieved by a further slitting of the optic nerve sheath and the fibrous annulus of Zinn.²⁹

The definitive indications for traumatic optic nerve decompression would include as follows:

- Radiologically, evident bony fracture fragment impinging on the intracanalicular portion of the optic nerve in the lateral wall of the related sphenoid sinus (Fig. 6), or an optic nerve sheath hematoma (as seen on MRI), in a patient with traumatic optic neuropathy with a vision of <6/60 at presentation.
- Failure to improve/deterioration of vision after 48 hours of megadose steroid therapy in a patient with traumatic optic neuropathy with vision <6/60 at presentation, with no obvious radiological evidence of compromise in the volume of the optic canal by a hematoma or fracture fragment impingement. This may include any probable canal injury⁵² in patients with a similar clinicoradiological profile, indicated by the presence of fluid levels in the posterior ethmoid and sphenoid sinuses, and/or the presence of fractures of the ethmoids, orbital apex and sphenoid.

Today, transnasal endoscopic optic nerve decompression is the gold standard due to a decrease in the morbidity associated with the erstwhile external and transcranial approaches to the nerve. However, there are certain potential complications associated with this procedure, some of which may be a consequence of the trauma causing the optic neuropathy and some may be due to certain anatomical variations and considerations discussed above which should be kept in mind. The ophthalmic artery usually runs through the postero-inferior quadrant of the optic nerve, but may sometimes run around the latter's lower edge and into the surgical

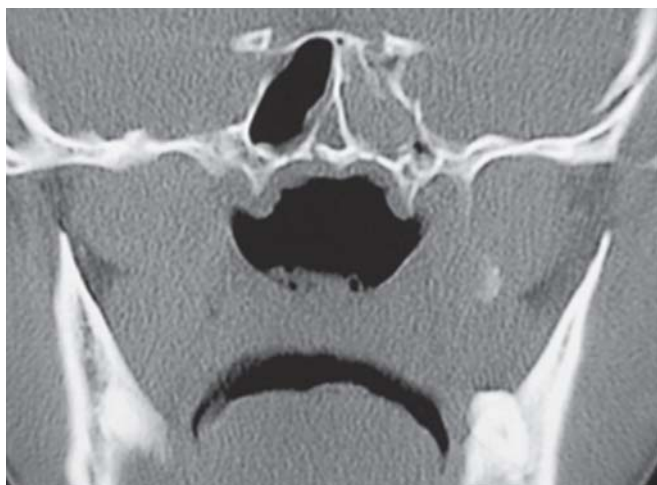

Fig. 6: Coronal CT scan of the paranasal sinuses showing the bony fracture fragment impinging on the left optic nerve with a left sphenoid hem sinus

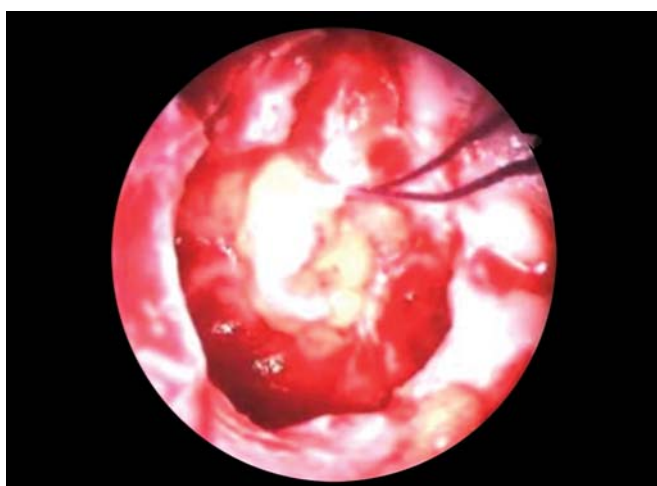

Fig. 7: A traumatic CSF leak in the skull base repaired using a connective tissue (fat) by the bath-plug technique

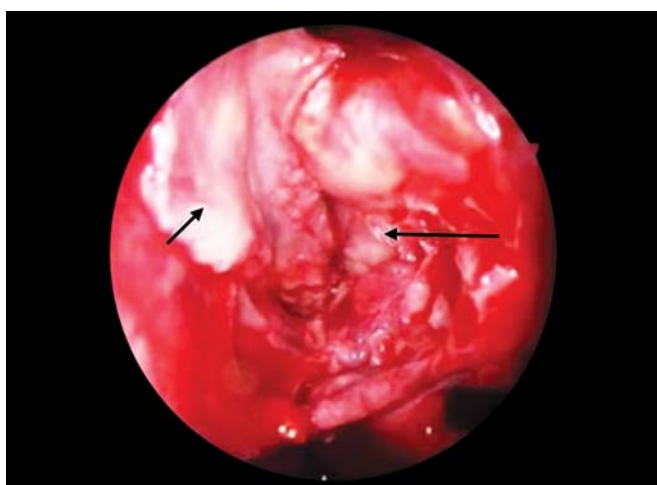


Fig. 8: Multiple hair-line fractures in the skull base repaired using a connective tissue (facia lata) carpet graft (short black arrow). The decompressed left optic nerve is denoted by the long black arrow

field.⁵³ The risk of damage to this artery may be minimized by incising the nerve sheath in its upper medial quadrant.^{37,51} Concomitant damage to the base of the skull with a resultant CSF leak may occur as a result of the trauma or may occur iatrogenically, while decompressing the optic nerve. In any case, once detected, it should be managed simultaneously endoscopically by sealing the site of leak using a connective tissue either as a bath-plug or a carpet—graft in a multilayered closure (Figs 7 and 8). Use of nasal packs is to be avoided to prevent pressure on the decompressed, bare optic nerve, however, some centers advocate the use of tissue glue to keep the connective tissue used for repair of the leak in place.

There is considerable controversy surrounding the question of slitting the sheath of the nerve in addition to decompressing the bony canal. Proponents of decompression of the nerve sheath note that the post-traumatic compartmental syndrome is best relieved by releasing the constricting sheath enveloping the nerve.^{36,37} Detractors of nerve sheath slitting, however, doubt its efficacy and also note that this may cause an occasional cerebrospinal fluid (CSF) leak, may potentially disrupt the pial vessels contributing to nerve vascularity, may disrupt the nerve fascicles and may also risk injury to the ophthalmic artery coursing in the optic canal.^{37,38} The layers of the optic nerve sheath as viewed from a medial transsphenoidal approach include the periosteal and dural layers of the duramater, arachnoid sheath, subarachnoid space and the pial sheath which is adherent to the nerve. Nerve sheath incisions may potentially be limited to the superficial dura mater alone and may not violate the subarachnoid CSF space.

The best timing for nerve decompression is yet a controversial topic. However, it is logical to assume that early surgical decompression would be more efficacious in reversing pathology than decompression that has been delayed by a few weeks. Of course, if there are fractured bony spicules seen on CT scan which are impinging on the optic nerve along its course, or the presence of a nerve sheath hematoma seen on the MRI scan, endoscopic decompression must not be delayed. But, in the event of absence of any positive findings radiologically, surgically decompressing the nerve whether justified and if so, which is the best time to do so, is still one of the gray areas in our field, with conflicting reports in literature. Early surgical decompression, however, has not been proved to be more efficacious than early treatment with steroids in conventional doses or megadoses.^{27,35} Moreover, optic nerve injury may be associated with other life-threatening and progressive injuries and also injury to the internal carotid artery,³⁴ in these scenarios, medical management is perceived as the safer initial treatment option. We therefore prefer initial

treatment with megadoses of steroids, and recommend surgical decompression only for patients who, despite such medical treatment, continue to have poor vision or whose vision progressively deteriorates. The efficacy of this treatment policy has been previously documented in the literature,³⁹ and many other studies have noted the potential of the nerve to recover even if surgery is delayed by a few months.⁴⁰⁻⁴⁶

CONCLUSION

Currently, there is no validated approach to the management of traumatic optic neuropathy. The rationale for intravenous corticosteroids in the treatment of traumatic optic neuropathy was derived from the results of the National Acute Spinal Cord Injury Study 2 (NASCIS 2). The NASCIS 2 was a multicenter clinical trial that evaluated patients with acute spinal cord injury treated with placebo, methylprednisolone or naloxone. Pharmacologically, corticosteroids are considered to reduce microvascular spasm and soft tissue edema via stabilization of the microvascular circulation and calcium homeostasis, thereby enhancing bloodflow and reducing cell death. The study showed that methylprednisolone started within 8 hours of injury was associated with a significant improvement in both motor and sensory function compared to patients treated with a placebo. Although widely accepted, the question whether corticosteroids are of similar effect in the treatment of traumatic optic neuropathy is unproven. The majority of case reports and series with corticosteroids in traumatic optic neuropathy are retrospective, nonconsecutive, nonrandomized and uncontrolled. Meanwhile, several nonclinical studies have questioned the therapeutic benefit associated with corticosteroids in acute traumatic optic neuropathy.^{16,26} The results from the CRASH trial indicated an even higher risk of mortality in patients with head injury treated with high-dose corticosteroids, thus, making the modality of management of this condition all the more precarious. However, it would be justified to speculate that the pure white matter optic nerve is not pharmacologically affected in the same manner as the mixed white and gray matter spinal cord.

The International Optic Nerve Trauma Study²⁷ was initiated to compare the visual outcomes of patients observed without treatment with those of patients treated with corticosteroids and of patients treated with optic canal decompression surgery. This multicenter, comparative, interventional but nonrandomized trial comprised 133 patients with traumatic optic neuropathy from 16 countries. Treatment decisions were according to the investigators' customary practice and no specific protocols for corticosteroid treatment or surgical technique were followed. The results showed that visual acuity improved in 32% of patients treated with surgery, in 52% of patients treated with corticosteroids, and in 57% of untreated patients. Thus, there was no clear benefit observed with either corticosteroid therapy or optic canal decompression. The results further showed that neither the dosage or timing of corticosteroid treatment nor the timing of optic canal decompression were associated with an increased probability of improved visual acuity.

We personally feel (see Table 1: Our experience) that neither corticosteroid therapy nor optic canal decompression should be considered the standard of care for patients with traumatic optic neuropathy and that therapeutic decisions should be made on an individual patient basis. Given the relatively high rate of spontaneous visual recovery, some studies concluded that there is no evidence that surgical decompression of the optic nerve provides any additional benefit.²⁸ However, in selected cases in which orbital bone fragments or foreign bodies impinge on, but do not transect the optic nerve, surgical intervention may be indicated. In any case, one should be aware of the fact that surgical intervention carries a definite risk of complications, such as collateral damage to structures of the orbital apex as well as other intracranial structures or iatrogenic direct and indirect optic nerve damage, the latter via disruption of the pia as well as postoperative cerebrospinal fluid leaks and meningitis.

Similar to corticosteroids, the use of surgery in traumatic optic neuropathy remains controversial and each case needs to be individually assessed for treatment options and the management protocols individualized for each patient.

Table 1: Management of traumatic optic neuropathy (2005-12)

Sr. No.	Indication	No. of patients	No visual recovery	Partial visual recovery	Complete visual recovery
<i>Endoscopic decompression</i>					
1	Accidental trauma	18	6	8	4
2	Iatrogenic trauma	1		1	
	Medical therapy only				
3	Accidental trauma	22	2	17	3
	Total	41	8	26	7

There is most definitely a need for a large, prospective, multicentric, randomized controlled trial to assess the different therapeutic approaches in traumatic optic neuropathy but such a trial may be challenging given the low frequency of the condition, and the difficulties inherent in randomizing patients.

ACKNOWLEDGMENT

We would like to thank the Dean, TN Medical College and BYL Nair Charitable Hospital, for permission to publish this article.

REFERENCES

- Chandwick J, Mann WN. The medical works of Hippocrates, Backwell, Oxford, England 1950.
- Anderson R, Panje W, Gross G. Optic nerve blinding following blunt forehead trauma. *Ophthalmology* 1982;89:445-55.
- Joseph MP, Lessell S, Rizzo J, Momose J. Extracranial optic nerve decompression for traumatic optic neuropathy. *Arch Ophthalmol* 1990;108:1091-93.
- Lam BL, Weingeist TA. Corticosteroid-responsive traumatic optic neuropathy. *Am J Ophthalmol* 1990;109:99-101.
- Spoor TC, Hartel WC, Lensink, Wilkinson MJ. Treatment of traumatic optic neuropathy with corticosteroids. *Am J Ophthalmol* 1990;110:665-69.
- Miller N. The management of traumatic optic neuropathy (Editorial). *Arch Ophthalmol* 1990;108:1086-87.
- Lessell S. Indirect optic nerve trauma. *Arch Ophthalmol* 1989;107:382-86.
- Wolin MJ, Lavin PJ. Spontaneous visual recovery after traumatic optic neuropathy after blunt head injury. *Am J Ophthalmol* 1990;109:430-35.
- Buchwald HJ, Weingärtner WE, Spraul CW, Wagner P, Lang GK. Contusion of the optic nerve after minor blunt ocular trauma: Case report and literature review. *Ophthalmologie* 1999;96(8):529-33.
- Hathiram BT, Khattar VS, Sonawane HP, Watve PJ. Traumatic optic neuropathy. Our experience. *Indian J Otolaryngol Head Neck Surg* 2010;62(3):229-35.
- Altenmüller E, Cornelius CP, Uhl H. Flash-evoked visual potentials in the early diagnosis of optic nerve injury due to craniofacial fractures. *EEG EMG Z Elektroenzephalogr Elektromyogr Verwandte Geb* 1991;22:224-29.
- Gellrich NC. Controversies and current status of therapy of optic nerve damage in craniofacial traumatology and surgery. *Mund Kiefer Gesichtschir* 1999;3(4):176-94.
- Kline LB, Morawetz RB, Swaid SN. Indirect injury of the optic nerve. *Neurosurgery* 1984;14:756-64.
- Kallela I, Hyrkas T, Pauku P, et al. Blindness after maxillofacial blunt trauma. *J Oral Maxillofac Surg* 1994;22:220-25.
- Walsh FB. Pathological-clinical correlations. I. Indirect trauma to the optic nerves and chiasm (II). Certain cerebral involvements associated with defective blood supply. *Invest Ophthalmol* 1966;5:433-49.
- Steinsapir KD, Goldberg RA. Traumatic optic neuropathy. *Surv Ophthalmol* 1994;38:487-518.
- Chen YR, Breidahl A, Chang CN. Optic nerve decompression in fibrous dysplasia: Indications, efficacy and safety. *Plast Reconstr Surg* 1997;99:22-30.
- Eidlitz-Markus T, Shuper A, Schwartz M, Mimouni M. Delayed posttraumatic visual loss: A clinical dilemma. *Pediatr Neurol* 2000;22:133-35.
- Karakitsos D, Soldatos T, Gouliamos A, Armaganidis A, Poularas J, Kalogeromitros A. Transorbital sonographic monitoring of the optic nerve diameter in patients with severe brain injury. *Transplant Proc* 2006; 38:3700-06.
- Tayal VS, Neulander M, Norton HJ, Foster T, Saunders T, Blaivas M. Emergency department sonographic measurement of optic nerve sheath diameter to detect findings of increased intracranial pressure in adult head injury patients. *Ann Emerg Med* 2007;49(4):508-14. Epub 2006 Sep 25.
- Rene C, Rose GE, Lenthall R, Moseley I. Major orbital complications of endoscopic sinus surgery. *Br J Ophthalmol* 2001;85:598-603.
- Sullivan KL, Brown GC, Forman AR, Sergott RC, Flanagan JC. Retrobulbar anesthesia and retinal vascular obstruction. *Ophthalmology* 1983;90:373-77.
- Hupp SL, Buckley EG, Burne SF, Tenzel RR, Glaser JS, Schatz NS. Posttraumatic venous obstructive retinopathy associated with enlarged optic nerve sheath. *Arch Ophthalmol* 1984;102:254-56.
- Guy J, Sherwood M, Day AL. Surgical treatment of progressive visual loss in traumatic optic neuropathy. *J Neurosurg* 1989;70:799-801.
- Hammer G, Ambos E. Das traumatische Optikuscheidenhamatomum und seine operative Behandlungsmöglichkeit. *Klin Monatsbl Augenheilkd* 1971;59:818-19.
- Ohlsson M, Westerlund U, Langmoen IA, Svensson M. Methylprednisolone treatment does not influence axonal regeneration or degeneration following optic nerve injury in the adult rat. *J Neuroophthalmol* 2004;24:11-18.
- Levin LA, Beck RW, Joseph MP, Seiff S, Kraker R. The treatment of traumatic optic neuropathy: The International Optic Nerve Trauma Study. *Ophthalmology* 1999;106:1268-77.
- Yu-Wai-Man P, Griffiths PG. Surgery for traumatic optic neuropathy. *Cochrane Database of Systematic Reviews* 2005:CD005024.
- Thakkar A, Tandon DA, Mahapatra AK. Surgery for optic nerve injury: Should nerve sheath incision supplement osseous decompression? *Skull Base* 2009;19:263-72.
- Mine S, Yamakami I, Yamaura A, et al. Outcome of traumatic optic neuropathy. Comparison between surgical and nonsurgical treatment. *Acta Neurochir (Wien)* 1999;141:27-30.
- Chen CT, Huang F, Tsay PK, et al. Endoscopically assisted transconjunctival decompression of traumatic optic neuropathy. *J Craniofac Surg* 2007;18:19-26.
- Levin LA, Joseph MP, Rizzo JF III, Lessell S. Optic canal decompression in indirect optic nerve trauma. *Ophthalmology* 1994;101:566-69.
- Wang BH, Robertson BC, Giroto JA, et al. Traumatic optic neuropathy: A review of 61 patients. *Plast Reconstr Surg* 2001; 107:1655-64.
- Rajiniganth MG, Gupta AK, Gupta A, Bapuraj JR. Traumatic optic neuropathy: Visual outcome following combined therapy protocol. *Arch Otolaryngol Head Neck Surg* 2003;129:1203-06.
- Cook MW, Levin LA, Joseph MP, Pinczower EF. Traumatic optic neuropathy. A meta-analysis. *Arch Otolaryngol Head Neck Surg* 1996;122:389-92.
- Thakkar A, Mahapatra AK, Tandon DA. Delayed optic nerve decompression for indirect optic nerve injury. *Laryngoscope* 2003;113:112-19.

37. Luxenberger W, Stammberger H, Jebeles JA, Walch C. Endoscopic optic nerve decompression: The Graz experience. *Laryngoscope* 1998;108:873-82.
38. Onofrey CB, Tse DT, Johnson TE, et al. Optic canal decompression: A cadaveric study of the effects of surgery. *Ophthal Plast Reconstr Surg* 2007;23:261-66.
39. Fujitani T, Inoue K, Takahashi T, Ikushima K, Asai T. Indirect traumatic optic nerve neuropathy—visual outcome of operative and nonoperative cases. *Jpn J Ophthalmol* 1986;30:125-34.
40. Niho S, Niho M, Niho K. Decompression of the optic canal by the transthemoidal route and decompression of the superior orbital fissure. *Can J Ophthalmol* 1970;5:22-40.
41. Fukado Y. Results in 400 cases of surgical decompression of the optic nerve. *Mod Probl Ophthalmol* 1975;14:474-81.
42. Sofferman RA. The recovery potential of the optic nerve. *Laryngoscope* 1995;105(supplement 72):1-38.
43. Matsuzaki H, Kunita M, Kawai K. Optic nerve damage in head trauma: Clinical and experimental studies. *Jpn J Ophthalmol* 1982;26:447-61.
44. Kountakis SE, Maillard AA, Urso R, Stiernberg CM. Endoscopic approach to traumatic visual loss. *Otolaryngol Head Neck Surg* 1997;116:652-56.
45. Girard BC, Bouzas EA, Lamas G, Soudant J. Visual improvement after transthemoid-sphenoid decompression in optic nerve injuries. *J Clin Neuroophthalmol* 1992;12:142-48.
46. Mine S, Yamakami I, Yamaura A, et al. Outcome of traumatic optic neuropathy. Comparison between surgical and nonsurgical treatment. *Acta Neurochir (Wien)* 1999;141:27-30.
47. Walsh FB, Hoyt WF. *Clinical neuro-ophthalmology*. Baltimore: Williams and Wilkins; 1969;2375.
48. Behbehani R. Clinical approach to optic neuropathies. *Clinical Ophthalmology* 2007;1(3):233-46.
49. Carta A, Ferrigno L, Salvo M, Bianchi-Marzoli S, Boschi A, Carta F. Visual prognosis after indirect traumatic optic neuropathy. *J Neurol Neurosurg Psychiatry* 2003;74:246-48.
50. Steinsapir KD. Treatment of traumatic optic neuropathy with high-dose corticosteroid. *J Neuroophthalmol*. Mar 2006; 26(1):65-67.
51. Chow JM, Stankiewicz JA. Powered instrumentation in orbital and optic nerve decompression. *Otolaryngol Clin North Am* Jun 1997;30(3):467-78.
52. Wormald PJ. Endoscopic optic nerve decompression. In *endoscopic sinus surgery anatomy: Three-dimensional reconstruction and surgical technique*. Thieme Medical Publishers, Inc. New York 2005:141-48.
53. Steinsapir KD, Seiff SR, Goldberg RA. Traumatic optic neuropathy: Where do we stand? *Ophthal Plast Reconstr Surg* May 2002;18(3):232-34.