

# Voice Rehabilitation after Laryngectomy

<sup>1</sup>Audrey B Erman, <sup>2</sup>Daniel G Deschler

<sup>1</sup>Department of Otolaryngology, Massachusetts Eye and Ear Infirmary, Harvard Medical School, Boston, Massachusetts, USA

<sup>2</sup>Director, Division of Head and Neck Surgery, Department of Otolaryngology, Massachusetts Eye and Ear Infirmary Associate Professor, Harvard Medical School, Boston, Massachusetts, USA

**Correspondence:** Audrey B Erman, Department of Otolaryngology, Massachusetts Eye and Ear Infirmary, Harvard Medical School, Boston, Massachusetts, USA

## Abstract

Improvements in voice rehabilitation over the past century have paralleled the surgical success of laryngectomy. The establishment of the tracheoesophageal puncture marked a turning point in the development of successful and dependable voice rehabilitation. Surgical options include both primary and secondary placement of a tracheoesophageal puncture. Though complications, such as pharyngoesophageal spasm or prosthesis leakage may occur, patients should expect functional voice restoration after laryngectomy.

**Keywords:** Voice rehabilitation, Laryngectomy, Tracheoesophageal puncture, Pharyngoesophageal spasm.

## INTRODUCTION

Even in the current era of evolving organ preservation protocols for treating laryngeal cancer, total laryngectomy continues to play a prominent role in curative treatment plans. Soon after the first reports of the laryngectomy procedure by Billroth, voice rehabilitation was likewise introduced as an important element in the treatment of laryngeal cancer. Just as the surgical success of laryngectomy improved since its introduction, the options to successfully restore voice have vastly improved over the past century. The importance of speech rehabilitation is paramount, highlighted by Hayes Martin's disparagement of the laryngectomy procedure for leaving patients voiceless.<sup>1</sup> As such, the evolution of voice restoration has paralleled the use of laryngectomy.

## HISTORICAL BACKGROUND

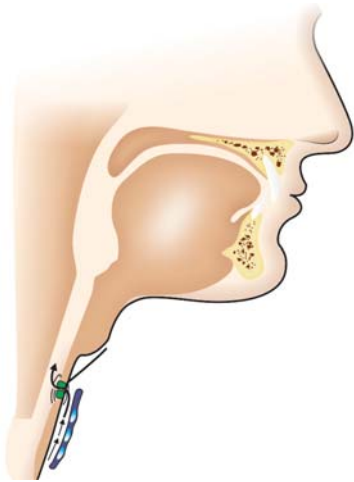
Gussenbauer described a fistula technique for voice rehabilitation accompanying his original description of Billroth's first laryngectomy.<sup>1</sup> A pharyngostoma managed secretions while an external device diverted air into the pharynx for voice production. Overtime, as surgeons eliminated the pharyngostome from standard laryngectomy procedure, alternative methods of voice production were needed and esophageal speech or the use of an external device became the primary options.<sup>2</sup> Multiple artificial instruments were then introduced, including both

mechanical and electric options, and many are still used today as a bridge prior to tracheoesophageal speech.

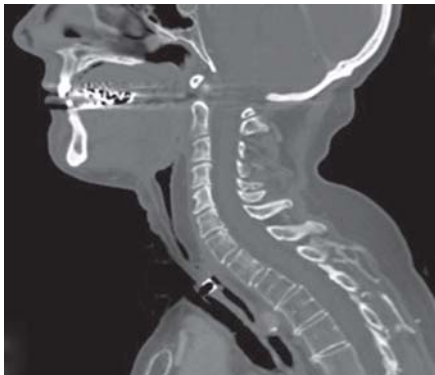
The development of esophageal speech may be attainable by some patients after laryngectomy. With this technique, air is swallowed into the cervical esophagus and then expelled, vibrating the patient's own pharyngoesophageal tissue forming a "pseudoglottis" which produces a functional, yet limited sound source for speech formation. Esophageal speech is difficult to learn, and despite extensive speech rehabilitation, only 26% of patients are able to use this in daily life.<sup>3</sup> Patients unable to attain esophageal speech were left with mechanical and electrical options.

Asia reintroduced voice restoration via fistula technique in 1965,<sup>1</sup> closely followed by Taub and Spiro with the "VoiceBak" as the first commercially available fistula prosthesis, but this technique also required a pharyngostoma.<sup>4</sup> Early prosthetic devices were expensive, cumbersome, of limited dependability, and the results were not widely reproducible. This led Singer and Blom<sup>5</sup> to develop a tracheoesophageal voice prosthesis and technique for surgical voice restoration that fulfilled the following key criteria:

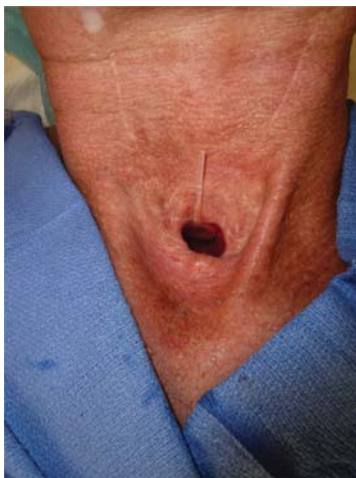- No compromise of oncologic goals
- Applicable in a radiated field
- No complex reconstruction (Applicable)
- Limited training for success
- Safety and rapid recovery
- No aspiration or alteration of swallowing



**Fig. 1A:** Anatomy and airflow schemata of a TEP prosthesis



**Fig. 1B:** CT Sagittal section showing prosthesis through party wall



**Fig. 1C:** Voice prosthesis in place

- Limited cost
- Superior speech production

A tracheoesophageal puncture (TEP) is made through the party wall, and a prosthesis is placed from the trachea

into the esophagus (Figs 1A to C). A one-way valve within the prosthesis limits aspiration of esophageal contents into the airway, while maintaining fistula patency to allow for diversion of pulmonary airflow through the pharynx for vocalization. Though the TEP technique and the available prostheses have undergone modifications overtime, the basic design and procedure has remained consistent. Thirty years after its inception, the TEP remains the mainstay of voice rehabilitation for patients undergoing total laryngectomy.

### PREOPERATIVE EVALUATION

Patients requiring total laryngectomy face significant emotional difficulty. Not only must they accept a possibly fatal cancer diagnosis, they must consent to a potentially difficult cure. Physicians and speech therapists help manage expectations and emotionally prepare patients for alaryngeal speech. As patients move through treatment, they will likely utilize many forms of speech rehabilitation, and discussing all options early helps alleviate the anxiety and manage expectations appropriately. While there are many options for communication including esophageal speech, writing, and artificial laryngeal devices, the high success rate of TEP moves clinicians to offer this as a first option for most (if not all) patients facing laryngectomy. Patients with a TEP report higher satisfaction rates with speech production and a higher overall quality of life over other methods of communication.<sup>6</sup>

Despite a thorough evaluation, ultimate success with a TEP remains difficult to predict based on preoperative measures. Factors, such as preoperative testing and a history of previous radiation have not been shown to be reliable preoperative predictors of success.<sup>7</sup> Some factors may steer a clinician away from recommending a TEP, such as dementia, and immobility of the upper limbs in which the patient will not be able to operate the device, or if caregivers will be unable to clean around the prosthesis. Barring these obvious hurdles, most patients will be counseled to undergo either a primary or secondary TEP.

### SURGICAL TECHNIQUES

Singer and Blom first introduced the tracheoesophageal puncture technique of voice restoration as procedure to be done secondarily after healing from the laryngectomy was complete. They subsequently expanded the technique to be done primarily at the time of laryngectomy. Both techniques are described.

## Secondary TEP

After laryngectomy, secondary surgical voice restoration should be delayed for 6 weeks to allow full healing of the stoma and surgical bed. If patients receive postoperative radiation therapy, secondary TEP may be further delayed until the skin and stoma have sufficiently recovered from radiation effects.

Preoperative assessment includes a barium swallow to evaluate for anatomical variations in the case of reconstructive efforts. Similar studies can assess for voice-limiting hypertonicity of the PE segment. Esophageal dilation may be performed prior to TEP if necessary.<sup>8</sup> Further testing with transnasal esophageal insufflation may offer further information regarding the tone of the pharyngeal constrictors.<sup>9</sup> With this technique, a catheter is placed into the esophagus transnasally and inflated with air to mimic pulmonary airflow across a TEP. Patients phonate and the relative quality of the voice is assessed. Fluent speech denotes optimal PE tone, while a breathy voice indicates low constrictor tone. Hypertonic PE constrictors cause effortful, intermittent speech, sometimes accompanied by gastric distension and burping. Complete spasm causes no voice production at all.

Secondary placement of a TEP is traditionally performed under general anesthesia per Singer and Blom's original description.<sup>5</sup> Esophagoscopy is performed, and esophageal dilation if indicated by barium swallow. The esophagoscope is placed bevel up at the level of the puncture site. A small incision is made into the esophagus, and a catheter placed into the fistula and guided into the distal esophagus. This stabilizes the puncture tract and allows it to mature until the prosthesis is placed 3-7 days after puncture.

For patients noted to have hypertonic or spastic PE constrictors on insufflation test, a pharyngeal myotomy may be performed through an open procedure, but had the significant potential risk of fistula formation. Recent experience demonstrated that selective Botulinum toxin (Botox) injections are very effective in breaking the cycle of PE spasm with minimal risk, and have essentially replaced the secondary myotomy procedure. Often, only one injection is needed to establish fluent tracheoesophageal speech.

Variations in technique, including the type of the esophagoscope, catheter, and use of the laser have been described.<sup>10,11</sup> Most recently, secondary TEP has been performed in the office setting with the aid of local anesthesia and transnasal esophagoscopy.<sup>12,13</sup> Supporters

cite the avoidance of general anesthesia and the improved ability to gauge prosthesis placement in an upright patient.

## Primary Transesophageal Puncture (TEP)

Drs. Maves, Lingerman, and Hamaker<sup>14,15</sup> were the first to establish primary TEP at the time of laryngectomy. There are no definitive disadvantages of primary TEP in terms of functional outcome or complication rates. In fact, primary TEP may be safer than secondary placement given the lack of additional anesthesia, and less risk of posterior esophageal perforation.<sup>16</sup>

Disruption of the common tracheoesophageal wall is an absolute contraindication to primary TEP placement. Abscess formation and mediastinitis may result from esophageal contents leaking around the puncture site. Patients undergoing a total laryngopharyngectomy with gastric pull-up, or in others with tracheoesophageal separation at the time of surgery, should be counseled for secondary TEP.

Hamaker describes five ordered steps for primary TEP: laryngectomy, stoma maturation, TEP, pharyngeal constrictor myotomy or pharyngeal plexus neurectomy, and buttressing of the tracheoesophageal wall.<sup>15</sup>

After laryngectomy, the stoma is matured. Stomal stenosis caused by contractions of the tracheoesophageal suture or skin flaps can be avoided by meticulous closure of the skin over the cartilage, preventing infection and resulting fibrosis. A deep stoma may preclude the use of hands-free speaking valves which require peristomal attachment. Releasing the sternal attachments of the sternocleidomastoid muscles results in a more favorable peristomal contour.

The TEP is made with a right-angled clamp and a scalpel. The clamp is placed into the esophagus through the laryngectomy defect and angled anteriorly. The party wall is incised over the clamp, and the tips of the instrument brought into the tracheal lumen. Traditionally, a catheter or nasogastric tube is passed through the TEP into the esophagus to serve as a placeholder in the TEP. Some authors prefer to place the prosthesis in the TEP intraoperatively, citing several advantages.

The cricopharyngeus, inferior and middle constrictors together make up the pharyngoesophageal (PE) sphincter. Pharyngoesophageal hypertonicity or spasm can limit airflow past the upper pharynx into the oral cavity, therefore precluding effective voice production. Clinically, this

manifests as intermittent effortful speech, or complete absence of speech. Hamaker describes a pharyngeal constrictor myotomy at the time of laryngectomy from the base of tongue to the cricopharyngeus.<sup>15</sup> The laryngectomy is then closed in the standard 3-layered fashion with the myotomy located posteriorly and the pharyngeal closure reinforced with a layer of intact muscle anteriorly. Singer, Blom and Hamaker subsequently introduced the pharyngeal plexus neurectomy to functionally eliminate PE spasm without muscle devascularization, theoretically reducing fistula formation.<sup>17</sup> To perform the plexus neurectomy after laryngectomy, the pharynx is rotated medially and the carotid artery retracted laterally to visualize the pharyngeal plexus entering the muscle at the level of the superior thyroid artery.<sup>18</sup> The nerve fibers may then be divided, and the constrictors used to reinforce the mucosal closure.

In a comparative study between patients who underwent myotomy alone, unilateral pharyngeal plexus neurectomy, or pharyngeal neurectomy with myotomy, patients in all three arms had equally successful voice production.<sup>19</sup>

Other variations on muscle closure techniques reported in the literature offer further insight into the delicate balance between providing enough mucosal coverage to prevent fistula formation, while disrupting the concentric ring to prevent PE spasm. In the nonmuscle closure technique, a two-layered closure of mucosa and submucosa results in the complete elimination of a concentric ring of muscle. Initially, there were no patients in either published study that demonstrated voice-limiting PE spasm, though the results demonstrated a slightly higher fistula rate of 9-10%<sup>20,21</sup> compared to 4% with traditional CP myotomy.<sup>17</sup> A later study was published reporting the development of PE spasm in one patient with nonmuscle closure.<sup>22</sup>

Incorporating a vascularized muscle closure while maintaining an interrupted constrictor ring, Deschler et al. introduced the half muscle closure technique.<sup>23</sup> After laryngectomy, the pharyngeal mucosa and submucosa are reapproximated. One half of the constrictors are closed over the midline providing a vascular bed to help minimize fistula. The contralateral constrictors are oversewn. Of the 23 patients, only one developed voice-limiting PE spasm. Only one patient developed a pharyngoesophageal fistula (4%) despite 22 patients having undergone preoperative radiation therapy. The authors conclude the half muscle closure to be a safe, reproducible operation which limits both fistula formation and voice-limiting PE spasm.

## POSTOPERATIVE REHABILITATION AND COMPLICATIONS

The efforts of speech pathologists are essential to successful voice restoration and they work intensely with patients to establish tracheoesophageal speech. In the immediate postoperative period, patients often communicate by writing tablets. Some may use an electrolarynx in the interim prior to TE speech initiation. After the discontinuation of a nasogastric catheter, TE speech is initiated. If the prosthesis was not placed in the operative suite, the catheter is removed and the fistula sized by the speech pathologist. The patient and speech pathologist decide together which type of prosthesis will be optimal.

Cessation of voice in a postlaryngectomy patient may represent a host of clinical scenarios, including stomal and esophageal stenosis, radiation fibrosis, and tumor recurrence. A complete history and physical may elucidate the most common causes of TEP failure and are reviewed below.

### Voice-Limiting Pharyngoesophageal Spasm

Despite aggressive diagnostic and surgical techniques to prevent hypertonicity, some patients have limited TE speech production due to excess tone in the PE constrictors after laryngectomy. Dilation of the constrictors with air perpetuates the problem and the patient is unable to expel the air into the oral cavity for vocalization. Traditionally, secondary pharyngeal constrictor myotomy has been used to correct postlaryngectomy spasm.<sup>24</sup> While effective in speech restoration, secondary PE constrictor myotomy is associated with an increased rate of fistula, likely due to further devascularization of the protective muscle layer over the mucosal closure.<sup>25</sup>

Injection of the PE constrictors with Botulinum toxin (Botox) provides an alternate solution for voice-limiting PE spasm. Diagnostic aides including insufflation testing and barium swallow can help identify the spasmodic segment. A trial lidocaine block identifies those patients who may benefit from Botox injection. Lidocaine is injected into the area of spasm, and restoration of speech implies a good prognosis for TE speech after Botox injection.<sup>26</sup> Videofluoroscopic techniques and EMG assistance have both been described to aid the practitioner in locating the exact anatomical location of the spasmodic segment for injection.<sup>27,28</sup> Though the effects of Botox are temporary, the lasting effects of PE relaxation may be seen for years,



precluding the need for further injections. Some postulate that the damaged nature of radiated surgical tissue inhibits further neuromuscular regeneration,<sup>29</sup> while some maintain that patients learn to voluntarily relax the segment of concern.<sup>26</sup>

### Prosthesis Migration and Leakage

Leakage of fluids through the prosthesis is the most common problem related to the prosthesis itself.<sup>30</sup> Fungal colonization of the valve mechanism is the most common cause of leakage, but can also be caused by an improperly fitting valve (Figs 2A and B).<sup>31</sup> Leakage of liquids around the prosthesis is most often indicative of a poorly healed TEP. Many patients have radiated necks, are hypothyroid, and have other factors associated with poor wound healing. Recurrent cancer is always a possibility and should be thoroughly evaluated.



**Fig. 2A:** Two types of indwelling prostheses



**Fig. 2B:** Fungal colonization on prosthesis  
(Courtesy: Glenn Bunting, 2010)

### SUMMARY

The development of alaryngeal speech has paralleled the development of the laryngectomy procedure. The establishment of the TEP and associated prostheses marked a turning point in the development of successful and dependable voice-rehabilitation. Though PE spasm, issues with stoma geometry, and prosthesis leakage can occur, patients should expect acceptable and functional voice restoration after laryngectomy.

### REFERENCES

- Holinger PH. Panel discussion: The historical development of laryngectomy. VA century of progress of laryngectomies in the northern hemisphere. *Laryngoscope* 1975;85:322-32.
- Singer MI. Tracheoesophageal speech: Vocal rehabilitation after total laryngectomy. *Laryngoscope* 1983;93:1454-65.
- Gates GA, Ryan W, Cooper JC (Jr), et al. Current status of laryngectomee rehabilitation: I. Results of therapy. *Am J Otolaryngol* 1982;3:1-7.
- Taub S, Spiro RH. Vocal rehabilitation of laryngectomees. Preliminary report of a new technic. *Am J Surg* 1972;124:87-90.
- Singer MI, Blom ED. An endoscopic technique for restoration of voice after laryngectomy. *Ann Otol Rhinol Laryngol* 1980;89:529-33.
- Clements KS, Rassekh CH, Seikaly H, et al. Communication after laryngectomy. An assessment of patient satisfaction. *Arch Otolaryngol Head Neck Surg* 1997;123:493-96.
- Lavertu P, Guay ME, Meeker SS, et al. Secondary tracheoesophageal puncture: Factors predictive of voice quality and prosthesis use. *Head Neck* 1996;18:393-98.
- Blom E, Hamaker RC. Tracheoesophageal voice restoration following total laryngectomy, in Myers E, JY S (Eds): *Cancer of the head and neck* (3rd ed). Philadelphia, Saunders, 1996; 839-52.
- Blom ED, Singer MI, Hamaker RC. An improved esophageal insufflation test. *Arch Otolaryngol* 1985;111:211-12.
- Shaw GY, Searl JP. Secondary tracheoesophageal puncture using a KTP laser. *Laryngoscope* 2000;110:1574-77.
- Cannon CR. Using an endotracheal tube in difficult secondary tracheoesophageal puncture: A novel technique. *Otolaryngol Head Neck Surg* 2001;125:117-19.
- LeBert B, McWhorter AJ, Kunduk M, et al. Secondary tracheoesophageal puncture with in-office transnasal esophagoscopy. *Arch Otolaryngol Head and Neck Surg* 2009;135:1190-94.
- Desyatnikova S, Caro JJ, Andersen PE, et al: Tracheoesophageal puncture in the office setting with local anesthesia. *Ann Otol Rhinol Laryngol* 2001;110:613-16.
- Maves MD, Lingeman RE. Primary vocal rehabilitation using the Blom-Singer and Panje voice prostheses. *Ann Otol Rhinol Laryngol* 1982;91:458-60.
- Hamaker RC, Singer MI, Blom ED, et al. Primary voice restoration at laryngectomy. *Arch Otolaryngol* 1985;111:182-86.

16. Karlen RG, Maisel RH. Does primary tracheoesophageal puncture reduce complications after laryngectomy and improve patient communication? *Am J Otolaryngol* 2001;22:324-28.
17. Singer MI, Blom ED, Hamaker RC. Pharyngeal plexus neurectomy for alaryngeal speech rehabilitation. *Laryngoscope* 1986;96:50-54.
18. Bayles SW, Deschler DG. Operative prevention and management of voice-limiting pharyngoesophageal spasm. *Otolaryngol Clin North Am* 2004;37:547-58.
19. Blom ED, Pauloski BR, Hamaker RC. Functional outcome after surgery for prevention of pharyngospasms in tracheoesophageal speakers. Part I: Speech characteristics. *Laryngoscope* 1995;105:1093-103.
20. Clevens RA, Esclamado RM, Hartshorn DO, et al. Voice rehabilitation after total laryngectomy and tracheoesophageal puncture using nonmuscle closure. *Ann Otol Rhinol Laryngol* 1993;102:792-96.
21. Olson NR, Callaway E. Nonclosure of pharyngeal muscle after laryngectomy. *Ann Otol Rhinol Laryngol* 1990;99:507-08.
22. Terrell JE, Lewin JS, Esclamado R. Botulinum toxin injection for postlaryngectomy tracheoesophageal speech failure. *Otolaryngol Head Neck Surg* 1995;113:788-91.
23. Deschler DG, Doherty ET, Reed CG, et al. Prevention of pharyngoesophageal spasm after laryngectomy with a half-muscle closure technique. *Ann Otol Rhinol Laryngol* 2000;109:514-28.
24. Singer MI, Blom ED. Selective myotomy for voice restoration after total laryngectomy. *Arch Otolaryngol* 1981;107:670-73.
25. Baugh RF, Baker SR, Lewin JS. Surgical treatment of pharyngoesophageal spasm. *Laryngoscope* 1988;98:1124-26.
26. Chao SS, Graham SM, Hoffman HT. Management of pharyngoesophageal spasm with Botox. *Otolaryngol Clin North Am* 2004;37:559-66.
27. Hoffman HT, Fischer H, VanDenmark D, et al. Botulinum neurotoxin injection after total laryngectomy. *Head Neck* 1997;19:92-97.
28. Hamaker RC, Blom ED. Botulinum neurotoxin for pharyngeal constrictor muscle spasm in tracheoesophageal voice restoration. *Laryngoscope* 2003;113:1479-82.
29. Lewin JS, Bishop-Leone JK, Forman AD, et al. Further experience with Botox injection for tracheoesophageal speech failure. *Head and Neck* 2001;23:456-60.
30. Op de Coul BM, Hilgers FJ, Balm AJ, et al. A decade of postlaryngectomy vocal rehabilitation in 318 patients: A single Institution's experience with consistent application of provox indwelling voice prostheses. *Arch Otolaryngol Head Neck Surg* 2000;126:1320-28.
31. Hilgers FJ, Ackerstaff AH, Balm AJ, et al. A new problem-solving indwelling voice prosthesis, eliminating the need for frequent Candida- and "underpressure"-related replacements: Provox ActiValve. *Acta Otolaryngol* 2003;123:972-79.