

Allergic Fungal Rhinosinusitis

¹Vicky S Khattar, ²Bachi T Hathiram

¹Assistant Professor, Department of ENT and Head and Neck Surgery, TN Medical College and BYL Nair Charitable Hospital Mumbai, Maharashtra, India

²Professor and Head, Department of ENT and Head and Neck Surgery, TN Medical College and BYL Nair Charitable Hospital Mumbai, Maharashtra, India

Correspondence: Vicky S Khattar, Assistant Professor, Department of ENT and Head and Neck Surgery, TN Medical College and BYL Nair Charitable Hospital, C-7, Swati, Kalyan Complex, Panchmarg, Versova, Mumbai-400061, Maharashtra, India

Abstract

Allergic fungal rhinosinusitis (AFRS) is one of the more commonly encountered forms of noninvasive fungal rhinosinusitis, seen in immunocompetent individuals. It is caused by a Gell and Coombs Type I, IgE mediated (and possibly Type III) hypersensitivity reaction to an extramucosal fungal antigen. It bears striking similarities to Allergic Broncho Pulmonary Aspergillosis (ABPA), in terms of pathogenesis as well as treatment. It commonly presents as nasal polyposis. Most current treatment protocols for this condition are based on a combined medical and surgical approach. In this article we have recapitulated the history, epidemiology, etiology, clinical features, diagnostic investigations and treatment protocols for this disease.

Keywords: Nasal polyps, hypersensitivity, sinusitis, Aspergillosis, steroids, itraconazole.

Allergic fungal rhinosinusitis (AFRS) has been reported worldwide with an incidence of 5 to 10% of all cases of chronic rhinosinusitis requiring surgery.² It represents an allergic/hypersensitivity disorder. Although anecdotal, there have been numerous suggestions in literature, linking an upper airway hyper-reactivity and chronic rhinosinusitis. Due to its pathophysiological similarities with allergic bronchopulmonary aspergillosis (ABPA), AFRS probably forms one such link.

HISTORY

It was first reported as allergic aspergillosis of the paranasal sinuses by Millar et al in 1981.¹ In 1983, Katzenstein et al termed the condition Allergic Aspergillus Sinusitis, although fungal cultures had not been obtained.² In the same year, DeJuan et al described the same condition in children, and termed it Allergic Periorbital Mucopyocele.³ However, now the accepted name for this condition is Allergic Fungal Rhinosinusitis or Allergic Fungal Sinusitis.⁴⁻⁶

PATHOPHYSIOLOGY

AFS is one of the two nontissue-invasive fungal sinusitis along with fungal balls. It is similar to Allergic Bronchopulmonary Aspergillosis which is postulated to Type I and Type III hypersensitivity reaction to fungal antigen. However, in AFRS, it is mainly Type I hypersensitivity which

has been postulated in its pathophysiology (Type III reaction is doubtful, since immune complexes have not been demonstrated). According to the theory developed by the team at UT South-Western,⁸⁻¹⁰ fungi enter the nose and sinuses, triggering Type I and III responses; this inflammation results in: production of allergic mucin, stasis of secretions and obstruction of sinus ostia. The trapped fungi continue to stimulate the immune system, and the cycle repeats itself. Over time, massive polyposis develops, and fungal mucocoeles distort the sinonasal anatomy.¹¹ This theory finds several lines of support; however, the findings from the series of Ponikau et al (1999) question this theory.¹² From their observations, they concluded that Type I hypersensitivity is not important in the pathophysiology of AFRS, and should not be a diagnostic criterion. They proposed the alternative term eosinophilic fungal sinusitis to describe this disease.¹²

Members of the dematiaceous family are most commonly implicated, i.e. *Bipolaris spicifera*, *Drechslera*, *Alternaria*, *Curvularia*, *Excerohilum*, *Rhizopus*, *Fusarium* and *Chrysosporium*. These fungi were thought to be non-cross-reactive, but recently an 18-kD protein has been isolated, which has been proposed to be a 'fungal pan allergen'.²⁴

The disease is extramucosal, however, secondary bacterial infection may supervene, simulating an acute exacerbation of underlying chronic sinus disease.

The natural course of AFRS is characterized by frequent recurrences, irrespective of the treatment modality. Kupferberg et al (1997) noted universal recurrence in the absence of vigorous postoperative medical treatment, and they noted, that even with medical treatment, recurrence was common.¹³ The overall recurrence rates varied from 10 to 100%.¹¹

AFRS is known to have a predilection for involving the orbit and the skull base (Fig. 1).¹⁵⁻¹⁹

The hallmark of AFRS is the allergic mucin. Allergic mucin can be described as a thick and tenacious secretion, the color ranging from tan to green, brown or black, which on H and E staining reveals eosinophils, Charcot Leyden crystals, and possibly fungal hyphae which can be seen after staining with Gomori Methanamine Silver stain. The Fontana Masson stain specifically stains melanin, which is characteristic of dematiaceous fungi, and thus helps to differentiate it from septate fungi. The mucin tends to become more tenacious and scanty after treatment with steroids.

This mucin is essentially a proinflammatory mass of pyknotic eosinophils and their components, including their degranulation products which include the major basic protein (MBP).²⁵ This MBP is a known proinflammatory and mucosal epithelial cell-toxic molecule, which plays an important role in asthma.²⁶ Also, an 18-kD IgE fungal allergen has been identified within the mucin, which has been postulated to be a fungal pan-allergen, which besides being recognized by the patient's serum, also reacts with many different commercial mold preparations.²⁴

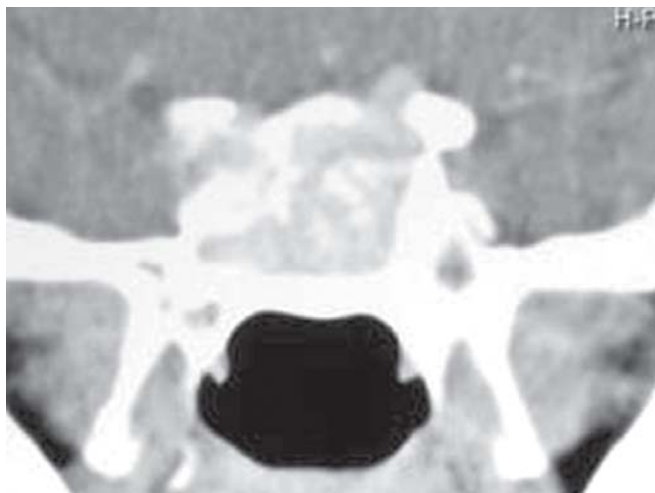


FIGURE 1: Coronal CT – PNS showing erosion of the roof of the left, and lateral wall of the right sphenoid sinus, in a case of bilateral AFRS

Besides the mucin, one encounters fungal debris, which fills most of the sinuses, and needs to be meticulously evacuated during surgery.

EOSINOPHILIC MUCIN RHINOSINUSITIS (EMRS)

Sometimes, this mucin is also encountered in patients with rhinosinusitis, with their clinical profile very similar to that of AFRS, but without actual AFRS. This mucin is negative for fungal hyphae on histopathology with negative fungal cultures. They may also show the characteristic hyperattenuating shadows on CT as in AFRS.^{21,22} Some of them may not be atopic, but may have NSAID hypersensitivity. This entity has been termed as eosinophilic mucin rhinosinusitis (EMRS) by Ferguson (2000). The disease is usually bilateral (in about 93% cases), and patients of EMRS have a greater incidence of coexistent asthma than seen with AFRS, besides also having a lower serum IgE level as compared to the latter.

IMMUNOLOGICAL BASIS

While ABPA involves Type I and Type III hypersensitivity, there is however, a controversy as to whether Type III really plays a role in the pathogenesis of AFRS.

Those suffering from AFRS have an elevated total serum IgE, which ranges anywhere between normal to 3000 IU/ml, and waxes and wanes in proportion to the disease exacerbations; it may thus be used as a prognostic tool, just as in ABPA.²³ The hypersensitivity response in AFRS, to the etiologic fungus is less robust as compared to that seen in ABPA; this can probably be explained by the fact that, due to the smaller sinonasal surface area available for contact sensitization and immune-reactivity as compared to that of the lungs in ABPA, the response is less.²⁴

EPIDEMIOLOGY

AFRS is the most common form of fungal rhinosinusitis.⁷ AFRS is usually seen in the 3rd to 5th decade of life. Since fungi thrive in warm and humid climates, AFRS is commonly seen more in tropical climates such as that seen in India. It is seen in atopic individuals with a normal immune system. Younger children present in a similar fashion as adults. Asthma is seen to be associated in 33-50% patients, and many of these have aspirin hypersensitivity. About 60% AFRS patients will give a history of allergic rhinitis, but of those who undergo allergy testing, 70-90% show evidence of atopy.^{20,8}

Erythrocyte sedimentation rate is normal unless there is a super added bacterial infection. Due to the inherent nature of the disease, recurrences are invariably common.

DIAGNOSIS

Symptoms

- History of nasal polyposis (incidence is nearly 100%)
- History of previous surgery (indicating recurrence)
- Patient may have documented atopy
- Proptosis is common in children with AFRS
- hypertelorism due to expansion of bony labyrinth
- 75% patients have history of expelling dark colored rubbery nasal casts
- These symptoms are besides those which may be seen in any sinonasal inflammatory pathology.

Bent and Kuhn's diagnostic criteria (1994): In 1994, they proposed major as well as minor diagnostic criteria; the major criteria include:

- Type I hypersensitivity
- Nasal polyps
- Characteristic CT scan findings
- Positive fungal stain or culture
- Allergic mucin with fungal elements and no tissue invasion.

The minor criteria although not pathognomonic of the disease, are indicative.

IMAGING

CT Findings

Findings are similar for AFRS as well as EMRS. Approximately half the cases (51% as studied by Mukherji et al, 1998) occur unilaterally, and many others show asymmetric involvement (78% as studied by Mukherji et al, 1998) by the disease on the two sides. There is expansion of the involved sinuses with corresponding reduction in the space of the surrounding compartments such as the orbit (Fig. 2), which may be accompanied by remodelling (Fig. 2) or attenuation of the bony margins within the periphery of the lesion. Several studies have quoted the incidence of bony erosion with spread of pathology into the adjacent anatomic areas as 20% (Mukherji et al, 1998, Nussenbaum et al, 2001). Whether this erosive effect represents a direct manifestation of the progression of the disease, or a different pathological entity within AFRS, has yet to be proven (Oyarzabal and Chevretton, 2000).

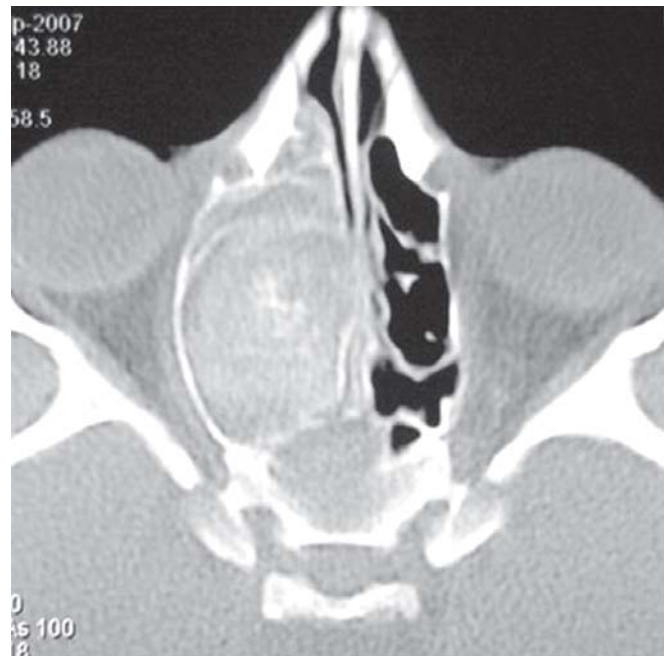


FIGURE 2: Axial CT – PNS showing expansion of the right sinonasal compartment with corresponding compromise of the right orbital volume, with remodelling of the right lamina papyracea, as compared to the left side, in a case with right sided AFRS

AFRS is primarily caused by dematiaceous fungi. The allergic mucin seen in such cases contains the maximum load of the fungal elements, which are known to have a great affinity for calcium, manganese, magnesium and other ferromagnetic substances. This is seen more so in cases which have not been treated with steroids. Since this mucin is interspersed with fungal debris, concretions and polypoid mucosa, the unenhanced CT scan shows a characteristic heterogeneity of signal within the involved sinus, which has been given many names such as the 'starry-sky', 'ground-glass' or 'serpiginous' patterns, but commonly referred to as the 'double-density' sign, which by far, describes this typical radiologic appearance the best (Fig. 3). This is best appreciated in the soft tissue windows.²⁴ However, this 'double density' sign may also be seen with other forms of fungal sinusitis, and is usually caused by the dense inspissated eosinophil-rich extramucosal allergic mucin, which although found virtually in all cases of AFRS during surgery, may also be seen in nonfungal hypertrophic sinus disease, such as the ASA triad (Samter's syndrome). Thus, according to Schubert (2004), the hyperattenuating signal on CT in AFS may be caused by both the presence of inspissated allergic mucin, and the fungal hyphae within it. Following steroid therapy, an initial complete 'white-out' appearance on CT scan (Fig. 4) changes to one with a

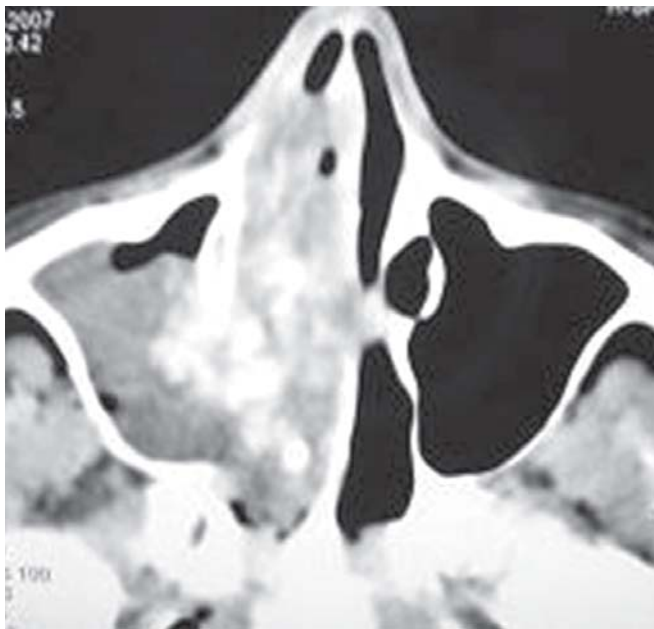

FIGURE 3: Axial CT – PNS showing the characteristic 'double-density' sign, in a patient with right sided AFRS

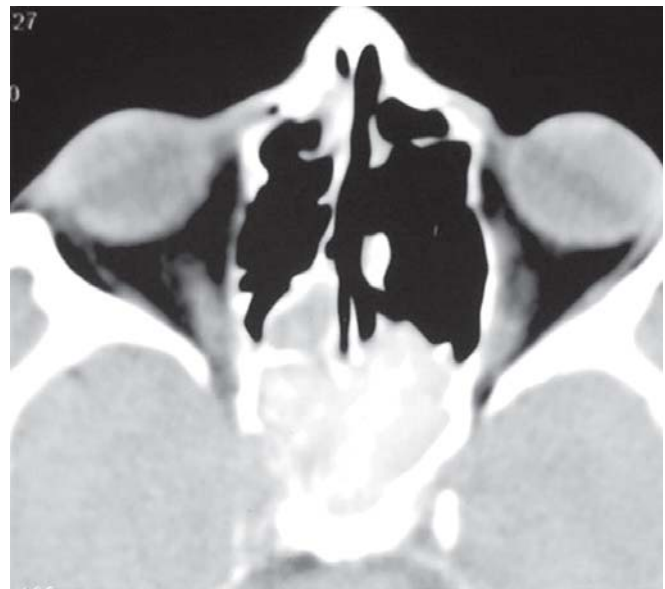

FIGURE 5: Preoperative, poststeroid axial CT – PNS of the same patient (Fig. 4) showing a dramatic reduction in the bulk of disease

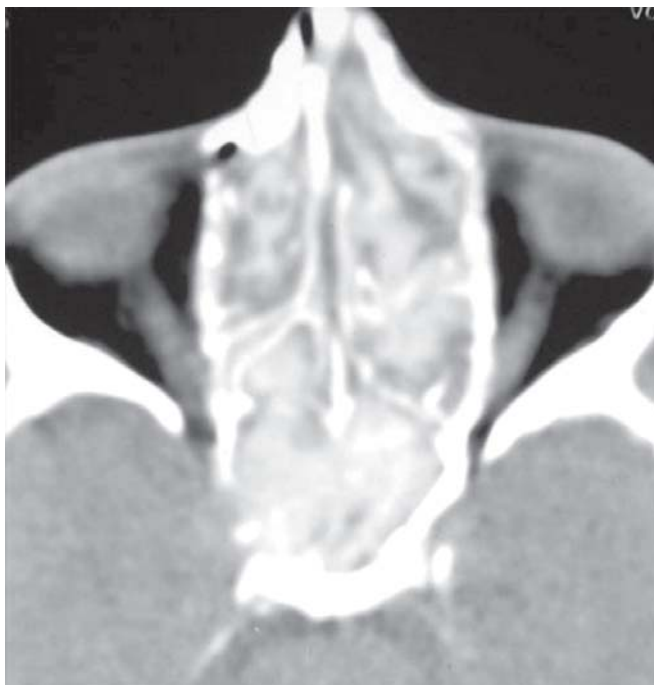

FIGURE 4: Preoperative, presteroid axial CT – PNS showing a complete 'white-out' appearance, with involvement of both sides sinonasal compartments

decreased disease load (Fig. 5), leaving behind the medically irreversible changes which would warrant surgical intervention; it also allows for better denotation of bony landmarks, and helps in surgical road-mapping, besides the added advantage of reducing intraoperative bleeding. Thus

it would not be unadvisable to say, that CT scans may be repeated after the preoperative steroid therapy, which in all probability would help in planning for a favorable surgical outcome.

MR Findings

The characteristic appearance is a iso or hypoattenuated signal on T1 weighted images, and a signal void on T2 weighted images in AFRS. The high protein and low water concentration of allergic fungal mucin, coupled with the high water content within the surrounding edematous paranasal sinus mucosa, gives rise to the characteristic MR findings in AFRS, with this effect being more pronounced in the T2 images, due to a prolonged magnetic field relaxation time (Marple 2006). The signal void on T2 images may mimic aeration (Bransetter and Weissman 2005). The surrounding inflamed polyps and mucosa are hyperintense on both T1 and T2 (Manning et al, 1997). MRI also helps in confirming the noninvasion of the dura and periorbita, which is typical of this disease. This may be correlated with the CT scan for better delineation of the disease.

INVESTIGATIONS

1. Total eosinophil count–this may or may not be raised.
2. Erythrocyte sedimentation rate–may not be raised, except in superadded bacterial sinus infection.

3. Total serum IgE – usually elevated, often ranging upto 5000 IU/ml or more, averaging 600 IU/ml, sometimes this may also be normal (Schubert, 2000).³⁰
4. Antigen specific IgE, for both fungal and other inhalants, by *in vitro* testing and/or skin tests.
5. Precipitating antibodies (if available, however only for investigational purposes).
6. Microscopic evaluation of mucin evacuated intraoperatively.
7. Fungal culture of mucin evacuated intraoperatively.

PREOPERATIVE PREPARATION IS ESSENTIAL

- Although most literature stresses on the role of post-operative management, the role of preoperative preparation cannot be foregone. If there are sufficient reasons to strongly suspect AFRS preoperatively (after the required radiologic, biochemical, microbiologic and endoscopic investigations), then systemic steroids may be given preoperatively, which may be in the form of oral prednisolone, in a dose of 0.5 to 1.0 mg /kg/day, seven days prior to surgery, which helps in reducing polyps and mucosal edema and helps identify surgical landmarks better (however, allergic mucin disappears, but fungal debris persists, sometimes diverting the surgeon to a diagnosis of fungal balls) (Figs 4 and 5). The CT scan may be repeated after steroid therapy, prior to surgery, especially in cases where the disease has spread beyond the sinonasal compartment. In such extensive pathology, the risks of exposure to 'added' radiation far outweigh the advantages obtained from a repeat scan.
- Concomitant antibiotics are administered to counteract super- added bacterial infection which is present in most of the cases.
- Nasal decongestants are started a week prior to surgery.

SURGICAL MANAGEMENT

The key to surgical management is the complete removal of all allergic mucin, polyps and fungal debris to decrease the antigenic load. Meticulous irrigation may be employed to flush out all the debris after the sinuses have been opened by widening their ostia. Recidivism of the mucin/debris has been postulated as one of the causes of recurrence. The principle of mucosal preservation should be followed, since the disease by nature is purely extramucosal it also helps in better healing with a reduced risk of postoperative adhesion

formation. However, proponents of certain surgical techniques claim that limited functional endoscopic sinus surgery is associated with a higher rate of AFRS recurrence than more aggressive surgical procedures that remove all dysfunctional obstructive hypertrophic/hyperplastic sinus mucosa as well as all inspissated allergic mucin.³⁰ The polyps and fungal debris serve as helpful surgical markers. In fact, AFRS has been likened to cholesteatoma of the ear, in that it widens the pathways which it takes, and the same must be followed in order to evacuate it. In fact, many cases which have been earlier labeled as 'rhinitis caseosa' or 'nasal cholesteatoma' may have in all probability been cases of AFRS. The final goal of surgery is to provide adequate ventilation and drainage to all the sinuses. All evacuated material should be sent for fungal and bacterial culture, fungal KOH mounts, and histopathology for special stains.

Kupferberg (1997) has devised a system of staging, wherein postoperative sinus cavities can be staged, and decisions regarding further medical or surgical management may be instated.

- *Stage 0*: No mucosal edema or allergic mucin (Fig. 6).
- *Stage 1*: Mucosal edema with/without allergic mucin (Fig. 7).
- *Stage 2*: Polypoidal mucosa with/without allergic mucin (Fig. 8).
- *Stage 3*: Sinus polyps with fungal debris and allergic mucin (Fig. 9).

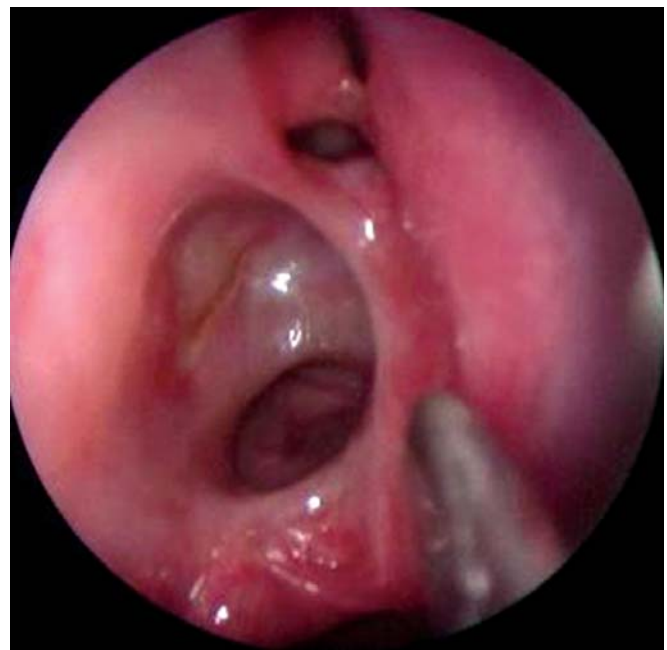

FIGURE 6: Kupferberg's stage 0 – no mucosal edema or mucin

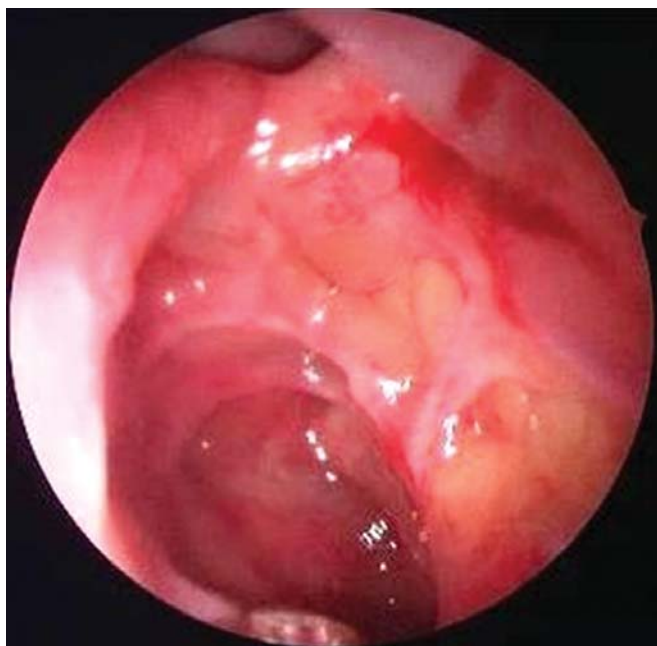

FIGURE 7: Kupferberg's stage 1 – edematous mucosa

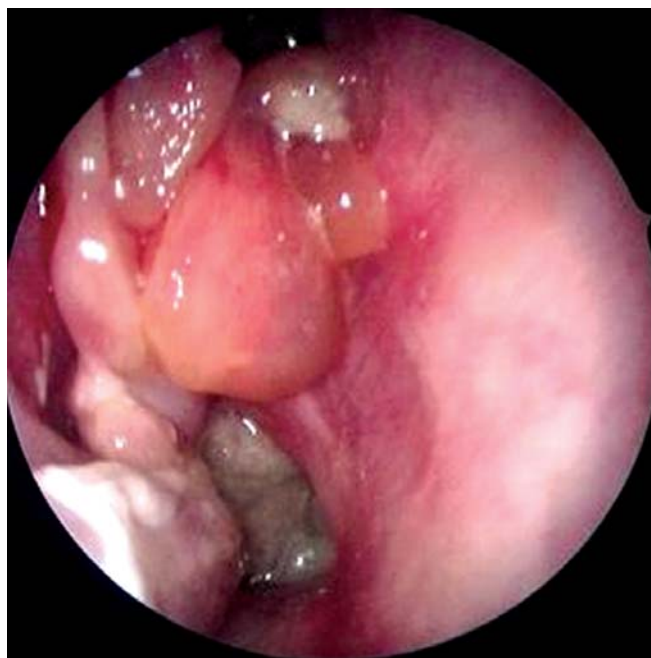

FIGURE 9: Kupferberg's stage 3 – frank polyps with allergic mucin

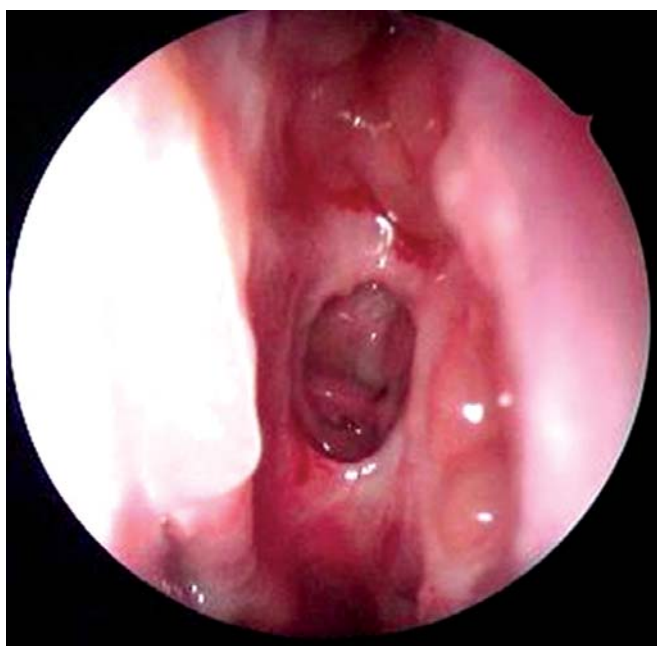


FIGURE 8: Kupferberg's stage 2 – polypoid mucosa

Stages 0 to 2 may respond to conservative management; Stage 3 usually requires surgery.

Often, the postoperative status may be 'down-staged', by administering short courses of steroids, and many times, revision surgery may be prevented.

COMPLICATIONS

Besides all the potential complications of sinus surgery, there is an added risk of damage to exposed structures such as

the dura and orbit, since often the disease abuts against these structures, without actually invading them. There is also an increased risk of encephalocele in cases of dural exposure which is however, reported rarely.

POSTOPERATIVE MANAGEMENT

The postoperative care plays an equally important role in contributing towards a good surgical result. Antibiotics are continued for a period of ten days. The patient is taught to self-administer saline nasal washes, once the sinus packs are removed. The patients are followed up at weekly intervals for the first four weeks following surgery and every 6 weeks thereafter, and subsequently three monthly for the next year. The nasal cavities are cleaned under endoscopic guidance to clear all crusts, secretions and break adhesions if any. *The aim should be to achieve and maintain a mucosal lined, well-ventilated cavity.* Various studies show that even years after initial treatment, a significant number of patients continue to evidence objective signs of inflammatory sinus disease, indicating clearly that the chronic and recurring nature of AFRS warrants extended follow-up (Marple et al 2002).

The role of postoperative medical management cannot be stressed more. In fact, surgery for AFRS without postoperative medical management leads to recurrence rates of up to 100%.^{13,27}

This may be local and systemic: topically, steroid sprays may be used for a minimum period of six months, and gradually tapered off, keeping room for stepping up the dose during an acute exacerbation of this recurrent pathology. Owing to the extramucosal nature of the disease, amphotericin B washes may also be given, which can take care of the luminal load of the fungus; there is not adequate evidence in literature however, to validate this therapy for AFRS.

Oral prednisolone can be started in a dose of 0.5 mg/kg as a single dose, and may then be tapered off, starting two weeks afterwards, and given for a minimum period of three to six months, with a low maintenance dose being given for even longer periods. Acute exacerbations of symptoms during treatment may be managed with a short step-up of the dose to tide over the crisis, followed by continuation of the earlier maintenance phase afterwards.

There has been an increased interest in the use of oral itraconazole in a dose of 200 mg twice daily, for variable periods ranging from three weeks to six months post-operatively, probably due to added its anti-inflammatory effect. Studies for ABPA have found an additional clinical benefit from the use of itraconazole, when compared to a placebo.^{28,29} Due to the similarity in the pathogenesis of ABPA and AFRS, this may be worth a thought. Principally however, this appears to be of no use, since AFRS has been defined on the basis of its extramucosal nature; nevertheless the added clinical benefit obtained in ABPA surely asks for further investigation in this field.

IMMUNOTHERAPY

- The use of immunotherapy, leads to a decreased amount of crusting and polyposis, and reduces the need for systemic and topical corticosteroids.
- Its role has been thought to be controversial, since Type III hypersensitivity plays a role in pathogenesis, and administering antigens would result in the potential formation of immune-complexes leading to an Arthus reaction, which has been seen in ABPA due to *Aspergillus fumigatus*; however, such reactions were not seen in AFRS caused by *Bipolaris spicifera*. In fact, studies on AFRS have proved that immunotherapy besides proving to be safe, also produced clinical improvements.^{16,3}
- Also seen is a decrease in the rate of reoperations.³⁰
- The long-term benefits are however unknown.

- The basic protocol includes an initial testing for allergy, which may usually be done prior to, or even after surgery. The therapy is started 4 to 6 weeks after surgery has confirmed complete removal of disease; in recurrent cases, revision surgery should be done prior to starting the therapy. The patient is tested for fungal as well as nonfungal antigens, and all positive reactors are prepared in two vials, one each for fungal and nonfungal antigens. Weekly injections are given from each vial in separate arms, with gradual stepping up of doses till the maximum tolerated level is reached. This is continued for a year, after which the injections are tapered over the next two years.³²

CONCLUSION

AFRS is an obstinate, immunologically mediated non-invasive fungal inflammation, with a marked propensity for recurrence. Unlike in other fungal infections of the body, with the exception of ABPA (to which it has been likened), steroids form an important part of therapy, along with surgery. Many a times, despite the best efforts, recurrences have been reported. The answer probably lies in a combination modality treatment protocol, which includes immunotherapy.

REFERENCES

1. Millar JW, Johnston A, Lamb D. Allergic Aspergillosis of the paranasal sinuses. *Thorax* 1981;36:710.
2. Katzenstein AA, Sale SR, Greenburger PA. Allergic Aspergillus Sinusitis: A newly recognized form of sinusitis. *J Allergy Clin Immunol* 1983;72:89-93.
3. DeJuan E, Green WR, Iliff NT. Allergic Periorbital Mucopyocele in children. *Am J Ophthalmol* 1983;96:299-303.
4. Bent JP III, Kuhn FA. Diagnosis of Allergic Fungal Sinusitis. *Otolaryngol Head Neck Surg* 1994;111:580-88.
5. DeShazo RD, Chapin K, Swain RE. Fungal Sinusitis. *N Engl J Med* 1997;337:254-59.
6. Robson JM, Hogan PG, Ben RA, et al. Allergic Fungal Sinusitis presenting as a paranasal sinus tumour. *Aust NZ J Med* 1989;19:351-53.
7. Ence BK, Gourley DS, Jorgensen NL, et al. Allergic fungal sinusitis. *Am J Rhinol* 1990;4:169-78.
8. Manning SC, Hollman M. Further evidence for allergic pathophysiology in Allergic Fungal Sinusitis. *Laryngoscope* 1998;108:1485-96.
9. Manning SC, Mabry RL, Schaefer SD, et al. Evidence of IgE mediated hypersensitivity in Allergic Fungal Sinusitis. *Laryngoscope* 1993;103:717-21.
10. Manning SC, Schaefer SD, Close LG, et al. Culture positive Allergic Fungal Sinusitis. *Arch Otolaryngol Head Neck Surg* 1991;117:174-78.

11. Marple BF. Allergic Fungal Rhinosinusitis: Current theories and management strategies. *Laryngoscope* 2001;111:1006-19.
12. Ponikau JU, Sherris DA, Kern EB, et al. The diagnosis and incidence of Allergic Fungal Sinusitis. *Mayo Clin Proc* 1999;74:877-84.
13. Kupferberg SB, Bent JP III, Kuhn FA. Prognosis for Allergic Fungal Sinusitis. *Otolaryngol Head Neck Surg* 1997;117:35-41.
14. Marple B, Newcomer M, Schwade N, et al. Natural history of Allergic Fungal Rhinosinusitis: A four to ten year follow-up. *Otolaryngol Head Neck Surg* 2002;127:361-66.
15. Cody DT, Neel HB, Ferreiro JA, Roberts GD. Allergic fungal sinusitis: The Mayo Clinic experience. *Laryngoscope* 1994;104:1074-1979.
16. Goldstein MF, Dunsky EH, Dvorin DJ, Lesser RW. Allergic Fungal sinusitis: A review with four illustrated cases. *Am J Rhinol* 1994;8:13-18.
17. Aviv JE, Lawson W, Bottone EJ, Sachdev VP, Som PM, Biller HF: Multiple intracranial mucocoeles associated with phaeoophomycosis of the paranasal sinuses. *Arch Otolaryngol Head Neck Surg* 1990;116:1210-13.
18. Bent JP, Kuhn FA: Diagnosis of allergic fungal sinusitis. *Otolaryngol Head Neck Surg* 1994;111:580-88.
19. Lydiatt WM, Sobba-Higley A, Huerter JV, Liebroch LG: Allergic fungal sinusitis with intracranial extension and frontal lobe symptoms: A case report. *ENT Journal* 1994;73:402-04.
20. deShazo RD, Swain RE: Diagnostic criteria for allergic fungal sinusitis. *J Allergy Clin Immunol* 1995;96:24-35.
21. Ferguson BJ. Eosinophilic Mucin Rhinosinusitis: A distinct clinicopathological entity. *Laryngoscope* 2000;110:799-813.
22. Schubert MS. Fungal Rhinosinusitis: Diagnosis and therapy. *Curr Allergy Asthma Rep* 2001;1:268-76.
23. Sanchez-Segura A, Brevia JA, Rodriguez C. T lymphocytes that infiltrate nasal polyps have a specialised phenotype and produce a mixed TH1/TH2 pattern of cytokines. *J Allergy Clin Immunol* 1998;102:953-60.
24. Schubert MS. Allergic Fungal Sinusitis. *Otolaryngol Clin N Am* 2004;37:301-26.
25. Khan DA, Cody TC III, George TJ, et al. Allergic Fungal Sinusitis: An immunohistologic analysis. *J Allergy Clin Immunol* 2000;106:1096-101.
26. Gleich GJ, Adolphson CA, Leiferman KM. Eosinophils. In: Gallin JI, Goldstein IM, Snyderman R, editors. *Inflammation: basic principles and clinical correlates*. New York: Raven Press; 1992;663-700.
27. Kuhn FA, Javer AR. Allergic Fungal Sinusitis: A four year follow-up. *Am J Rhinol* 2000;14:149-56.
28. Stevens DA, Schwartz HJ, Lee JY, et al. A randomised trial of itraconazole in allergic bronchopulmonary Aspergillosis. *N Engl J Med* 2000;342:756-62.
29. Wark PABW, Hensley MJ, Saltos N, et al. Anti-inflammatory effect of itraconazole in stable bronchopulmonary Aspergillosis: A randomised controlled trial. *J Allergy Clin Immunol* 2003;111:952-57.
30. Schubert MS, Goetz DW. Evaluation and treatment of allergic fungal sinusitis. II. Treatment and follow-up. *J Allergy Clin Immunol* 1998;102:395-402.
31. Quinn J, Wickern G, Whisman B, et al. Immunotherapy in allergic Bipolaris sinusitis: A case report [abstract]. *J Allergy Clin Immunol* 1995;95:201.
32. Mabry RL, Marple BF, Mabry CS: Outcomes after discontinuing immunotherapy for allergic fungal sinusitis. *Otolaryngol Head Neck Surg* 2000;122:104-07.