

Saprophytic Mycotic Infections of the Nose and Paranasal Sinuses

Mohan Kameswaran, S Raghunandhan

Consultant ENT Surgeons, Madras ENT Research Foundation, Chennai, Tamil Nadu, India

Abstract

The kingdom of fungi is ubiquitous and omnipresent, having prevailed over the tides of time, over numerous decades by adapting to various methods of survival in the susceptible host including humans. Saprophytic fungi derive nutrition from dead and decaying organic matter, with the capacity to flare up in virulence, provided the right opportunity especially when the host immunity is compromised (as in prolonged steroid therapy, diabetes, HIV infection, tissue transplant recipients) or if there is a breach in a vital barrier permitting deeper tissue penetration (postsurgical or post-traumatic). Hence, knowledge about the saprophytic fungal elements dwelling within the nose and paranasal sinuses is paramount for Otolaryngologists worldwide, in order to accurately diagnose and efficiently manage such intriguing cases. This article provides a broad overview of the various opportunistic fungi in rhinology, and highlights the principles of diagnosis and protocols in management.

Keywords: Saprophytes, mycosis, mucor, immunocompromised state, allergic fungal sinusitis, invasive fungal sinusitis, antifungal therapy.

INTRODUCTION

Living organisms are divided up among no fewer than five kingdoms, one of which is the kingdom of fungi. Fungi are a diverse group of eukaryotic organisms, found throughout nature, that obtain their nourishment from living or dead organic matter. The classification and identification of fungi is based on their appearance, rather than on their nutritional and biochemical differences, that are of such importance in the classification of bacteriae. In general numerous fungi of medical importance can co-exist in a mycelial or as a yeast form and thrive as an indolent saprophyte or turn into a virulent invasive pathogen, depending on the host and environmental conditions.

CLASSIFICATION OF MYCOSES

The clinical nomenclatures used for the mycoses are based on the (1) site of the infection, (2) route of acquisition of the pathogen and (3) type of virulence exhibited by the fungus.

Classification Based on Site

Mycoses are classified as superficial, cutaneous, subcutaneous, or systemic (deep) infections depending on the type and degree of tissue involvement and the host response to the pathogen.

Classification Based on Route of Acquisition

Infecting fungi may be either exogenous or endogeneous. Routes of entry for exogeneous fungi include airborne, cutaneous or percutaneous. Endogenous infection involves colonization by a member of the normal flora or reactivation of a previous infection.

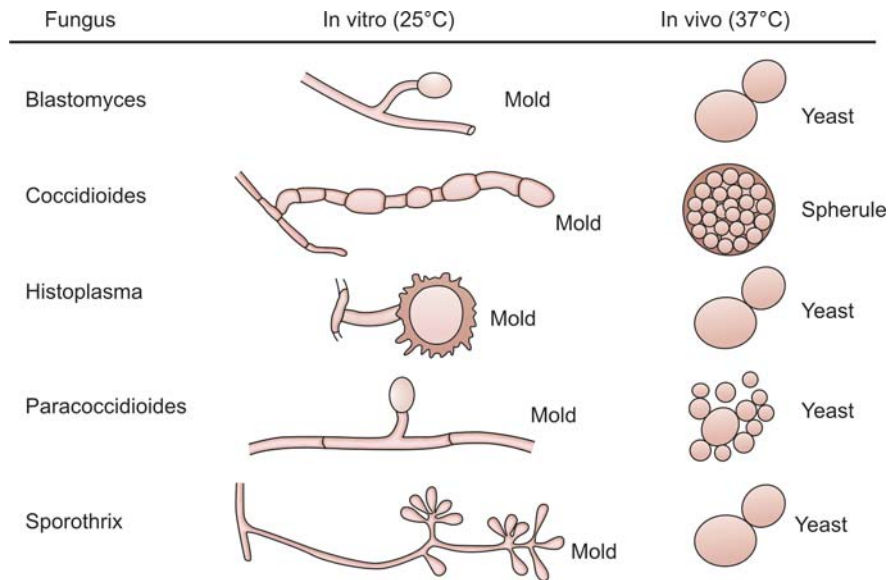
Classification Based on Virulence

Primary pathogens can establish infections in normal hosts. Opportunistic pathogens cause disease in individuals with compromised host defense mechanisms.

<i>Host defence</i>	<i>Immuno-compromised</i>	← <i>Immuno-competent</i>	<i>Atopic</i>
Fungal form	Invasive	Granulomatous Saprophytic Fungal ball	AFRS

SAPROPHYTIC INFECTIONS

Saprophytes refer to “*Saprotrophs*”, which are micro-organisms that obtain their nourishment from dead organic matter. They require the presence of ischemic and necrotic tissue debris, to provide a fertile environment for their proliferation. The dead tissues provide a source of nutrition and metabolic energy to these opportunistic pathogens. Saprophytes inhabiting the nasal cavities and paranasal



Diagrammatic representation of saprophytic and invasive tissue forms of pathogenic fungi

sinuses, usually exist as commensals which remain indolent on the surface and do not induce pathological changes within the nasal tissues, unless provoked by favorable conditions to become pathogens. The predisposing factors favoring them could be rampant allergy with polyposis, immunosuppression, prolonged steroid therapy, diabetes, surgery or traumatic inoculation into deeper tissues. Pharmacologic immune suppression is a significant contributor to flaring up of saprophytic infections. The use of corticosteroids in the early postoperative period may be a risk factor for the development of saprophytic infections, especially those resulting from fungal species.

SPECTRUM OF SAPROPHYTIC MYCOSES IN THE PARANASAL SINUSES

Candidiasis

Candidiasis (due to *C albicans* and other *Candida* spp.) is the most common opportunistic fungal infection. *Candida albicans* is the most common cause of candidiasis. The principal risk factors predisposing to deeply invasive candidiasis are protracted courses of broad spectrum antibiotics, cytotoxic chemotherapy, corticosteroids.

Aspergillosis

Invasive aspergillosis most frequently involves the paranasal sinuses. This fungus may disseminate from the lungs to involve the brain, kidneys, liver, heart, and bones. The main portal of entry for aspergillosis is the respiratory tract in

susceptible hosts. Quantitative and functional defects in circulating neutrophils are key risk factors for development of invasive aspergillosis. For example, neutropenia due to cytotoxic chemotherapy and systemic corticosteroids are common predisposing factors for invasive aspergillosis.

Zygomycosis

Zygomycosis due to *Rhizopus*, *Rhizomucor*, *Absidia*, *Mucor* species, or other members of the class of Zygomycetes, also causes invasive sinus infections. An especially life-threatening form of zygomycosis (also known as mucormycosis), is known as the rhinocerebral syndrome, which occurs in patients with diabetic ketoacidosis, neutropenia and corticosteroid therapy.

Cryptococcosis

Cryptococcosis is most typically an opportunistic fungal infection that trespasses the sinuses and most frequently causes pneumonia and/or meningitis. Defective cellular immunity, especially associated with the acquired immune deficiency syndrome, is the most common risk factor for developing cryptococcosis.

Pheohyphomycosis

Pheohyphomycosis is an infection by brown to black pigmented fungi of the cutaneous, superficial, and deep tissues, with predilection to spread to brain via intranasal route. These infections are uncommon, life-threatening, and occur mostly in immunocompromised states.

Hyalohyphomycosis

Hyalohyphomycosis is an opportunistic fungal infection caused by any of a variety of normally saprophytic fungi with hyaline hyphal elements. For example, *Fusarium* spp. infect neutropenic patients to cause pneumonia, fungemia, and disseminated infection with cutaneous lesions.

PATHOPHYSIOLOGY OF INVASIVE SAPROPHYTES

The saprophytic fungus is suspected to be a pathogen, if it is isolated repeatedly from nasal discharge with microbiological examination showing the fungal elements compatible in morphology with fungus isolated from the biopsy specimen whose histopathology showed tissue invasion. Pathological saprophytes, mostly belong to the Phycomycetes group of aerobic fungi. Phycomycetes are ubiquitous in nature, commonly found in decaying vegetation, soil, and bread mold. They grow rapidly and can release large numbers of airborne spores. Thus, they are frequently found colonizing the oral mucosa, nose, paranasal sinuses, and throat. Phycomycetes do not generally cause disease in immunocompetent individuals who are able to generate phagocytic containment of the organisms. Persons at risk of infection, typically have decreased phagocytic activity because of an impaired glutathione pathway which predisposes to saprophytic infestation within the nose and sinuses.

Rhinocerebral mucormycosis, is a well-recognised opportunistic infection caused by saprophytic fungi of the mucoraceae family. Saprophytic aerobic fungi of the Phycomycetes class (order Mucorales) cause mucormycosis, also known as “Phycomycosis”. The three genera responsible for most cases include *Rhizopus*, *Absidia*, and *Mucor*. Recently researchers have also reported cases of rhinocerebral mucormycosis caused by *Rhizomucor*, *Saksenaia*, *Apophysomyces*, and *Cunninghamella* species.

Rhizopus species have an active ketone reductase system that enables them to thrive in an acidic pH and glucose-rich medium. Hyperglycemia enhances fungal growth and impairs neutrophil chemotaxis; therefore, individuals with Diabetic ketoacidosis are commonly affected. *Rhizopus* species also favor an iron-rich environment and are frequently isolated in patients receiving desferoxamine therapy (an iron-chelating agent). In most cases, the fungi gain entry to the body via inhalation of airborne spores through the nose and sinuses. It has been postulated that

the most common reservoir for organisms is the pterygo-palatine fossa.

Mucorales, normally saprophytic, germinate in the nasal cavities due to an infection and then colonize the sinuses, the orbit, followed by the meninges. Meningeal involvement with peri-orbital edema, exophthalmosis or oculomotor paralysis may occur in high-risk patients along with marked sinus symptoms. Infection spreads along vascular and neuronal structures infiltrating the walls of blood vessels and nerves. Infections can erode bone through walls of the sinus and can spread into the orbit and extend into the brain. Invasion of nerves, blood vessels, cartilage, bone, and meninges and perineural spread are common. Direct invasion by fungal elements results in thrombosis and nerve dysfunction. Advancing infection can result in thromboses arising in the cavernous sinus, carotid arteries, and jugular vein. Carotid artery occlusion has also been reported as a complication.

Mucormycosis has a fulminantly fatal clinical pattern. The diagnosis is based on the histology and the mycology of the nasal and sinus mucosa samples performed using special stains. Once the diagnosis is confirmed, the required treatment with high doses of intravenous Amphotericin-B must be administered immediately, otherwise the evolution may be fatal. The survival rates among patients with invasive sinus disease without cerebral involvement may be as high as 50-80%. If infection spreads to the brain, the case fatality rate can exceed 80%. The single most important prognostic factor in the eventual outcome of patients with invasive mucormycosis seems to be the integrity or breach of the meningeal barrier. The prognosis of mucormycosis may improve with rapid diagnosis, early management including combined antifungal and surgical interventions, and reversal of underlying risk factors like diabetic ketoacidosis. The survival rate is approximately 80% when both medical and surgical interventions are administered. The cause of death in many patients is mucormycosis infection itself, rather than the progression of the underlying disease.

PATHOPHYSIOLOGY OF NONINVASIVE SAPROPHYTES

Noninvasive saprophytic fungal growth may be found in one or more paranasal sinuses of patients who have chronic suppurative rhinosinusitis. Similar growth may occur within nasal debris of patients who have undergone aggressive sino-nasal surgery or those who have Rhinitis Sicca or Atrophic Rhinitis. Although fungal cultures may be positive, the

absence of histologic findings of invasive fungal elements, often suggest saprophytic fungal growth.

In the case of a saprophytic fungal ball, there is accumulation of mycelium resulting from deposit and deficient germination of spores from different inhaled fungi (*Aspergillus fumigatus*, *Aspergillus flavus*, *Alternaria* sp., *Rhizopus microsporus* and *Pseudallescheria boydii*) over the respiratory mucosa of one isolated paranasal sinuses without invading the mucosa. Even though it is not characterized by the presence of marked inflammatory response, there are local inflammatory reactions with identification of purulent secretion drained to the affected paranasal sinus. Treatment is directed to complete removal of fungi regardless of the chosen surgical technique (endoscopic, combined or external).

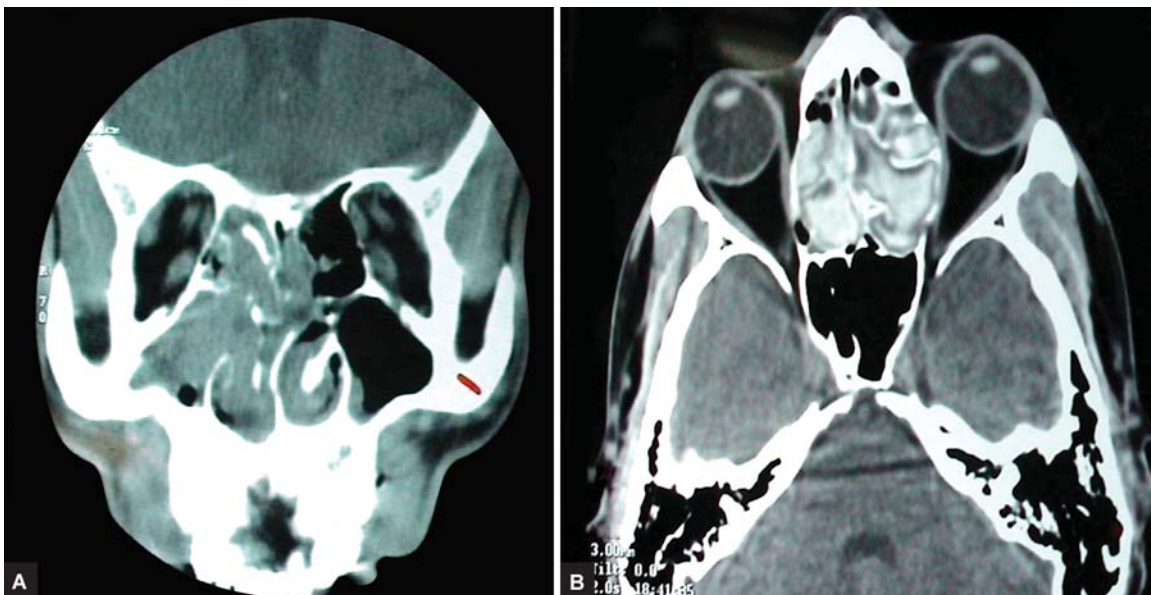
Allergic Fungal Rhinosinusitis (AFRS) is a form of benign, noninvasive sinusitis the histopathologic features of which are similar to those of allergic bronchopulmonary aspergillosis (ABPA). Most rhinologists believe that allergic fungal sinusitis (AFS) is an allergic reaction to fungi, in which fungal debris, allergic mucin, and nasal polyps are formed in the nasal cavity and paranasal sinuses. The causative fungi in allergic fungal sinusitis (AFS) are usually dematiaceous fungi, consisting of the genera *Bipolaris*, *Curvularia*, *Exserohilum*, *Alternaria*, *Drechslera*, *Helminthosporium*, and *Fusarium* and *Aspergillus*. A positive fungal culture along with presence of allergic mucin

remains the most reliable indicators of allergic fungal sinusitis. Patients with allergic fungal rhinosinusitis (AFRS) are atopic, but generally their symptoms will not resolve only with antihistamines and intranasal corticosteroids. Use of systemic corticosteroids and antifungal agents after surgical evacuation of the allergic fungal colonies within the sinuses produce marked relief of symptoms. In contrast to patients who have invasive fungal sinusitis, patients with allergic fungal sinusitis are always immune competent.

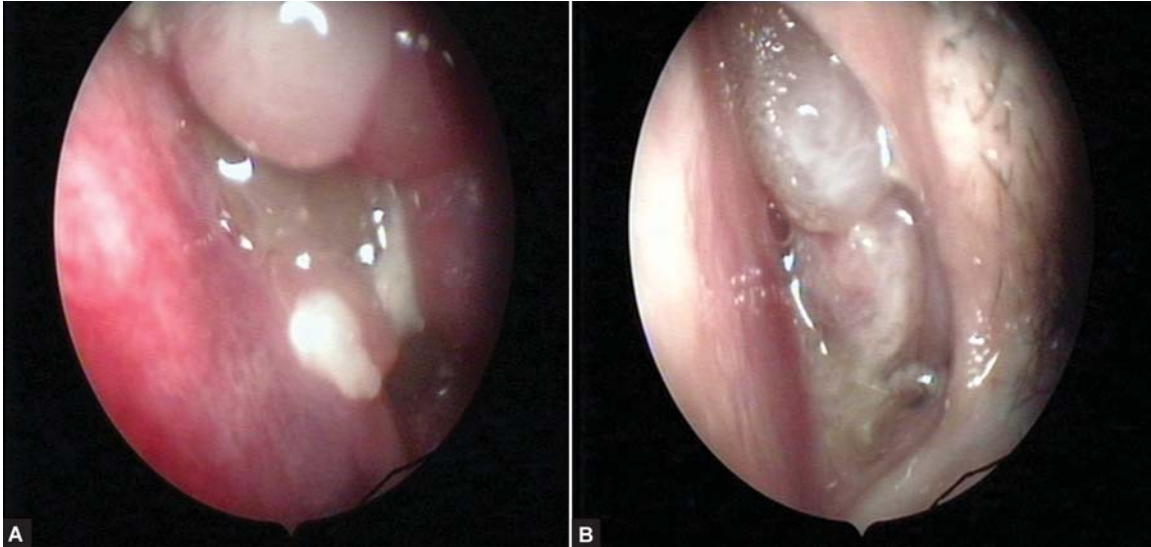
DIAGNOSIS AND TREATMENT

Radiographs reveal the involvement of often unilateral multiple sinuses, with heterogenous opacities within the sinuses and bony expansion along its walls (Figs 1A to 2B). Laboratory findings often support an allergic state, with a marked increase in eosinophilia and total serum IgE but the microbiological identification of these saprophytes remains paramount in further management of the infection.

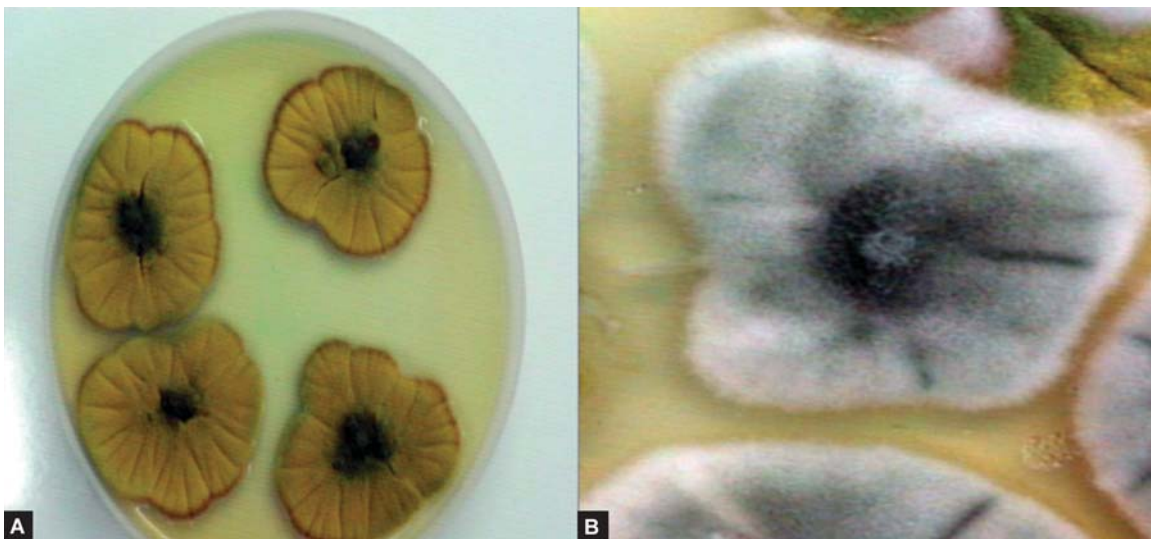
A systematic approach of material collection methods, type of medium and quick transport to a laboratory with experience in the study of fungi is essential to successfully identify these microorganisms. The contents of nasal lavage or collection by aspiration with sterile solution of infected areas under endoscopic vision should be quickly gathered and sent to the laboratory where trained staff can manipulate the sterile secretion with substances that dissolve the mucus and release possible fungi. Out of the collected material,



FIGURES 1A and B: Computed tomographic findings in fungal sinusitis may include mucosal thickening, air fluid levels, osteomeatal complex obstruction and heterogeneous opacification with local areas of high signal densities due to heavy metal deposition within the sinuses



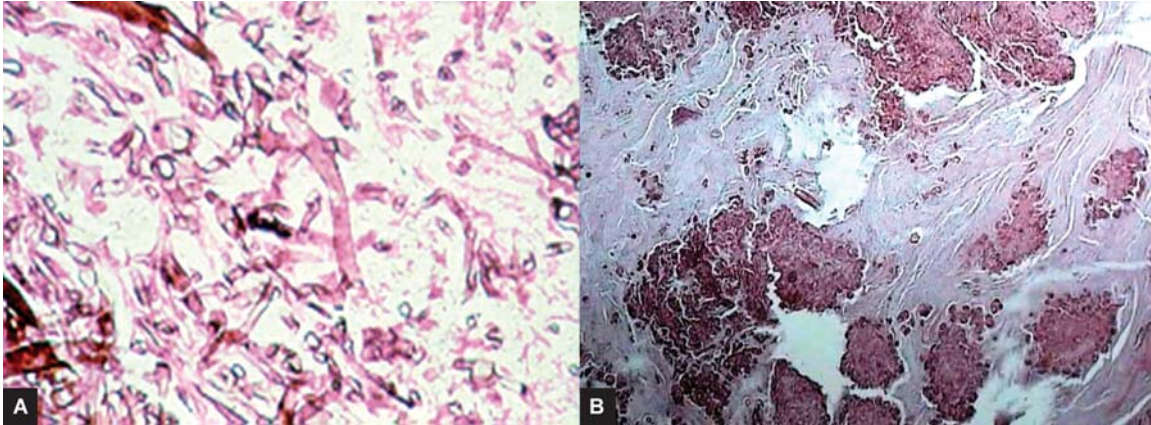
FIGURES 2A and B: Nasal endoscopy images of fungal colonies occluding the osteomeatal complexes along with polyps and allergic mucin



FIGURES 3A and B: *Aspergillus flavus* grow as flat colonies with yellowish green pigments and *Aspergillus fumigatus* grow as white colonies quickly becoming blue green with the production of conidia

0.5 ml needs to be cultivated in a medium of Sabouraud/ glucose (4%) with chloramphenicol (0.4 g l^{-1}) and gentamicin (0.04 g l^{-1}) and incubated for 30 days at 37° C and 30° C, respectively. Other 0.5 ml should be analyzed, if available, by PCR under strict technique to avoid false positive results by sample contamination. Material should also be submitted to microscopy for direct identification of fungal hyphae. In addition to investigate the presence of saprophytic fungi, specific skin and serological tests need to be performed in order to confirm whether the patient is allergic to the cultivated fungus (Figs 3A and B).

For most saprophytic fungi, RAST testing proves positive and immediate cutaneous reactivity to fungi is also present. Histopathologic review of the biopsy specimen from the sinuses may reveal characteristic “allergic mucin”, with numerous eosinophiles, Charcot-Leyden crystals and fungal hyphae, without any fungal tissue invasion (Figs 4A and B). Those patients with allergic mucin, but no documented fungi are indicated as having AFS-like syndrome. Current therapeutic recommendations include complete exenteration of all allergic mucin. Adjunctive, short-term systemic steroids often prove useful and nasal



FIGURES 4A and B: Histopathological photomicrographs of fungal sinusitis: Low power (10X) image showing allergic mucin with florid aggregates of eosinophils and Charcot-Leyden crystals; High power (40X) image showing colonies of fungi with irregularly branching septate hyphae and focal bulbous conidiophores

steroid spray should be continued for long term. Recurrence is common and thus close long-term clinical, endoscopic and radiographic follow-up remains mandatory.

ANTIFUNGAL TREATMENT PRINCIPLES IN ENT

- Correct identification of the fungus remains very essential for appropriate treatment. Use of standard antifungal regimens depends on fungus identified.
- Clinician should consider initial therapy as an induction phase with optimization in both dose and antifungal drug, which gives maximum fungicidal activity at the site of infection; consider combination therapy in certain case.
- Invasive Fungal Sinusitis in diabetics is more difficult to treat and hence the diabetic status needs to be controlled. Appropriate surgical debridement should be done as and when necessary.
- Antifungal agents are given systemically followed by oral antifungal agents for 6 weeks and more. Amphotericin B remains the drug of choice. In associated nephropathy, liquid based Amphotericin B is given in the dose of 1-5 mg/kg (Liposomal Amphotericin B) in order to reduce the nephrotoxicity. After a reasonable control, Itraconazole (Sporanox) in the dose of 100 to 400 mg/day may be given. Sodium supplements are useful to reduce nephrotoxicity. Liquid preparation of Amphotericin B can be used as a topical application through the nasal cavity. Hyperbaric Oxygen may reduce the ischemic acidotic condition.
- The fungal manifestation is dependent on the patient's immunologic status. Control of the underlying medical or immunosuppressive conditions is mandatory.

- Clinician must pay particular attention to drug interactions, pharmacokinetics, and resulting toxicities; this may require measurement of drug levels in certain circumstances.
- Follow-up for relapse/ re-infection after treatment should be at least 6 months to a year depending on fungus and type of infection.

CONCLUSION

Saprophytic fungi are ubiquitous and omnipresent in nature, mostly surviving on dead organic plant matter. Some species have the propensity to survive as commensals within the body cavities of humans, including the nose and paranasal sinuses. When the favorable situation arises, as in immunocompromised status, prolonged steroid therapy or post-surgical exposure of raw areas, these dimorphic fungi metamorphosize into invasive forms and present in a panoramic spectrum of clinical manifestations. Successful treatment of such indolent mycotic infections, largely depends on the accurate identification of the pathogen and early, appropriate intervention by surgical clearance, supported with antifungal medications as per standardized regimens.

REFERENCES

1. Odds FC, Arai T, DiSalvo AF, Evans EGV, Hay RJ, Randhawa HS, Rinaldi MG, Walsh TJ: Nomenclature of fungal diseases. *J Med Vet Mycol* 1992;30:1.
2. Rinaldi MG, Dixon DM (Eds). The evolving etiologies of invasive mycoses. *Infect Dis Clin Pract* 1994;3(suppl):S47.
3. Rippon JW: *Medical Mycology. The Pathogenic Fungi and the Pathogenic Actinomycetes* (3rd ed) Philadelphia: WB Saunders Co;1988.
4. Walsh TJ, Pizzo: Nosocomial fungal infections. *Ann Rev Microbiol* 1988;42:517.

5. Mucormycosis of the Nose and Paranasal Sinuses – Berylin J. Ferguson, MD – Otolaryngologic Clinics of North America.
6. Schubert MS. Medical Treatment of Allergic Fungal Sinusitis. *Ann Allergy Asthma Immunol* 2000;85:90-97.
7. Stringer S, Ryan MW. Chronic Invasive Fungal Rhinosinusitis. *Otolaryngol Clin North Am* 2000;33:375-87.
8. Definitions of Fungal Rhinosinusitis – Berylin J. Ferguson, MD – Otolaryngologic Clinics of North America.
9. Agents for treatment of Invasive Fungal Infections – Beatriz Luna, Pharm D, Richard H Drew, Pharm D, MS, and John R. Perfect, MD – Otolaryngologic Clinics of North America.
10. Kauffman CA, Carver PL: Use of azoles for systemic antifungal therapy. *Adv Pharmacol* 1997;39:143-89.
11. Voss A, Meis JFGM, Hoogkamp – Korstanje JAA: Fluconazole in the management of fungal urinary tract infections. *Infection* 1994;22:247-51.
12. Alphin AL, Strauss M, et al. Allergic fungal sinusitis: Problems in diagnosis and treatment. *Laryngoscope* 1991;101:815-20.
13. Lebowitz RA, et al. Isolation of fungi by standard laboratory methods in patients with chronic rhinosinusitis. *Laryngoscope* 2002;112:2189-91.