

## SURGICAL TECHNIQUE (REPRINT)

# Middle Fossa Approach

<sup>1</sup>JJ Waterval, <sup>2</sup>RJ Stokroos, <sup>3</sup>J Dings

## INTRODUCTION

A middle fossa approach is an operation technique that offers surgical access to the lateral skull base including the cranial side of the petrous bone, the internal auditory canal, the geniculate ganglion of the facial nerve canal and the petrous apex.

In earlier days, this approach was widely used for surgical removal of small intracanalicular vestibular schwannomas. Hearing preservation was thought to be accomplished if removed early. Nowadays, with the more conservative treatment of vestibular schwannomas, radiotherapy or radiosurgery is chosen more often, if treated at all. Moreover, the technique has mostly been deserted for this indication because the risk of iatrogenic facial nerve palsy is considered too high.

## INDICATIONS

The middle fossa approach can be used for a variety of indications (Fig. 13):

- Resurfacing technique for superior semicircular canal dehiscence syndrome
- Internal auditory canal decompression for
  - Skull base bone dysplasias, such as hyperostosis cranialis interna with encroachment of the internal auditory canal due to hyperostosis causing (expected) function loss of the facial or vestibulocochlear nerve.<sup>1,2</sup>
  - Facial nerve schwannomas
- Supralabyrinthine cholesteatomas
- Meningoencephalocele or cerebrospinal fluid leakage repair, either primary surgery or in case of previous failed transmastoid surgery. Either intradural or extradural
- Cholesterol granulomas or congenital cholesteatomas of the apex
- A wide number of neurosurgical lesions.

## SPECIFIC PREOPERATIVE EVALUATION

- Pure tone audiogram and speech audiogram
- High-resolution CT scan
  - For diagnostic purposes in case of bone dysplasia and superior semicircular canal dehiscence syndrome
  - For neuronavigation purpose for any indication
- MRI scan with gadolinium if neuronitis or neural edema in specific preoperative evaluation of the facial nerve
- Diffusion-weighted MRI scan in case of supralabyrinthine or congenital apex cholesteatomas
- Sequential brainstem-evoked auditory potentials can be helpful to detect subclinical auditory nerve damage.
- Vestibular function testing.

## ANESTHETIC CONSIDERATIONS

- General anesthesia with orotracheal intubation
- Use short-acting nondepolarising muscle relaxant to secure nerve monitoring
- Arterial line for real-time blood pressure measuring
- Urinary catheter
- Perioperative antibiotics are administered (cefazolin or amoxicillin/clavulanic acid and continued for 1 week postoperatively)
- Hydrocortisone IV is administered in case of intraoperative nerve manipulation.

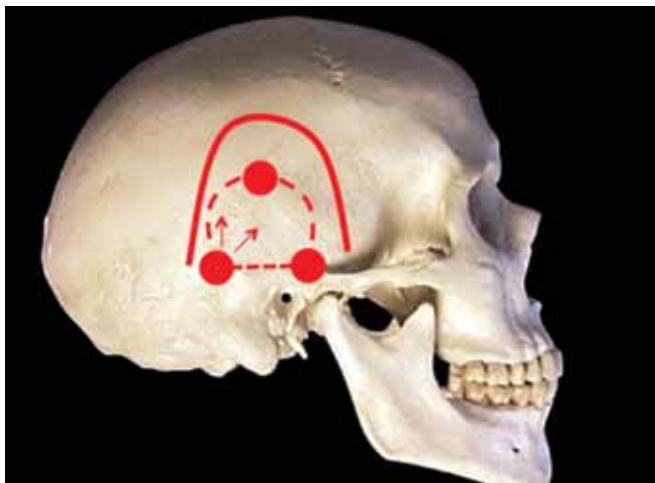
## SURGICAL STEPS

### General Procedure

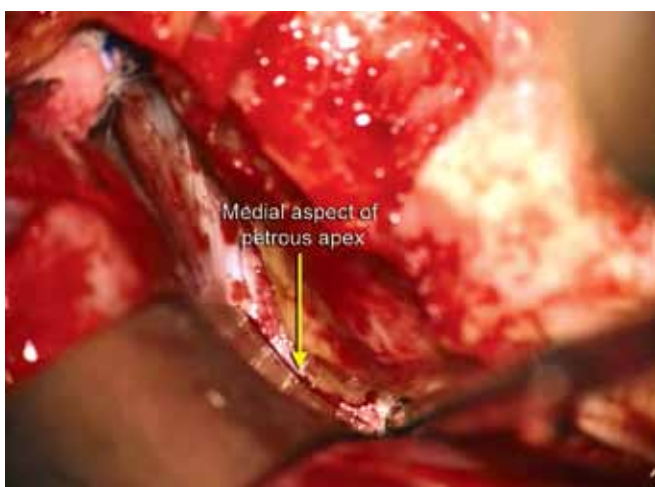
- The head is fixed in a skull clamp. The authors prefer to use one of the available Mayfield® skull clamps.
- Intraoperative nerve integrity monitoring is advised. The authors use Nerve Integrity Monitoring System (NIM®) by Medtronic.
- A neuronavigation system is strongly advised to be used depending on the type of indication and the experience of the surgeon. The authors prefer a Medtronic® Surgical Navigation System.
- Intraoperative brainstem-evoked auditory potentials are monitored in case of internal auditory canal decompression.
- The hair over the temporal region is shaven and the operation field is sterilized.

<sup>1,2</sup>Department of Otorhinolaryngology and Head and Neck Surgery, Maastricht University Medical Center, The Netherlands

<sup>3</sup>Department of Neurosurgery, Maastricht University Medical Center, The Netherlands

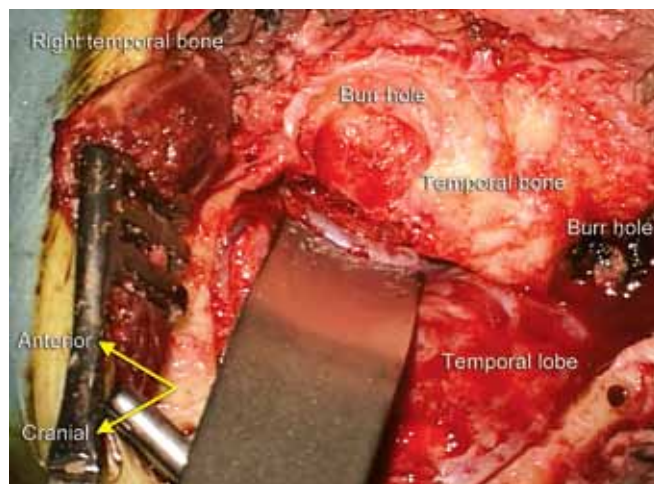


**Fig. 1:** Anatomical orientation for approach. Continued line: incision; three dots: burr holes; arrows: direction of removing the trepanation away from the sinus, to avoid damage of de transverse/sigmoid sinus



**Fig. 3:** Visualization of the petrous apex

- Cranial to the ear, an inverted U- or V-shaped incision is made (Fig. 1). The internal auditory canal lies in the extension of the external canal. The internal auditory canal should be in the center of the operation field. The slight anterior angulation of the temporal bone should be kept in mind.
- Anteriorly the incision should not exceed the anterior margin of the sideburn in order not to damage the temporozygomatic branch of the facial nerve.
- The temporal fascia and temporal muscle are split in an inverted T-shape.
- A trepanation of approximately 5 (width) × 3 to 5 (height) cm is made by creating 3 or 4 burr holes and connecting these with an oscillating saw, extending over the width of the temporal bone (Fig. 1). Often it cannot be avoided that the posterior hole is created at the level of the transverse/sigmoid sinus causing venous bleeding. This can be stopped with Surgicel<sup>®</sup>, cottonoid or bone



**Fig. 2:** Operation field after trepanation. Anatomical landmarks and orientation are indicated

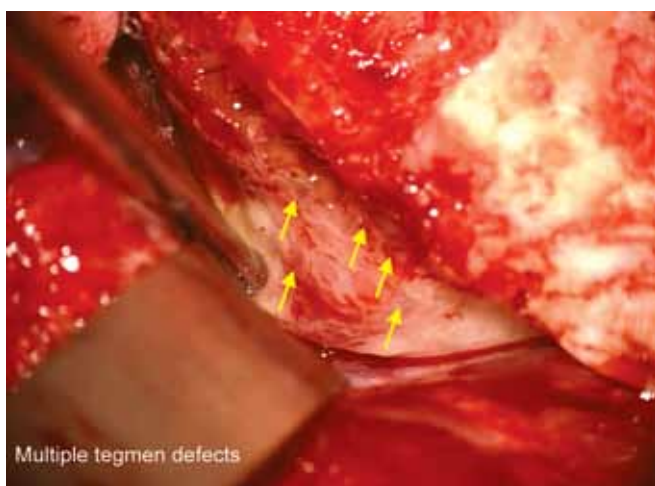
wax. The anterior hole is made just cranial to the root of the zygomatic arch.

- The trepanation can be detached from the dura mater with a freer working away from the transverse/sigmoid sinus (Fig. 1). Keep contact to the bone during mobilization. The vein of Labbé (or inferior anastomotic vein) should be kept in mind, even during an extradural procedure, and not injured. Its normal course is from the temporal lobe to the superior petrosal sinus, but an aberrant course through a dural fold is not uncommon.
- The arcuate eminence, if present, lies in a 90° angle with the posterior border of the petrous bone. Anteriorly the greater superior petrosal nerve is often encountered.
- Small guiding holes are burred within the trepanation and the skull for suturing the trepanation afterwards.
- The temporal lobe is then retracted cranially with a malleable spatula, the authors use the BUDDE<sup>®</sup> Halo Retractor System, which is compatible to the Mayfield<sup>®</sup> skull clamp setup. The spatula is placed cranial to the tip of the petrous apex (Figs 2 and 3).
- After the therapeutic procedure is completed the trepanation is sutured back into the skull with nonabsorbable material, the burr holes are filled with bone pâté, the muscle and fascia are closed with absorbable material and the wound is closed.

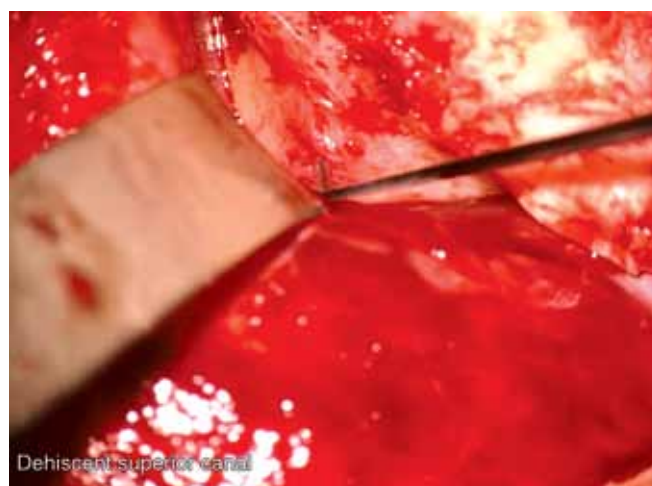## SPECIFIC CONSIDERATIONS FOR TWO DIFFERENT INDICATIONS

### *Resurfacing Technique for Superior Semicircular Canal Dehiscence Syndrome (Figs 4 and 5)*

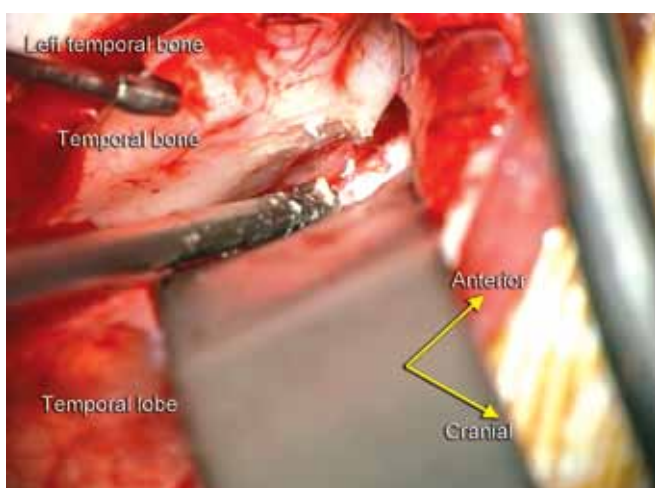
Resurfacing rather than plugging is preferred to treat superior semicircular canal dehiscence, because plugging is



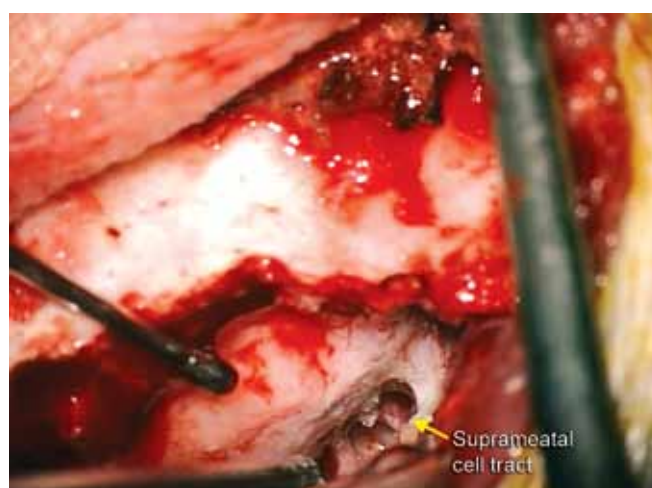
**Fig. 4:** Multiple tegmen defects in case of superior semicircular canal dehiscence syndrome



**Fig. 5:** Dehiscent superior semicircular canal



**Fig. 6:** Operation field after trepanation. Anatomical landmarks and orientation are indicated



**Fig. 7:** Supralabyrinthine and suprameatal cell tracts

thought to irreversibly damage the physiological function of the canal. This is the reason why this technique is preferred over the transmastoid technique. Dehiscence of the superior canal is often accompanied with an extremely pneumatized petrous bone making it possibly difficult to recognize the superior semicircular canal. Detachment of the dura off the membranous superior canal should be done with extreme care, since rupturing it causes endolymph leakage.

The canal is covered with a dural graft such as Duragen®. Autologous temporal muscle fascia or Tutoplast® may also be used. Bone pâté harvested at the time of the craniotomy is used to resurface the area. Another layer of graft is applied on top, followed by fibrin glue such as Tissucol®. In earlier days, the authors applied bone pâté directly on the defect.

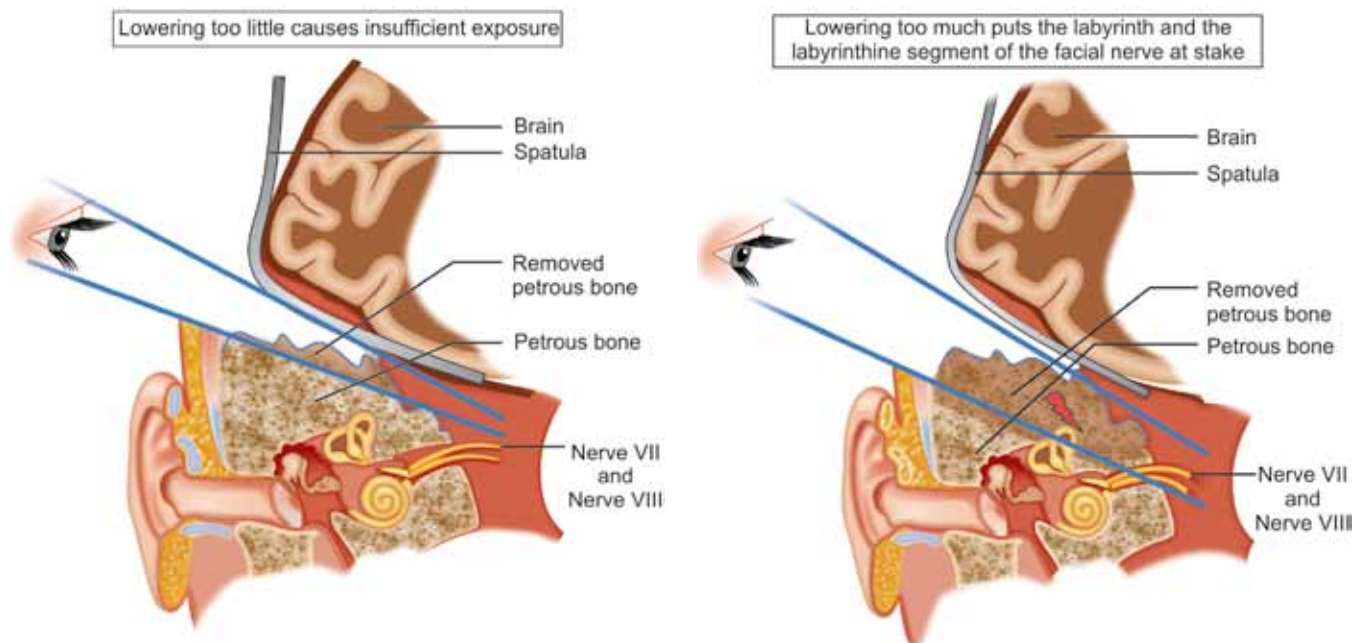
#### *Internal Auditory Canal Decompression for Skull Base Bone Dysplasias*

A series of bone dysplasias such as osteopetrosis, Camurati-Engelman disease, Van Buchem disease, osteosclerosis and

hyperostosis cranialis interna can cause internal auditory canal encroachment due to hyperostosis of the skull base. Preoperative imaging workup is essential to make sure encroachment is specifically caused at the level of the internal auditory canal. In case of additional encroachment at the labyrinthine, tympanal or mastoidal part of the fallopian canal the procedure must be extended with decompression of these levels. A neuronavigation system is of vital importance for this indication, because surgical landmarks can be extremely distorted due to hyperostosis.

- The superior aspect of the temporal bone is lowered with a diamond burr (Fig. 6).
- If present, supralabyrinthine and suprameatal cell tracts are opened and followed medially (Fig. 7).
- The more pronounced the hyperostosis, the less likely are the presence of the standard landmarks and the more limited is the exposure. It is often hard to identify the labyrinthine structures of the otic capsule, given the fact that the hyperostotic bone is of similar consistency.





**Fig. 8:** Illustration of the importance of the right operative field with its pitfalls

- The cranial side of the petrous bone (in this case hyperostotic bone) should be removed to reach the internal auditory canal. If too much bone is removed the inner ear structures can be damaged causing deafness/ facial nerve palsy, in case too little bone is removed no appropriate exposure of the internal auditory canal can be obtained (Fig. 8).
- A superior ridge of the apex can be left to place the spatula behind (Fig. 9).
- The porus is approached by drilling the anterior petrous apex slightly anterior to the expected location of the porus, then moving in a posterior direction. As soon as the porus or in this case, the internal auditory canal is localized, the canal is 'egg-shelled' and opened over an arc of approximately 180° (Figs 10 to 12).

#### ANY NEWER TECHNIQUE/MODIFICATION IN THE SURGERY

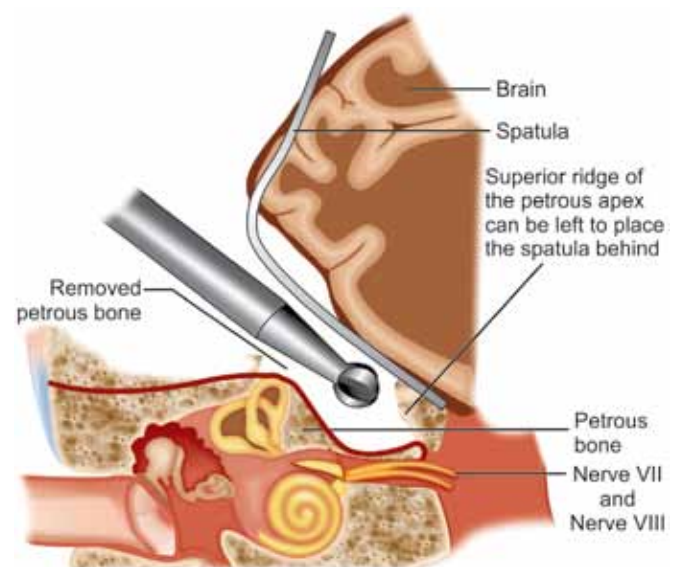
- By extending the posterior limb of the incision over the mastoidal part of the petrous bone, the mastoid cavity can be opened separately to allow access for decompression of the tympanic and mastoidal segments of the facial nerve.
- If necessary in case of tumor removal, the middle fossa approach can be extended with a posterior fossa approach technique, such as retrosigmoid or trans- or retrolabyrinthine.
- Transmastoidal plugging of the superior canal can be considered in patients with superior semicircular

canal dehiscence, however the physiologic function of the canal is lost. It can be a good alternative for patients with moderate health conditions and severe complaints.

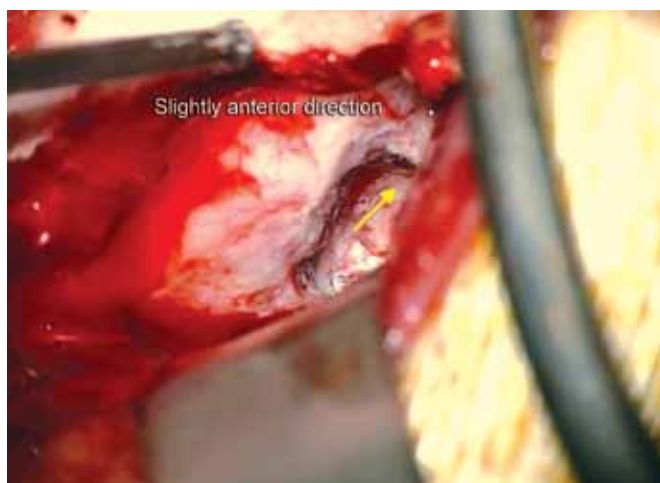#### COMPLICATIONS

##### General Complications

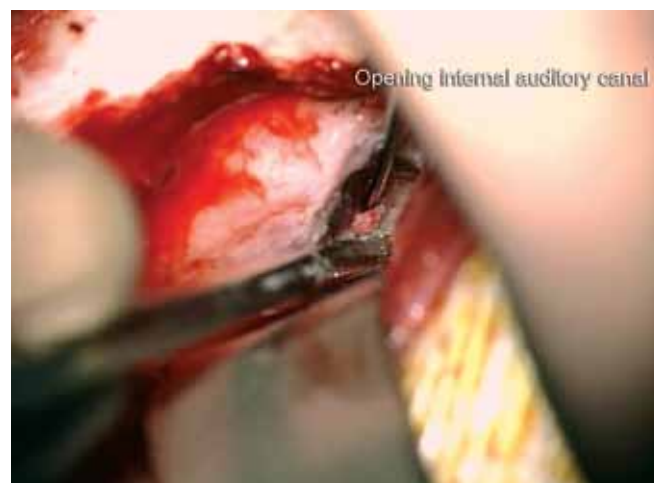- Facial nerve palsy
- Vestibulocochlear nerve damage
- Cerebrospinal fluid leakage with possible sequelae (e.g. lumbar drain, meningitis)
- Intracranial extradural or intradural hemorrhage
- Meningitis.



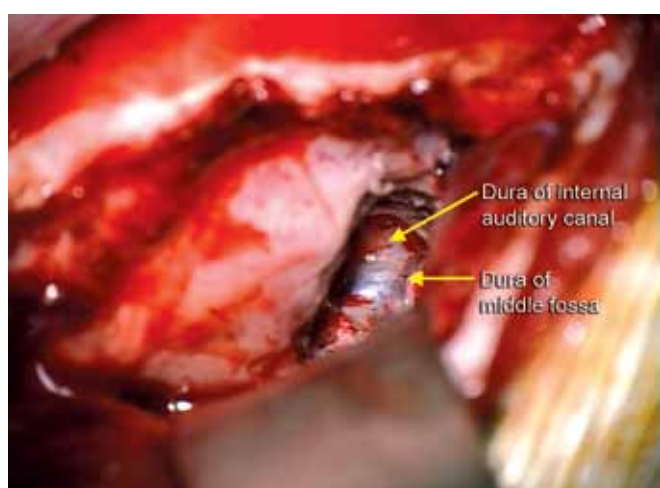
**Fig. 9:** Correct field of view



**Fig. 10:** Localization of the porus of the internal auditory canal



**Fig. 11:** Opening the internal auditory canal



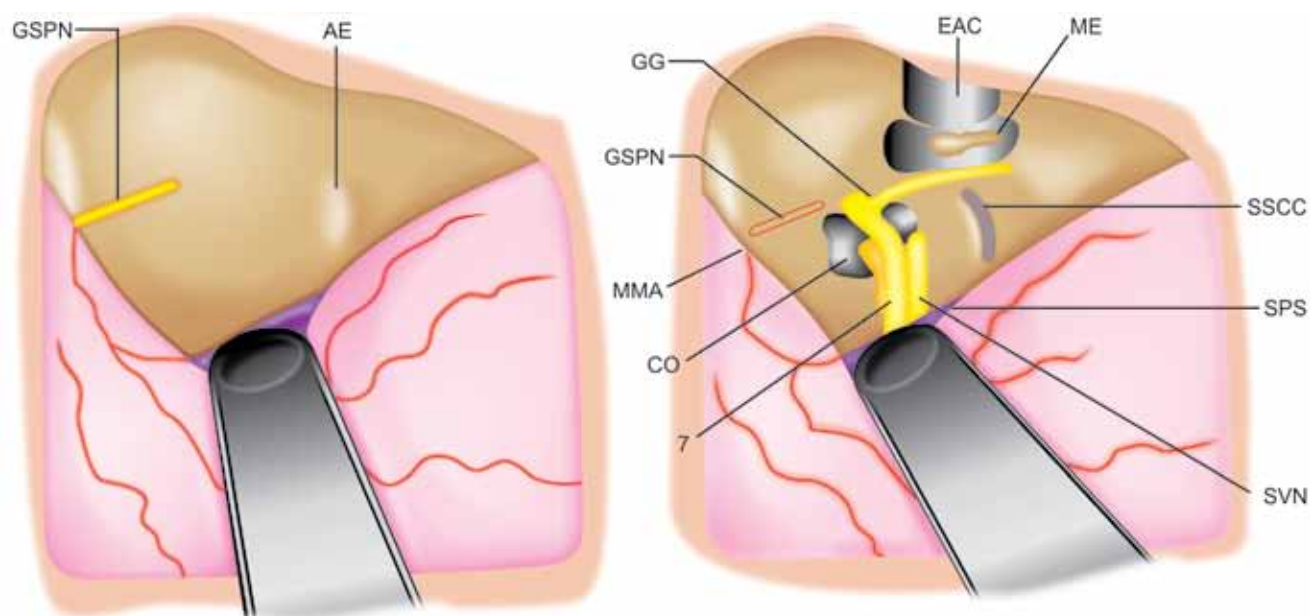
**Fig. 12:** The internal auditory canal after opening

### Resurfacing Superior Semicircular Canal

- Temporary deterioration of the symptoms
- Superior semicircular canal function loss characterized by acute continuous postoperative vertigo accompanied with the canal-specific nystagmus (theoretically an upbeat nystagmus with torsional component away from the operated side)
- (Sterile) labyrinthitis, treated with steroids.

### SPECIAL INSTRUMENTS USED FOR THE SURGERY

- One of the various available Mayfield® skull clamps
- Nerve Integrity Monitoring System NIM® by Medtronic



**Fig. 13:** Schematic anatomical orientation of the middle ear and inner ear structures in relation to a middle fossa approach. (EAC: External auditory canal; ME: Middle ear; GG: Geniculate ganglion; GSPN: Greater superior petrosal nerve; MMA: Middle meningeal artery; CO: Cochlea; SVN: Superior vestibular nerve; SPS: Superior petrosal sinus; SSCC: Superior semicircular canal; AE: Arcuate eminence; 7: Facial nerve)

- Medtronic® Surgical Navigation System
- BUDDE® Halo Retractor System.

## REFERENCES

1. Waterval JJ, Stokroos RJ, De Bondt RB, Manni JJ. Facial nerve decompression via middle fossa approach for hyperostosis cranialis interna: a feasible therapeutic approach. *J Laryngol Otol.* 2009;123(10):1177-1180.

2. Waterval JJ, van Dongen TM, Stokroos RJ, De Bondt BJ, Chenault MN, Manni JJ. Imaging features and progression of hyperostosis cranialis interna. *AJNR Am J Neuroradiol* 2012;33(3):453-461. Epub 2011 Dec 22.

## FURTHER READING

1. Atlas of skull base surgery and neurotology. Robert J. Jackler. 2nd ed. Published by Thieme Medical Publishers, Inc.

