

Aggressive Metastasizing Pleomorphic Adenoma— A Wolf in Sheep's Clothing: A Case Report with Review of Literature

RF Chinoy, D Dalmia, RS Mundhe, MA DeSouza, V Rane

ABSTRACT

Metastasizing pleomorphic adenoma (MPA) is a rarity, and detailed immunohistochemistry (IHC) work-up is being documented in this case. Most cases present with metastasis after a period of several years, ranging from 1.5 to 51 years. The present case deals with a morphologically and immunologically benign pleomorphic adenoma of the parotid, behaving in a paradoxically aggressive fashion at the local site, at the time of initial diagnosis. Regional nodal metastasis and significant local perineural and intraneural infiltration were identified at presentation. In view of the strong tumor neural affinity, the differential diagnosis included an atypical tubular form of adenoid cystic carcinoma (ACC). However, ACC was ruled out on morphology and by IHC. Literature is reviewed and the varied spectrum of reported cases is briefly put forth.

Keywords: Salivary gland, Pleomorphic adenoma, Metastasizing, Immunohistochemistry, Differential diagnosis.

Source of support: Nil

Conflict of interest: None declared

CASE PRESENTATION

A 50-year-old male presented with a painless swelling in the Parotid region, present for a few months. The patient had no prior history of any surgery in the head and neck region.

FNAC of the parotid done at the Railway hospital was diagnosed as a benign salivary gland tumor, viz a pleomorphic adenoma (PA) of the salivary gland. However, one of the authors viz. the treating surgeon had observed partial facial palsy and clinically suspected involvement of the facial nerve by a more sinister pathology. Hence, the superficial parotid gland and a lymph node were excised and sent to us for frozen section reporting.

Pathology

The freshly excised parotid gland received for FS measured $3.5 \times 3.5 \times 1$ cm totally and included a discrete lymph node measuring 2×1.5 cm. The cut surface of the parotid showed a firm glistening white tumor mass measuring $2 \times 1.5 \times 1$ cm,

with one surface of tumor abutting against the edge of the salivary gland. The lymph node was grossly unremarkable.

The FS revealed a conventional pleomorphic adenoma (Fig. 1), but with the unusual additional feature of peri and intraneural invasion (Fig. 2). To confound the issue further, the FS of the node also showed micrometastasis at the hilum. A second intraparotid node also showed metastasis (Fig. 3). The overall findings were pointing at an aggressive behavior pattern, even though there was no morphological evidence of a malignant mixed tumor.

On conveying this report to the surgeons telephonically, we received two further specimens for FS, viz the tissue engulfing the zygomaticotemporal branch of the facial nerve and tissue engulfing the cervicofacial branch of the facial nerve. All tissues submitted for FS showed classical features of a pleomorphic adenoma, and though there were focal areas with an adenoid cystic morphology, this feature did not dominate the picture, nor was this the component seen involving the nerves or within the metastatic nodes. At that point, we did consider the possibility of an atypical tubular variant of adenoid cystic carcinoma (ACC) judging by the striking perineural invasion and the hilar metastasis. However, on light microscopy and subsequent IHC, the basic picture remained that of a pleomorphic adenoma.

All subsequent tissues received in our laboratory were examined thoroughly with paraffin sections. They included the rest of the superficial parotid, the superficial temporal artery, soft tissues over the temporomandibular joint, left side of the parotid duct and the nerve. The surgeon had aimed at achieving complete resection, leaving no residual gross disease behind.

All the tissues, without exception, showed features of a PA, often with perineural invasion. A small intraparotid node also showed metastasis. Four other lymph nodes around the gland were not involved.

Immunohistochemistry (IHC) Studies

Tumor showed a very low Ki67 index, (approximately 2-3%), weak p53 positivity, a negative C kit and positive GFAP (Fig. 4). The marker GFAP, (supposedly an antibody against myoepithelial cells present in PA and reportedly absent in adenoid cystic carcinomas), was important in our case, helping to rule out ACC.³

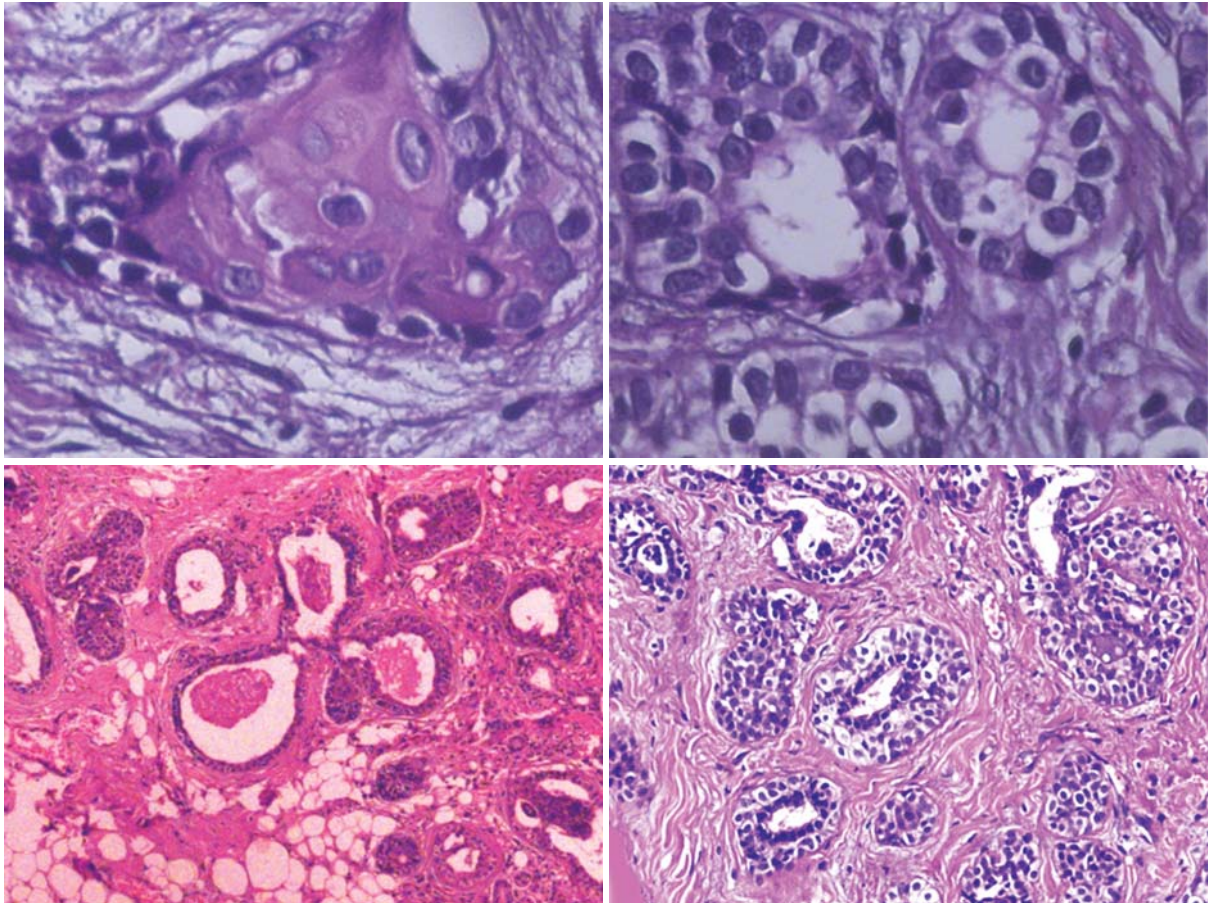


Fig. 1: Area of a conventional mixed tumor with squamous metaplasia

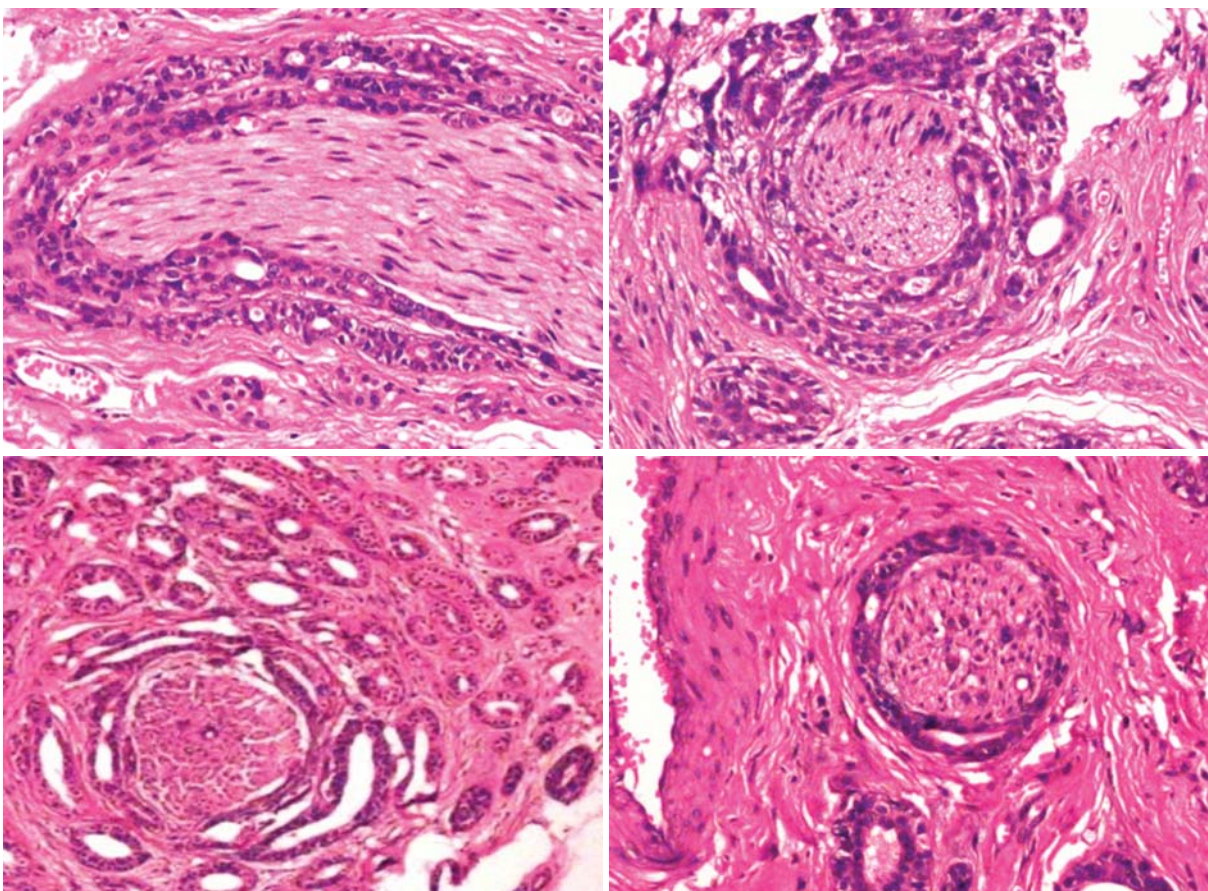


Fig. 2: Conspicuous perineural infiltration by double-layered glandular epithelium

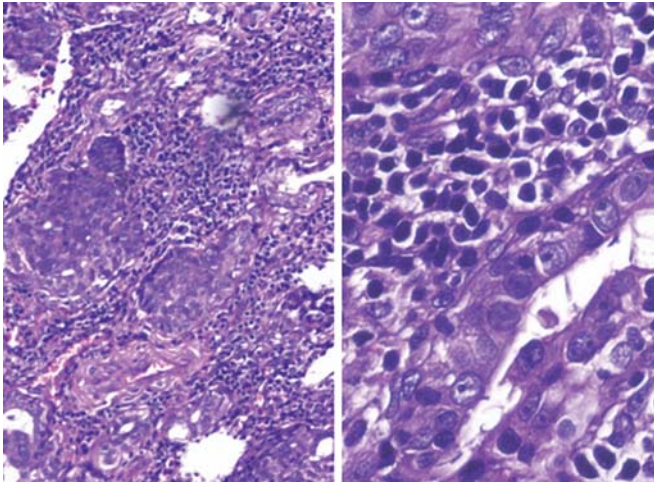


Fig. 3: Intraparotid nodal metastasis

At the time of primary diagnosis, there was no evidence of distant metastasis to bone, liver, lung or brain. A final diagnosis of ‘aggressive metastasizing pleomorphic adenoma, with extra-salivary extension, perineural infiltration and metastasis to two nodes’ was submitted.

The patient was advised local postoperative radiotherapy and a close follow-up.

INTRODUCTION

Metastasizing pleomorphic adenoma (MPA) is one of those rare tumors that breaks every rule of pathology books

dealing with morphology linked prognostic facets. Speaking of an ‘adenoma’ in the same breath as ‘metastasizing’ is not just puzzling, it is a call to look deeper, at what may lurk at an immunological and molecular level.

The World Health Organization (WHO) defines MPA as a ‘histologically benign pleomorphic adenoma that inexplicably manifests local or distant metastasis.’ It is further postulated by WHO that ‘multiple recurrences and surgical procedures allow some tumors to gain venous access and metastasize’.⁴ In several published case reports, there is overwhelming evidence of incomplete surgery at the time of initial removal of the PA, thereby stressing the need for meticulous initial surgery with clear resection margins, even for a benign PA.^{2,5} In our case, there is no question of offering any such escape route to explain metastasis, as our patient never had prior surgeries. Moreover, there was regional nodal metastasis at the time of diagnosis of the PA.

DISCUSSION

Salivary gland tumors represent 1 to 4% of all human neoplasias, and PA is the most common tumor.⁴ The common initial site of involvement of MPA is the parotid gland (74%), followed by minor salivary glands (17%) and submandibular glands (10%). Malignant transformation of PA into carcinoma ex-pleomorphic adenoma (CEPA) or

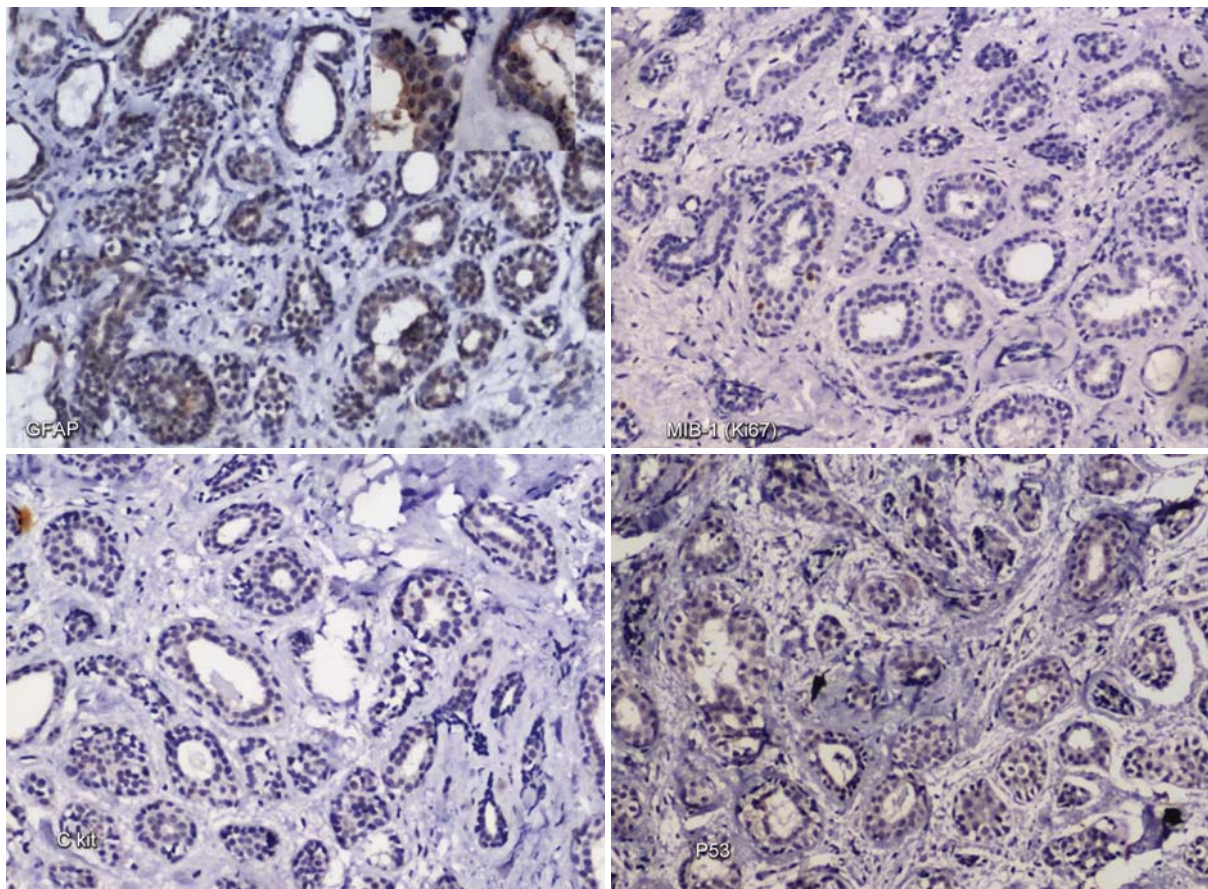


Fig. 4: IHC findings: GFAP—positive, MIB-1 (Ki67)—low, P53—weak positive and C-kit—negative

carcinosarcoma is rare. At the extreme end of the spectrum of malignant PA is the metastasizing pleomorphic adenoma (MPA) which behaves aggressively, even while it retains its innocuous/benign morphology. MPA has also been seen to progress rapidly with immunosuppression.² Most patients (81%) with MPA have a history of at least one local recurrence of PA prior to the detection of distant metastasis, which can take place as many as 1 to 51 years after detection of the primary with a mean of 16.3 years.^{1,2} The preferred metastatic site appears to be for bones (45%) followed by head and neck (43%), lungs (36%) and abdominal viscera (10%). Interestingly in the head neck site, only 17% metastasized to lymph nodes.²

The present case is unusual in several ways in that at initial presentation itself, there was nodal metastasis and a strong neural affinity (Figs 2 and 3). We have not been able to find any other reference dealing with a similar presentation of MPA. An excellent review of world literature by Nouraei et al² described 42 cases published between the years 1953 and 2005, where the histology of the primary PA matched that of the metastatic lesions. Most of these cases had at least one loco-regional recurrence prior to distant metastasis, and the mean latency period of presentation to metastasis was 16 years. In our case, local invasion into nerves and metastasis to the immediate regional nodes was simultaneously seen at primary presentation. Yet the tumor remained morphologically and immunologically quite benign, with conventional squamous, glandular, myoepithelial and adenoid cystic-like areas, in a fibromyxoid stroma.

The IHC was very low for proliferative marker Ki67 (approximately 2-3%). Markers for myoepithelial cells were positive (p63, SMA, Bcl2 and P53). Several issues were considered at the time of diagnosis hence we carried out a panel of IHC. Firstly, we considered the DD of a tubular variant of adenoid cystic carcinoma, versus a PA. To address this question, we conducted a panel of IHC markers, suggested by Choi et al³ (Table 1).

In the present case, the tumor showed a very low Ki67 index, weak P53 positivity, a negative C kit and positive GFAP. Pleomorphic adenomas almost always have a low Ki67 proliferative index, (mean 1.6%) and weak Bcl2. In contrast, adenoid cystic carcinomas have a high proliferative index (which depends partly on the grade of the tumor) higher p53 protein stain and intense staining for Bcl2. In our case, the only oddity was the positive Bcl2 staining. Marker GFAP, which highlights myoepithelial cells was positive in our case, thereby negating the possibility of this being an ACC. There are only a few published reports where IHC markers were done for MPA.^{3,6}

The second question to address was why was a PA metastasizing? We have no explanation for this behavior

Table 1: Categorization of PA and ACC on IHC^{1,3}

Marker	Pleomorphic adenoma	Adenoid cystic carcinoma
Ki67	Mean of 1.6%	20.5 to 54%
GFAP	Positive	Negative
C kit	Can be positive in epithelial cells	Usually 100% positive
P53	Mean 1.2%	Mean 4.3 to 24%
Bcl2	Weak stain	Intense strong positive

on light microscopy or on IHC. There was local invasion of nerves, but no evidence of mitosis, necrosis or destructive invasion. We suspect that unknown changes at a molecular level are propelling the tumor to metastasize.

Reasons as to why aggressive events occur only in a small number of patients are not yet established and most often these tumors do not reveal the usual requisites for metastatic disease (like high proliferative index, invasive growth pattern, mitoses or necrosis). Several hypotheses have been proposed to explain metastasis, such as prior surgery, permeation of cells into blood vessels and lymphatics.¹ However in our case, no such answers are applicable.

To date, there is no way to predict which (PA) tumor will behave in an aggressive manner, but since the majority follow the normal pathway, we can assume that the vast majority will follow a benign course. However, there are case reports suggesting that pleomorphic adenoma is a low grade potentially malignant tumor.^{5,7} Various authors therefore advocate that patients with intraoperative tumor spillage, incomplete resection or a local recurrence should have long-term follow-up.

The case is presented with detailed IHC profile for its rarity, atypical early aggressive and metastatic behavior.

REFERENCES

1. Cheuk W, Chan JKC. Salivary gland tumors. In: Fletcher CDM editor. Diagnostic Histopathology of tumors. 3rd ed. 2007;1: 239-325.
2. Nouraei SAR, Chir MBB, Ferguson MS, Clarke PM, Sandison A, Sandhu GS, Michaels L, Rhys-Evans P. Metastasizing pleomorphic salivary adenoma. Arch Otolaryngol Head Neck Surg 2006;132(7):788-793.
3. Choi SJ, Cho SI, Do NY, Lee JH, Choi JY, Lim SC. Significance of the expression of tumor markers in adenoid cystic carcinoma and pleomorphic adenoma of the salivary gland. Korean J Otorhinolaryngol Head- Neck Surg 2008;Apr 51(4):336-342.
4. Gnepp DR. Metastasizing Pleomorphic Adenoma. In: Barnes L, Eveson JW, Reichart P, Sidransky D, editors. World Health Organisation Classification of Tumours: Pathology and Genetics of Head and Neck Tumours. Lyon, France: IARC Press, 2005;245.
5. Bradley, Patrick J. Metastasizing pleomorphic salivary adenoma should now be considered a low-grade malignancy with a lethal potential. Current Opinion in Otolaryngology and Head and Neck Surgery 2005 Apr;13(2):123-126.

6. Santaliz-Ruiz IV LE, Morales G, Santini H, Sánchez-Santiago M, Arroyo A. Case Report Metastasizing Pleomorphic Adenoma: A Fascinating Enigma. *Case Reports in Medicine*; Volume 2012 (2012), Article ID 148103;p5.
7. Klijanienko J, El-Naggar AK, Servois V, Rodriguez J, Validire P, Philippe Vielh. Clinically aggressive metastasizing pleomorphic adenoma: report of two cases. *Head and Neck* 1997;Oct 19(7):629-633.

ABOUT THE AUTHORS

RF Chinoy

Consultant Histopathologist, Department of Pathology, Prince Aly Khan Hospital, Mumbai, Maharashtra, India

Correspondence Address: Nesbit Road, Aga Hall, Opp. St. Mary Boys School, Mumbai-400 010, Maharashtra, India, Phone: 09821242778
e-mail: roshchinoy@gmail.com, medico_rajesh@hotmail.com

D Dalmia

Head, Department of ENT, Dr BAM Central Railway Hospital Byculla, Mumbai, Maharashtra, India

RS Mundhe

Consultant Pathologist, Department of Pathology, Prince Aly Khan Hospital, Mumbai, Maharashtra, India

MA DeSouza

Assistant Pathologist, Department of Pathology, Prince Aly Khan Hospital, Mumbai, Maharashtra, India

V Rane

Assistant Pathologist, Department of Pathology, Prince Aly Khan Hospital, Mumbai, Maharashtra, India