

Sarcoid-like Foreign Body Granuloma of Tongue

Jagannath Bisanna, Smitha Soubhagya Gangaraj, Nirmala Santhosh

ABSTRACT

We report a case of delayed granulomatous reaction of the tongue due to religious practice of piercing with a metal rod. There are very few cases reported in literature with complications of ritual oral and body piercing presenting as sarcoid-like foreign body granuloma.

Keywords: Tongue piercing, Foreign body, Sarcoid-like, Granulomatous nodule.

Source of support: Nil

Conflict of interest: None declared

INTRODUCTION

Oral and body piercing are practiced by some devotees as a part of religious and cultural ceremonies. Cheek, tongue, chest or back are usually pierced with metal spears or hooks. The complications which may occur are bleeding, infection and granulomatous reaction. Complications of such piercing are very rare with very few cases reported in Malaysia and India.

CASE REPORT

A 38-year-old male patient presented with a progressive, nontender swelling in the tongue since 1 month. On examination, a firm swelling measuring about 2.5×2.5 cm was noted on the right dorsal aspect of the tongue with no restriction to mobility of the tongue. The mucosa over the swelling was intact (Fig. 1).

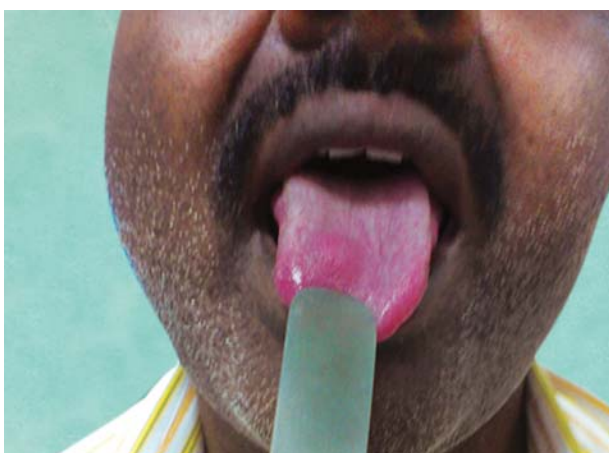

Fig. 1: Firm swelling on the right dorsal aspect of tongue

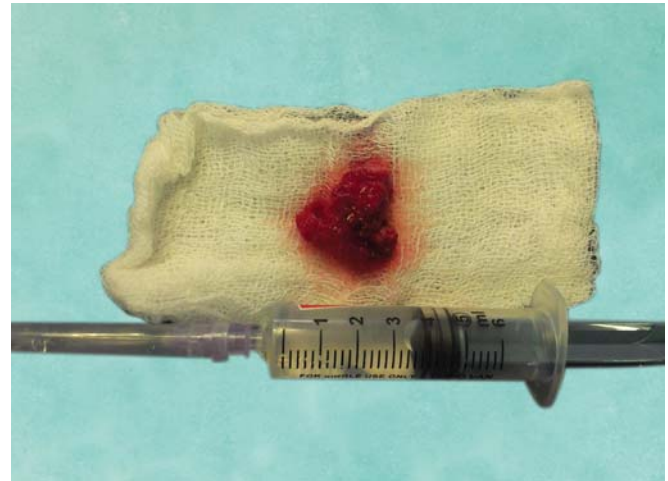


Fig. 2: Excised mass of the tongue

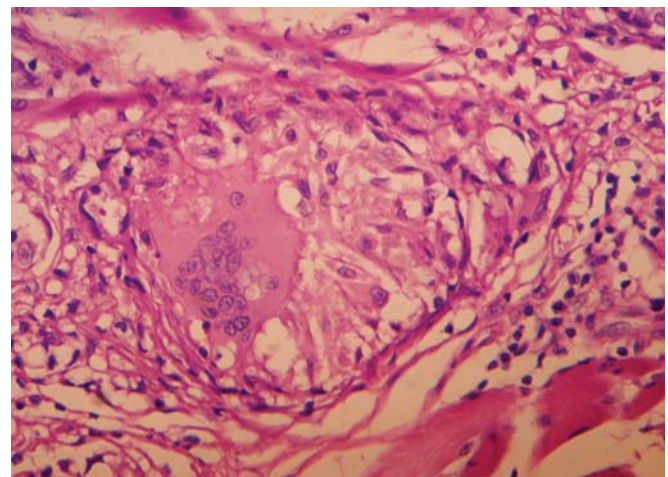


Fig. 3: Microscopic picture showing epithelioid granulomas surrounded by fibrocollagenous tissue, Langhans and foreign body type giant cells (H&E: 40x)

FNAC of the swelling was inconclusive. The swelling was excised (Fig. 2) and sent for histopathological examination. Sections showed multiple epithelioid granuloma surrounded by fibrocollagenous tissue. There were Langhans and foreign body type of giant cells along with scattered chronic inflammatory cells. The granulomas were noncaseating type and were seen insinuating between the muscle fibers. Some giant cells showed asteroid bodies phagocytic vacuoles (Fig. 3). A diagnosis of sarcoidosis or foreign body granuloma was made. Questioning the patient revealed that he had undergone a ritual of piercing his tongue with a metal rod and then covering the raw area with holy ash, a year back. All investigations were also done to rule out sarcoidosis. Patient is on regular follow-up without any recurrence.

DISCUSSION

Body piercing is becoming popular among younger generation. The most common piercing sites in the orofacial region are lips, labiomental groove, cheeks, nose and eyebrows. Tongue piercing is becoming increasingly popular.¹ Complications related to it are bleeding, infection, allergic reactions, scarring and granulomatous reaction.² The most obvious complications are those of pain and swelling. Edema of the tongue is a feature of all tongue piercing because of the vascularity of the area.³ Clinical manifestations may occur rapidly or delayed for months or years.

As a religious practice, body piercing has been followed for many years. Metal rods and hooks are pierced on cheeks, tongue, chest and back. Complications of such puncturing are extremely rare. Very few cases are reported in Malaysia and India.^{4,5} Mucous membranes seem to be more susceptible to the mechanical-related injuries than the skin because the skin is thicker and has more protective layers.⁵ There are very few cases reported in literature which presented as sarcoid-like foreign body reaction.⁶ The granulomatous reaction is attributed to the holy ash used or due to small metal shards getting embedded into the skin and oral mucosa on penetration or removal of the spear.⁴ Treatments include excision or intralesional corticosteroid injections. Sarcoidosis should be ruled out and regularly followed up.

REFERENCES

1. Ziebolz D, et al. Long-term effects of tongue piercing—a case control study. *Clin Oral Investig* 2012;16(1):231-37.
2. Koenig LM, Carnes M. Body piercing medical concern with cutting-edge fashion. *J Gen Intern Med* 1999;14:379-85.
3. Farah CS, Harmon DM. Tongue piercing: Case report and review of current practice. *Australian Dent J* 1998;43(6):387-89.
4. Su MW, Jyh JT, Suganthi T, Roshidah B. Delayed granulomatous reaction after oral piercing during Thaipusam. *Ann Dermatol* 2012;24(3):355-57.
5. Antoszewski B, Szychta P, Fijalkowska M. Are we aware of all complications following body piercing procedures? *Int J Dermatol* 2009;48:422-25.
6. Ng KH, Siar CH, Ganesapillai T. Sarcoid-like foreign body reaction in body piercing: A report of two cases. *Oral Surg Oral Med Oral Pathol Oral Radiol Endod* 1997;84(1):28-31.

ABOUT THE AUTHORS

Jagannath Bisanna

Associate Professor, Department of ENT, Kempegowda Institute of Medical Sciences, Bengaluru, Karnataka, India

Smitha Soubhagya Gangaraj (Corresponding Author)

Assistant Professor, Department of ENT, Kempegowda Institute of Medical Sciences, Bengaluru, Karnataka, India, e-mail: smitha_praveen@hotmail.com

Nirmala Santhosh

Senior Resident, Department of ENT, Kempegowda Institute of Medical Sciences, Bengaluru, Karnataka, India